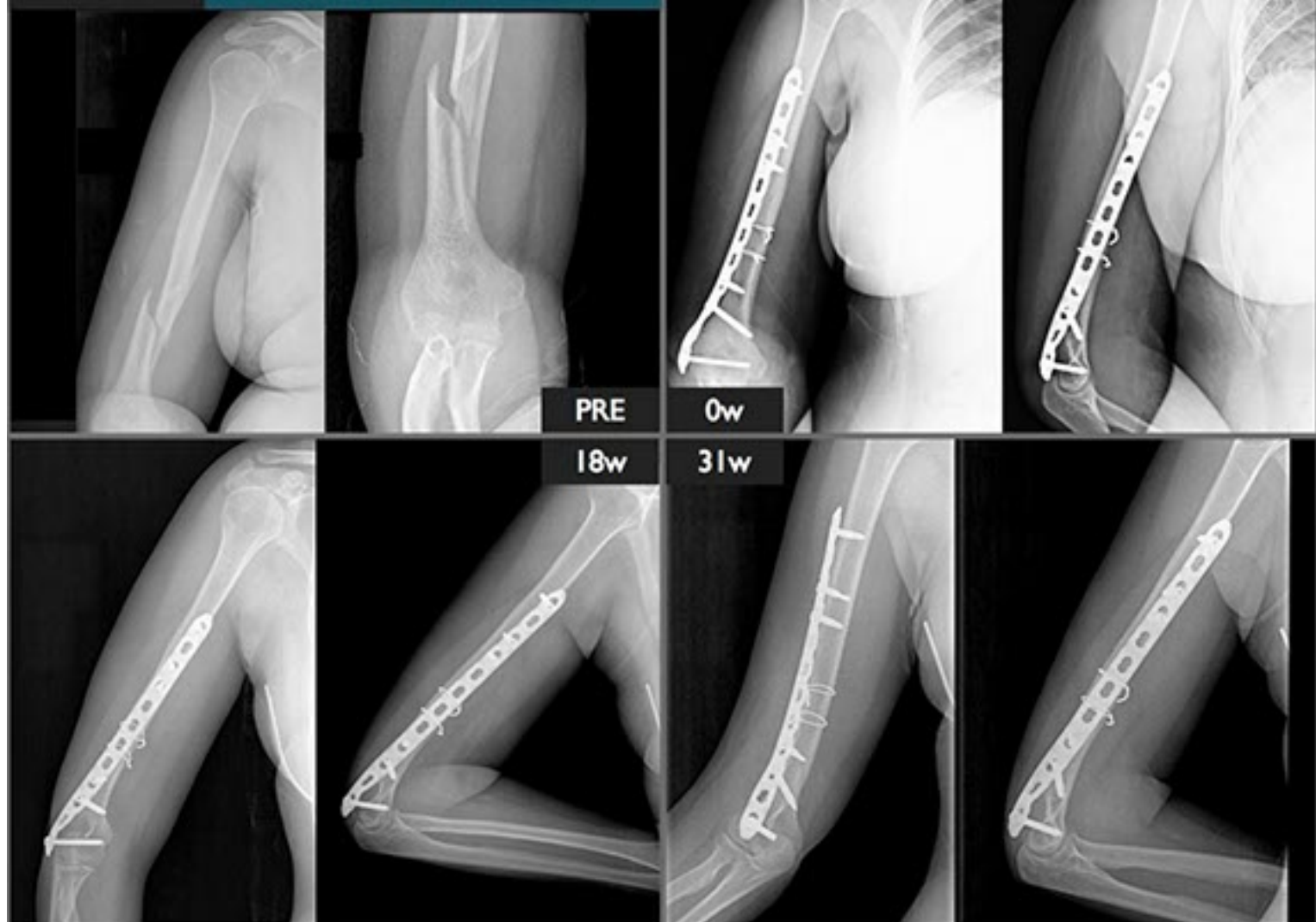
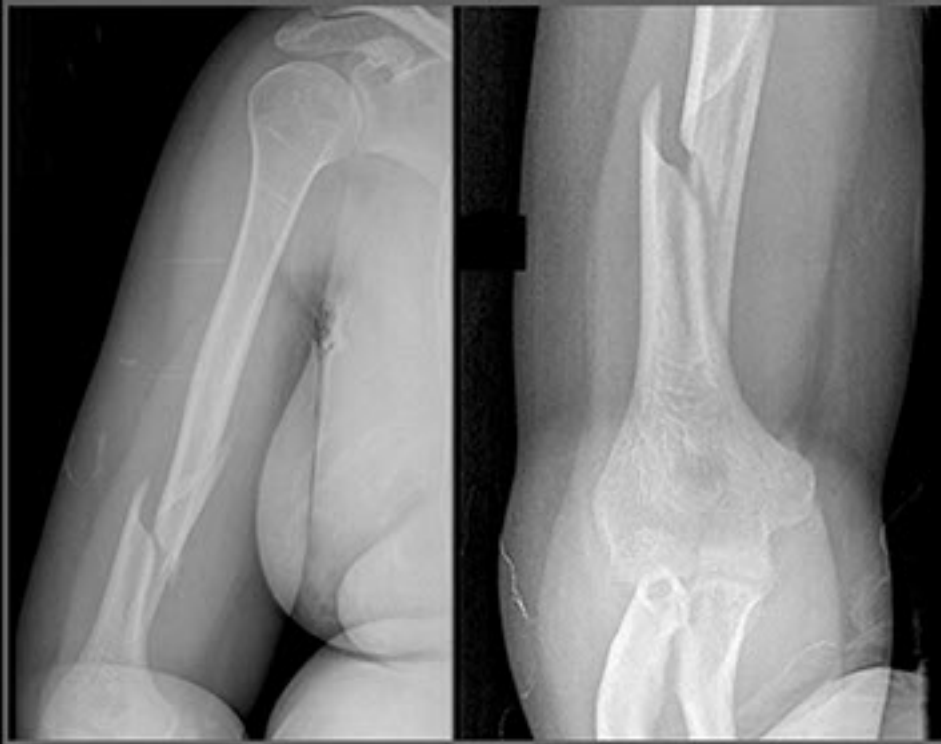


Apr 2015

COMMENTED by Simon Lambert



PRE



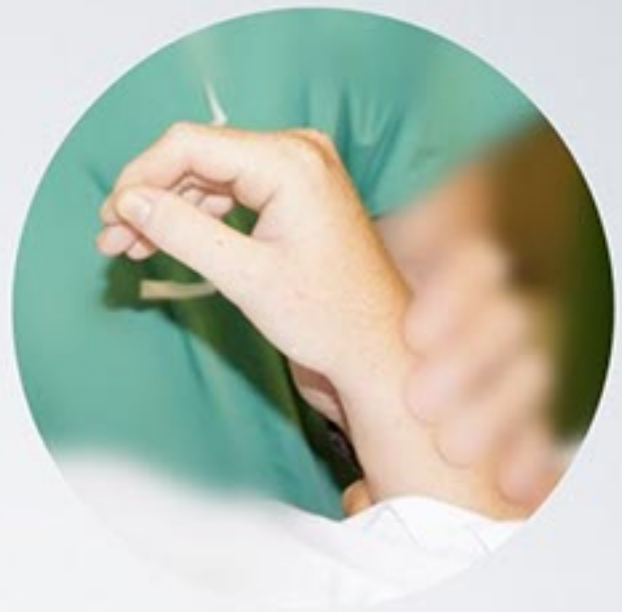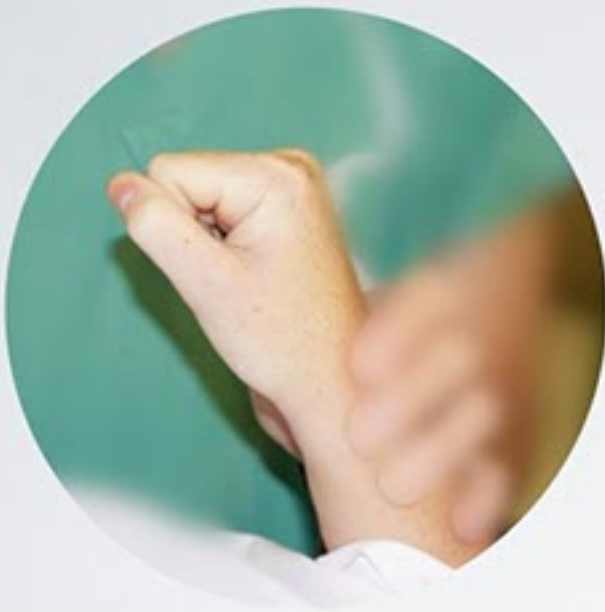This is a distal segmental spiral fracture with the medial segment and in this case the medial segment appears to be less displaced than the entire distal segment. The displacement - in what appears to be a closed injury - is governed by the attachment of the triceps to the posteromedial aspect of the distal humerus so that there is a varus and internal rotation with abduction type of displacement to the distal humerus. And the apex of the distal humerus segment laterally is very close to the perforation of the lateral intermuscular septum through which the radial nerve enters the anterior compartment of the distal arm.

PRE

So, this fracture - even though it is usually a fairly low energy injury - has to be concerned with the function of the radial nerve.

And we understand from literature that alignment of fracture and stability of fracture is important in terms of nerve recovery.

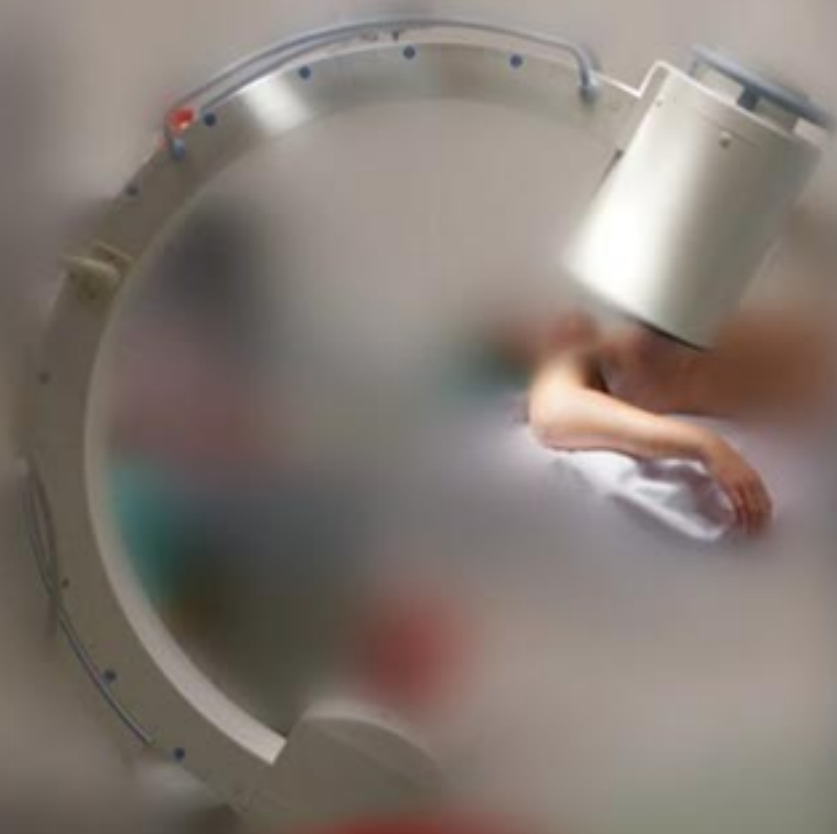So this is the sort of injury where if there is an associated radial nerve injury there is an absolute indication to achieve fracture stability through fixation rather than treat this non-operatively.

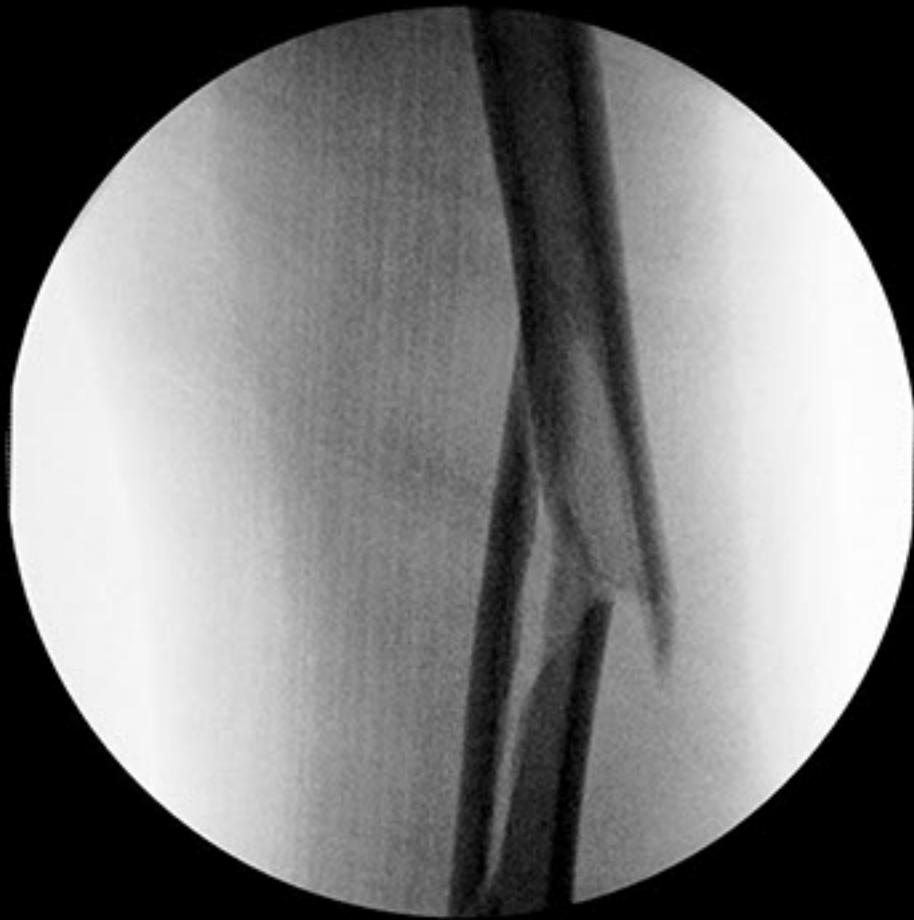

There is at least a partial radial nerve injury.
In the English speaking literature to-date there is a reasonable consensus that non operative management of some humeral shaft fractures is acceptable because - and this is a misconception in my view - the radial nerve always gets better. We are not sure of that and we do not have good evidence for that.

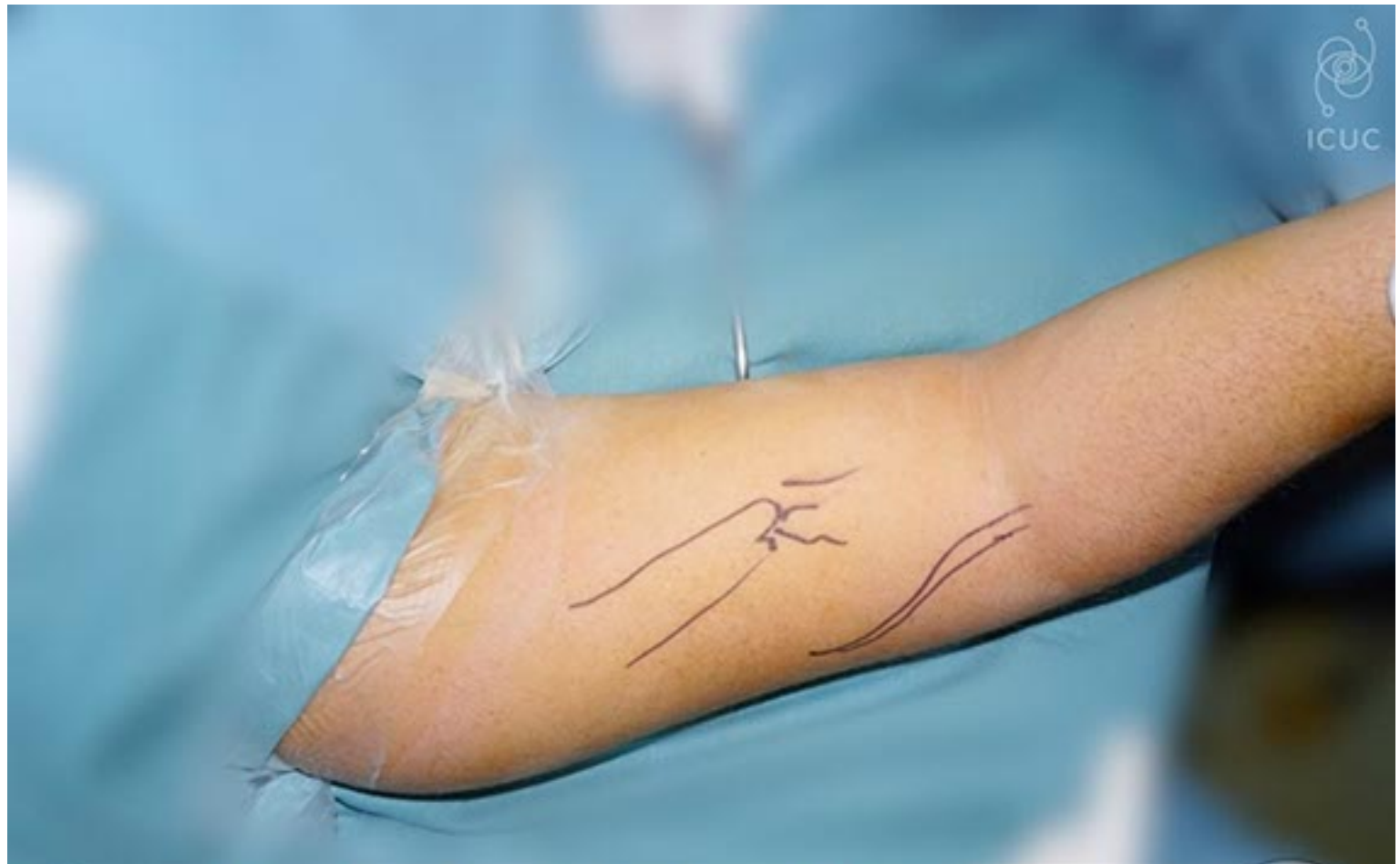I was very concerned with an amateur analysis of that topic in the British Journal of Orthopaedics that basically took a rather holistic view of these fractures and said they could be treated non operatively which I have to say I have some disagreement with.

Here we have a condition where there is a progressive radial nerve lesion. In that case there is an absolute indication to operate. What you then do with the fracture is entirely up to you but the radial nerve really has to be exposed so we can predict it's outcome. If we are going to expose the radial nerve, well, then we are obliged really to stabilize the fracture. So the two go hand in hand.

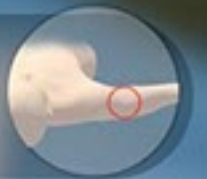



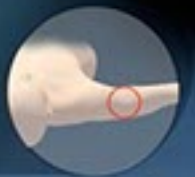Under fluoroscopy we can see that the fracture is realigned in longitudinal traction. So we know that we are going to be able to manipulate this fracture relatively safely.

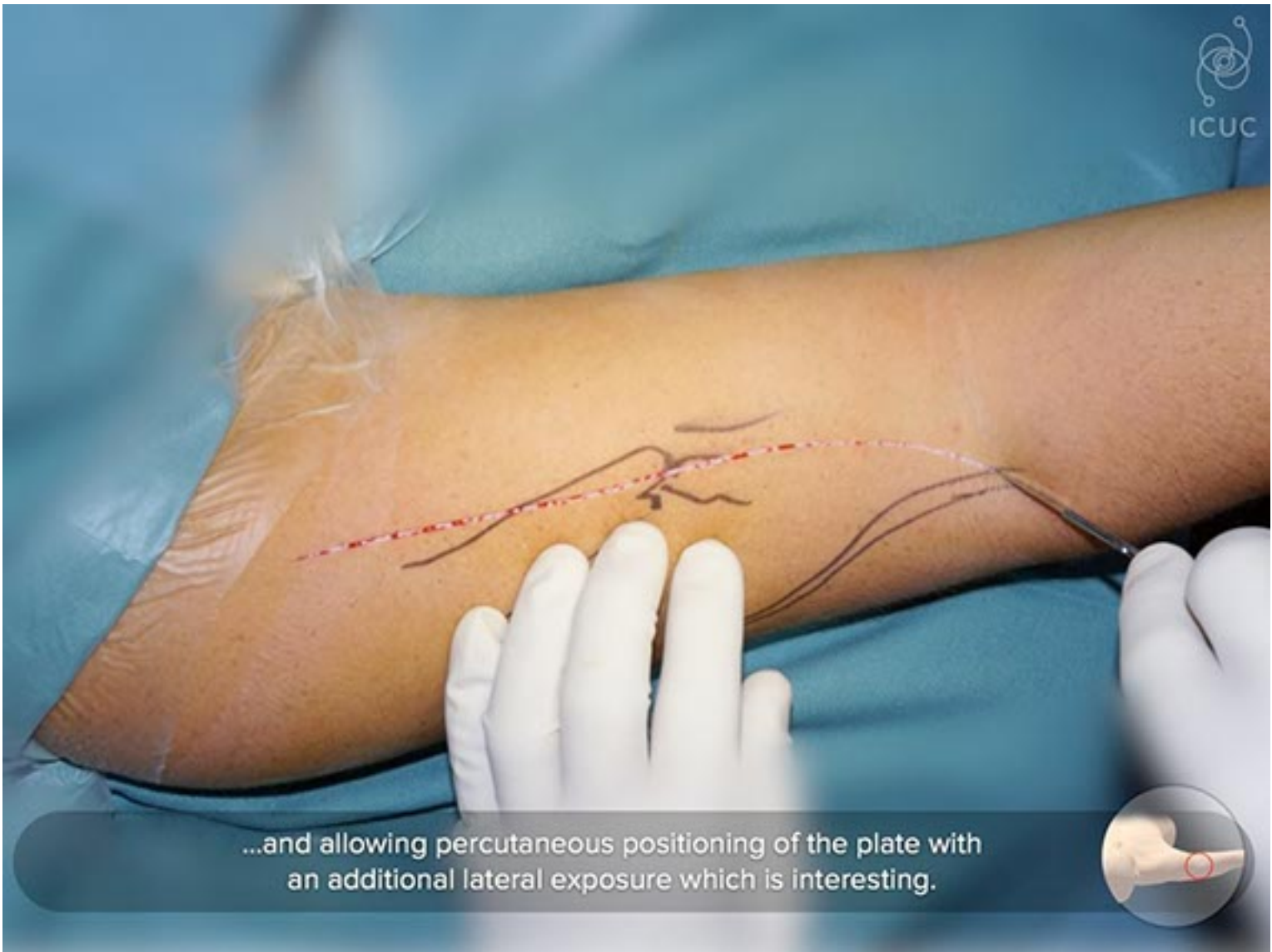

A view of where the fracture is in relation to the radial nerve trunk by topographical anatomical landmarks. This allows us then to understand where to site the incision.

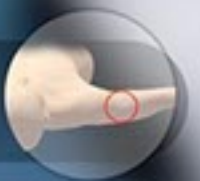

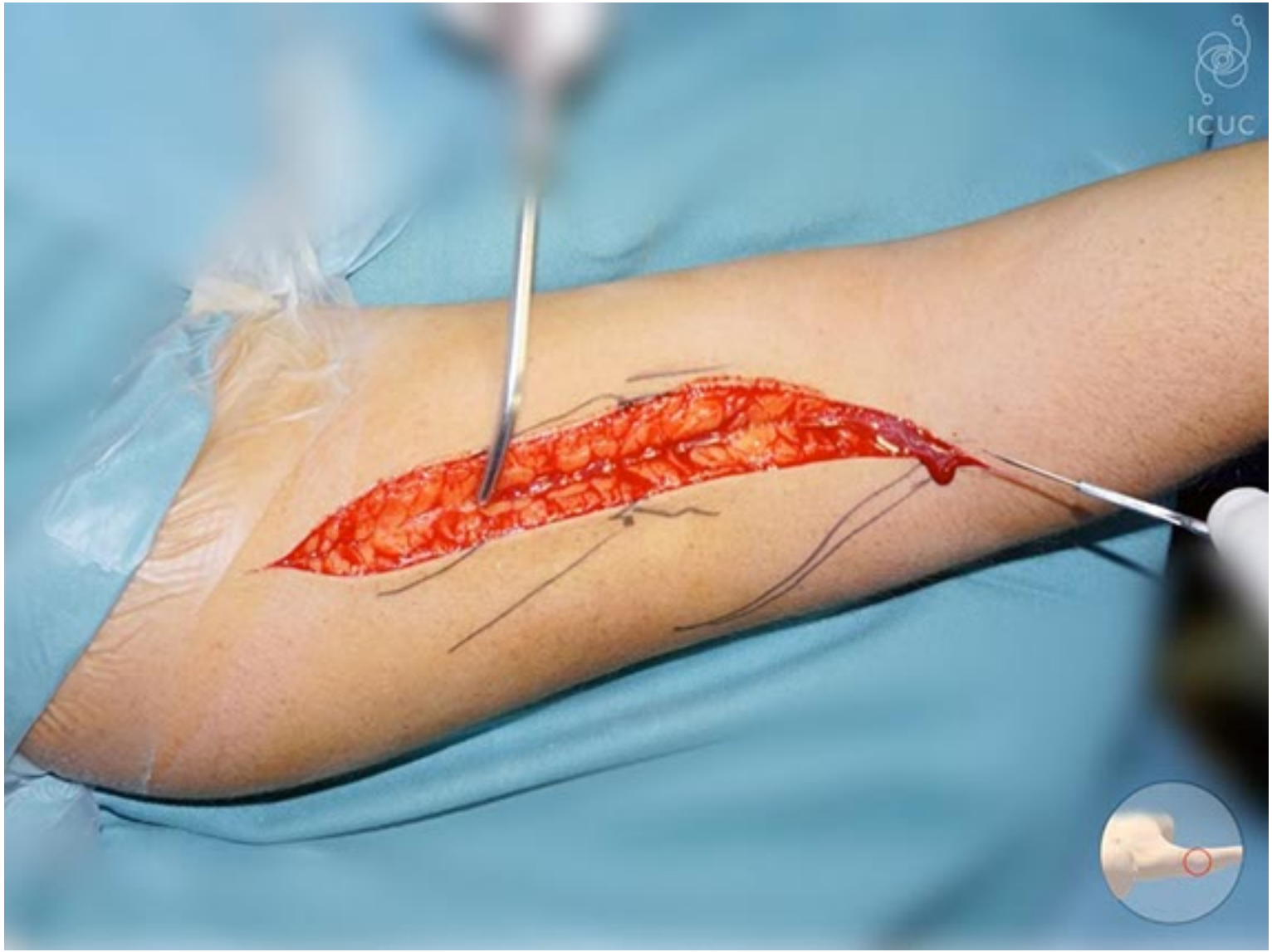This is an interesting incision which is an almost direct anterior approach, running down towards the elbow and then curving laterally so one can get access to the radial nerve trunk as passes between brachialis and brachioradialis...

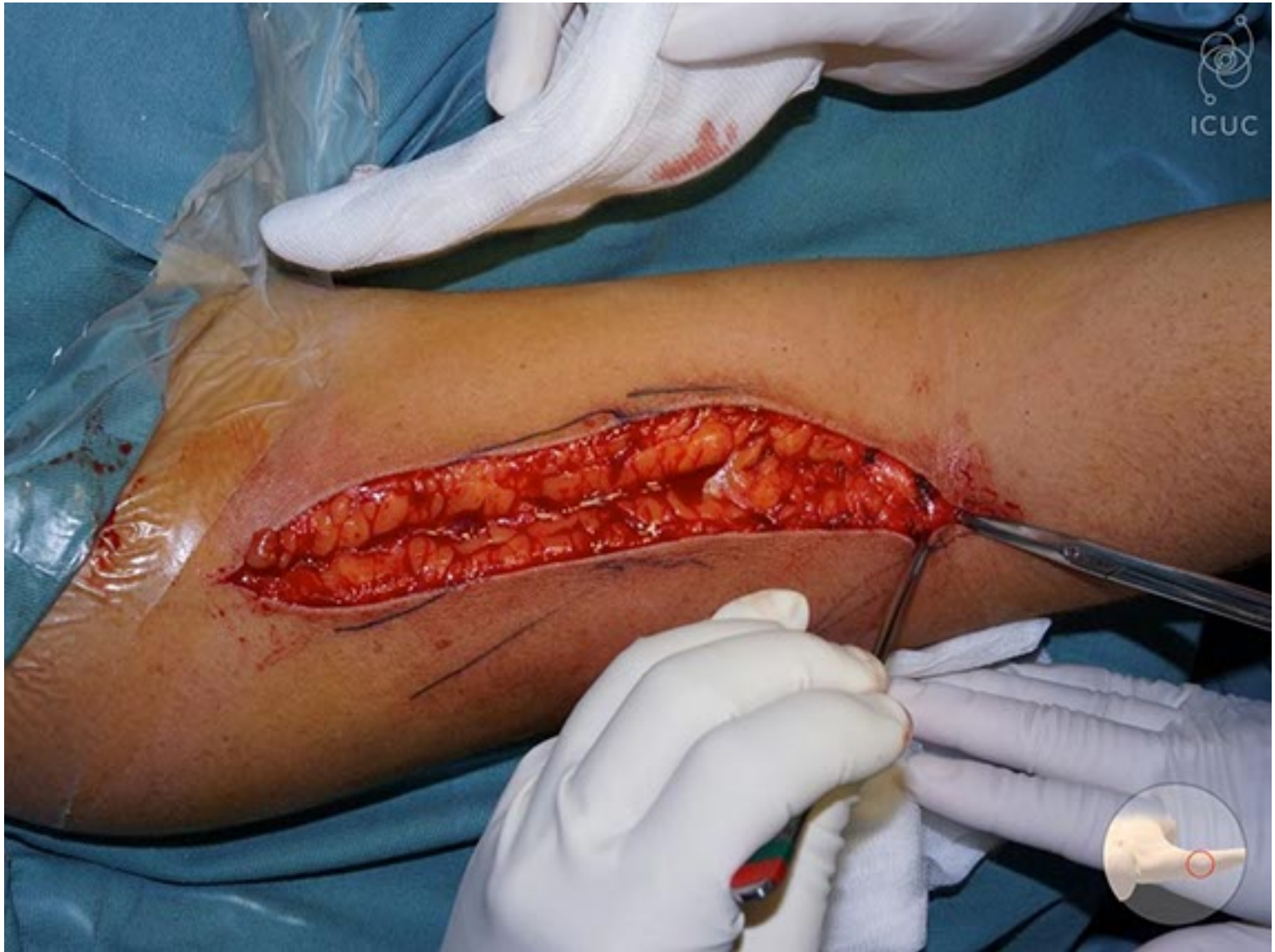


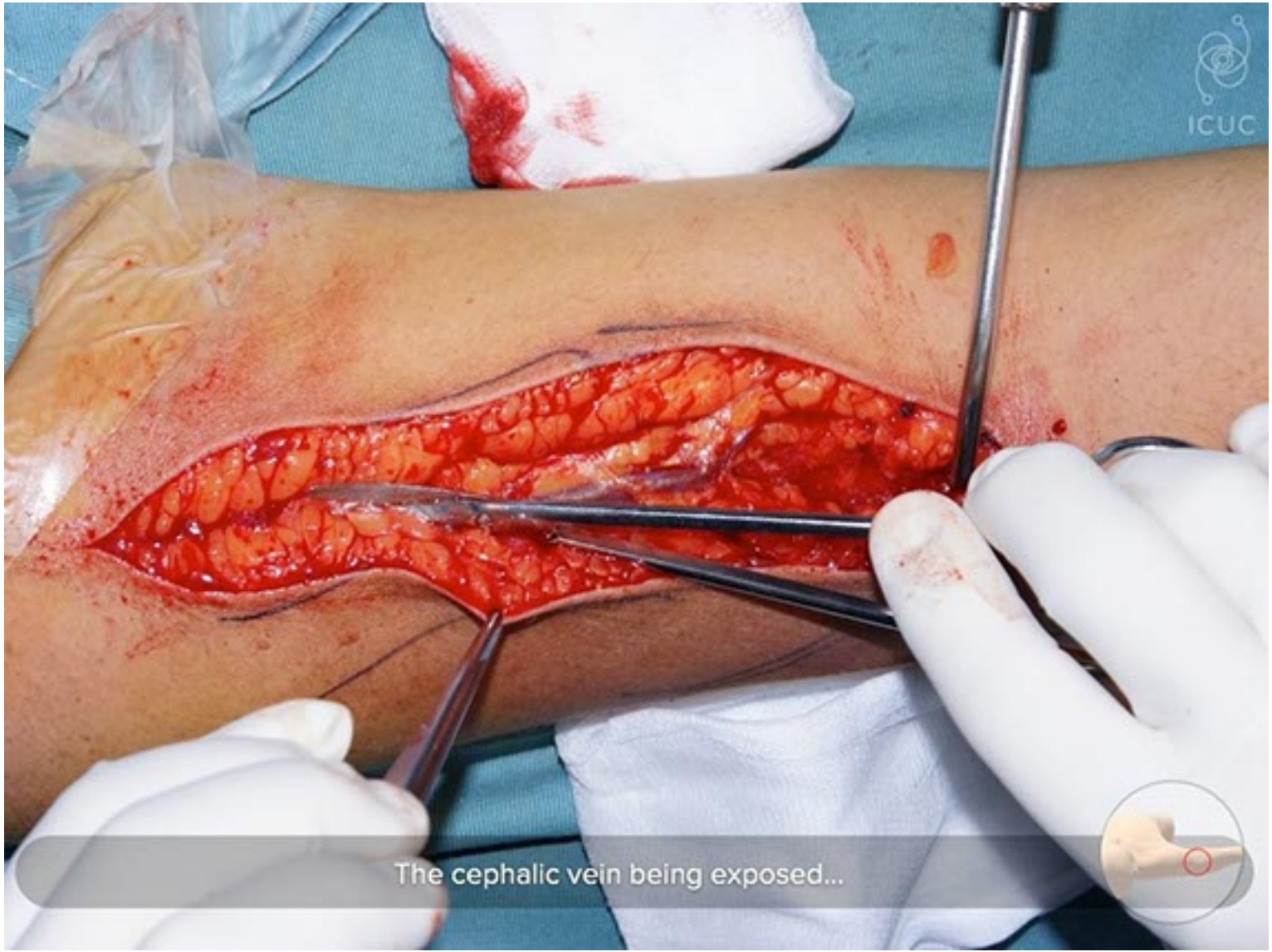
...and allowing percutaneous positioning of the plate with an additional lateral exposure which is interesting.

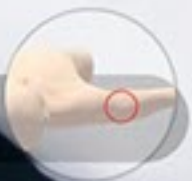


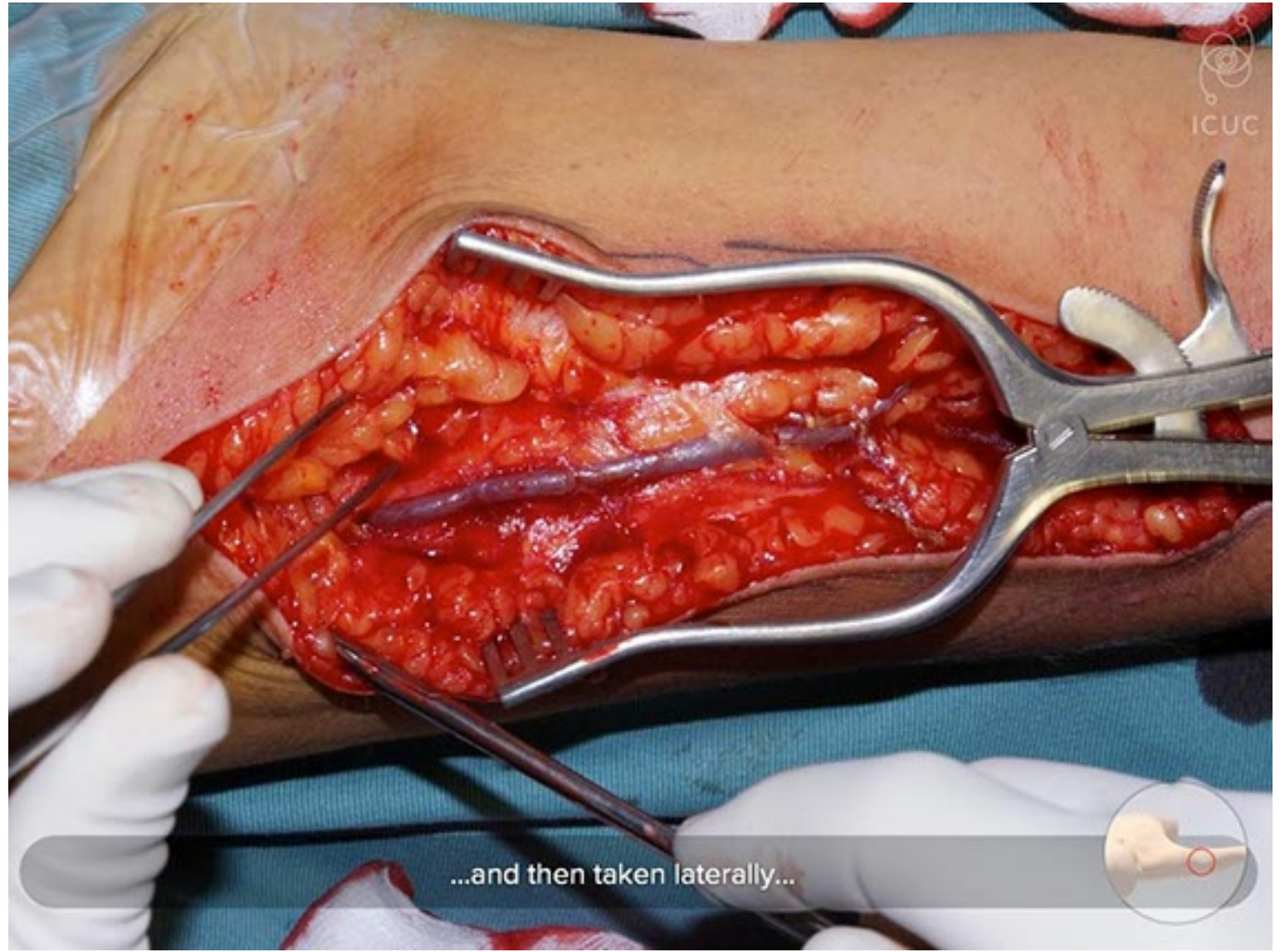




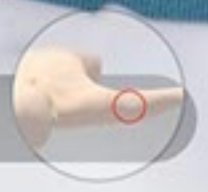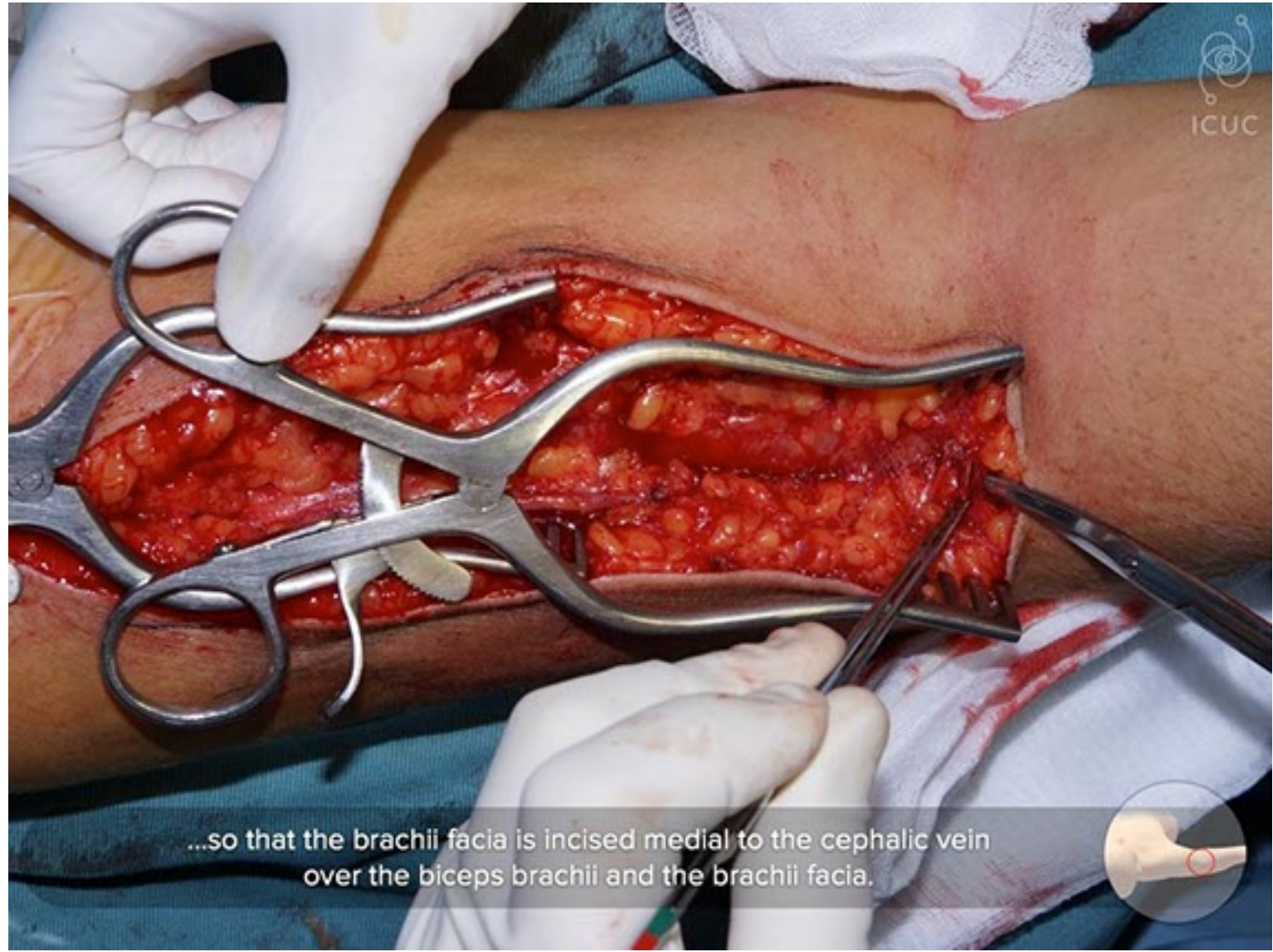The cephalic vein being exposed...



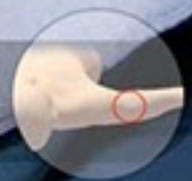

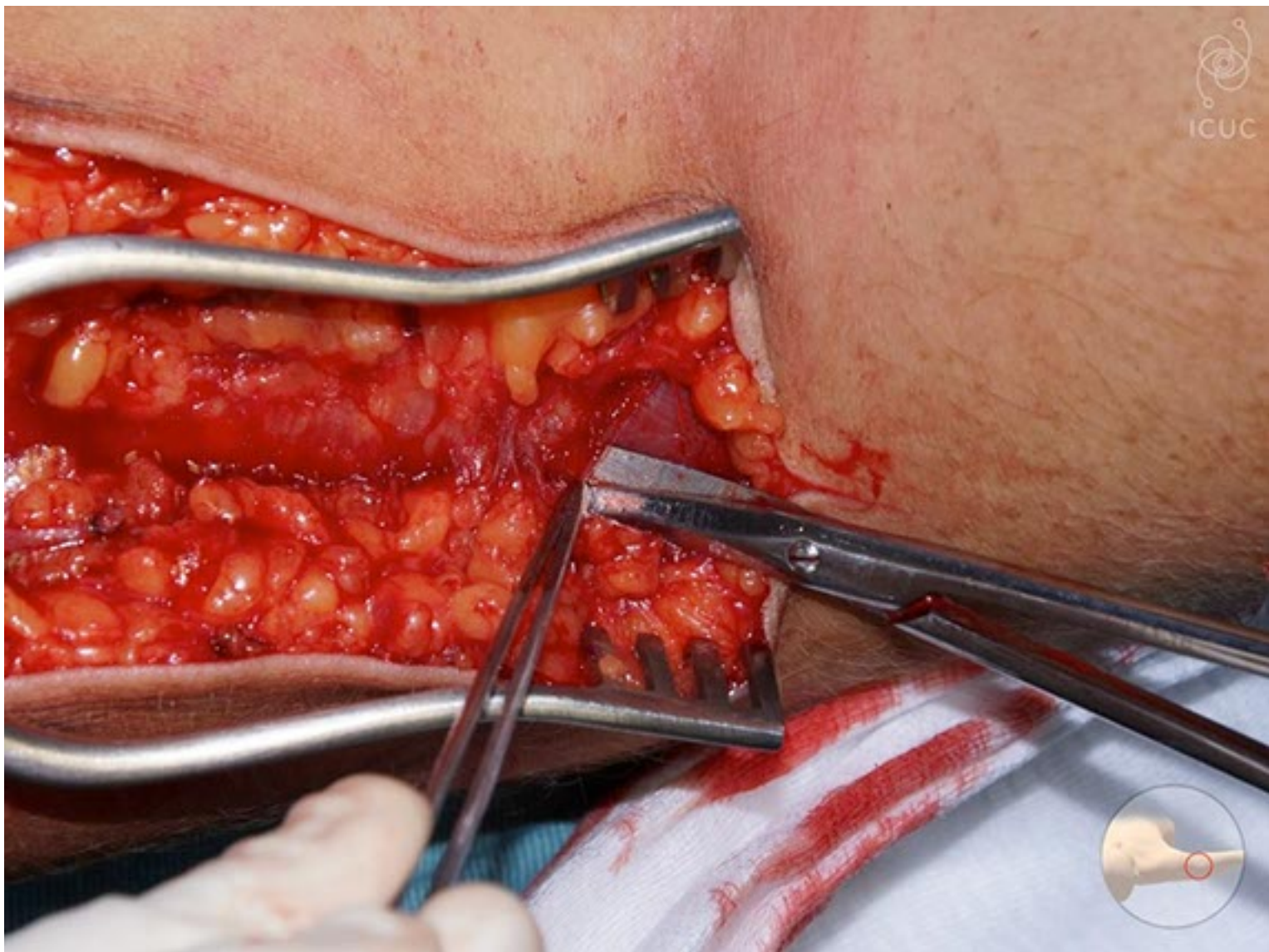
...and then taken laterally...

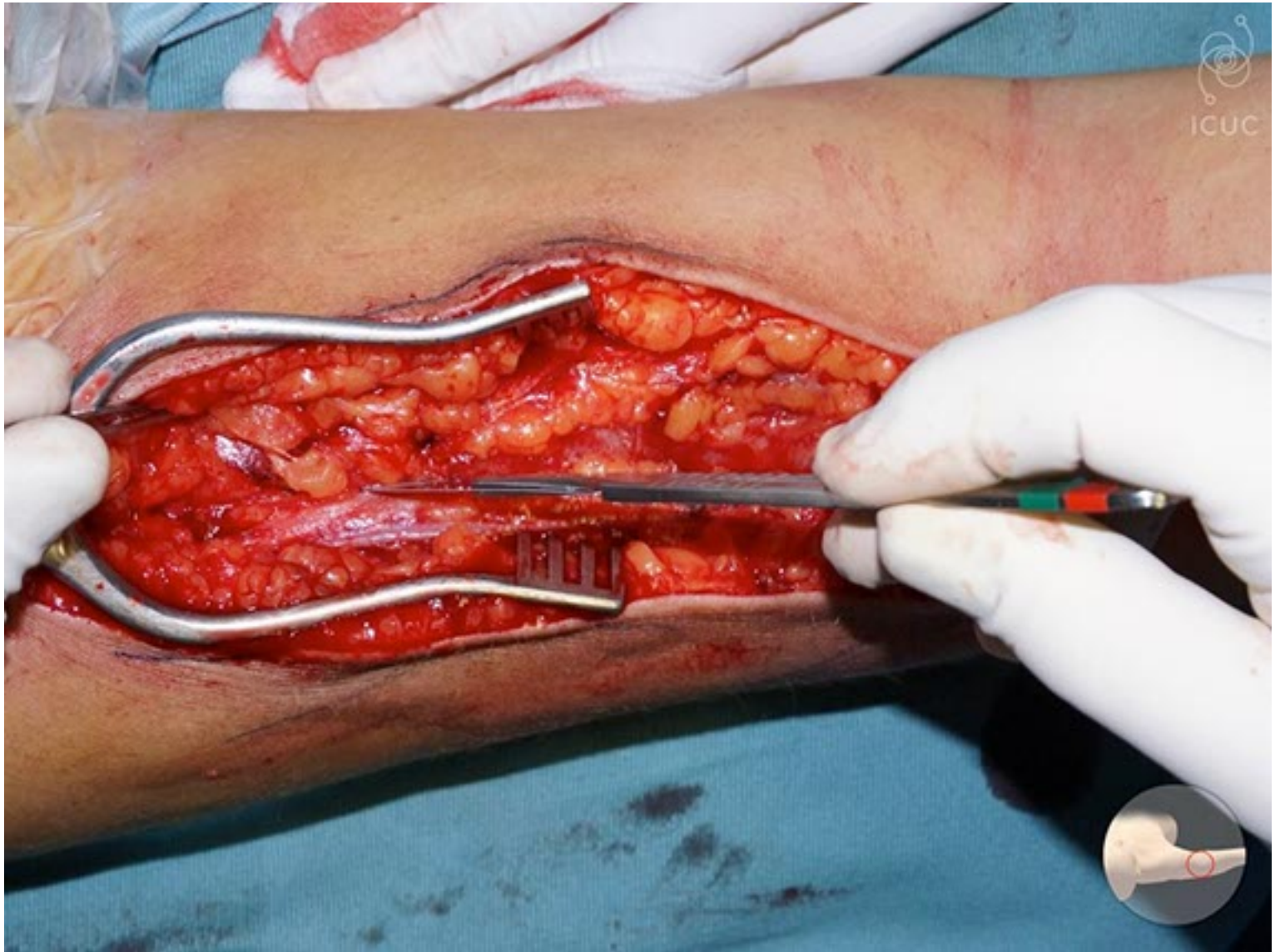


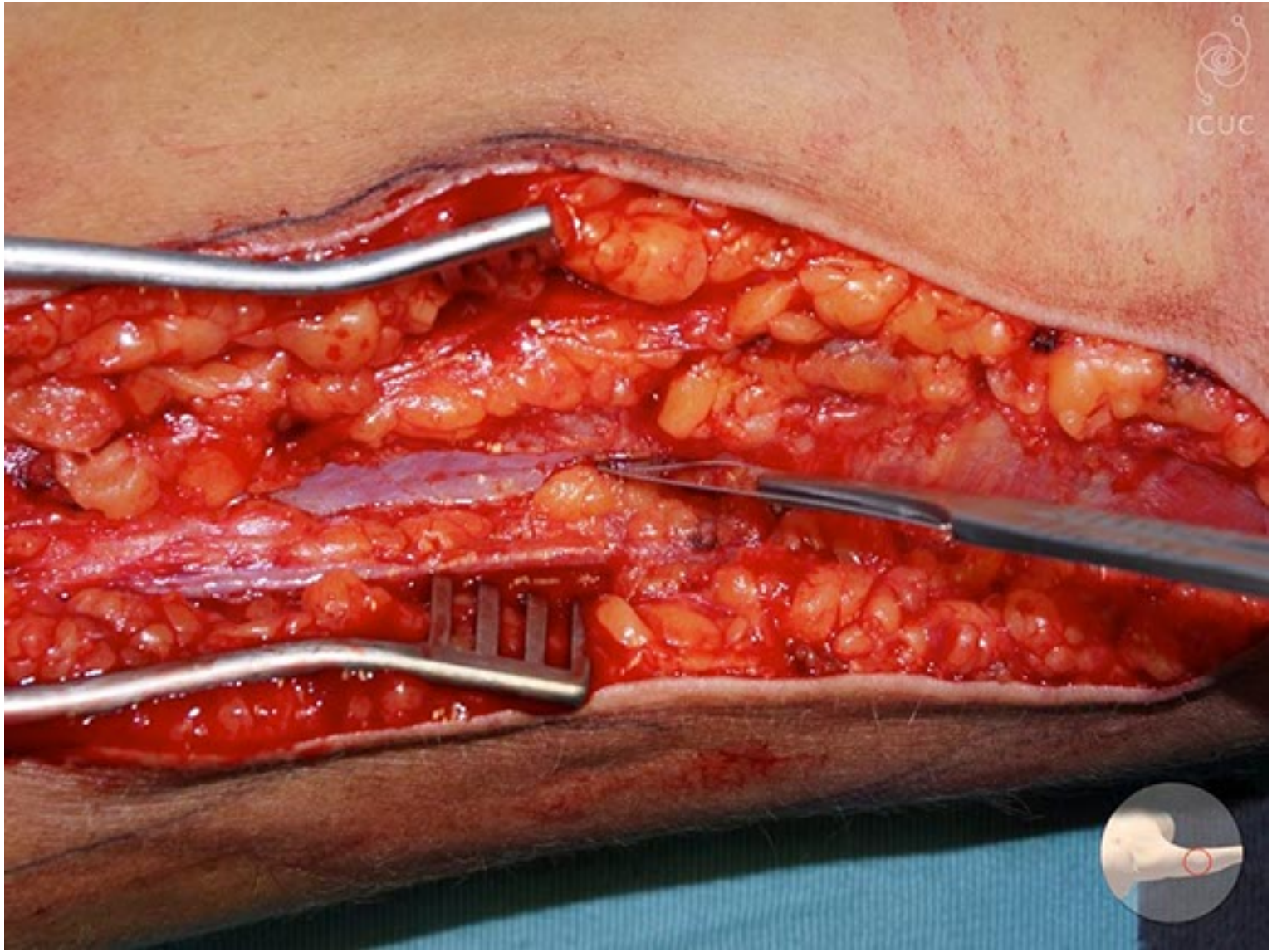


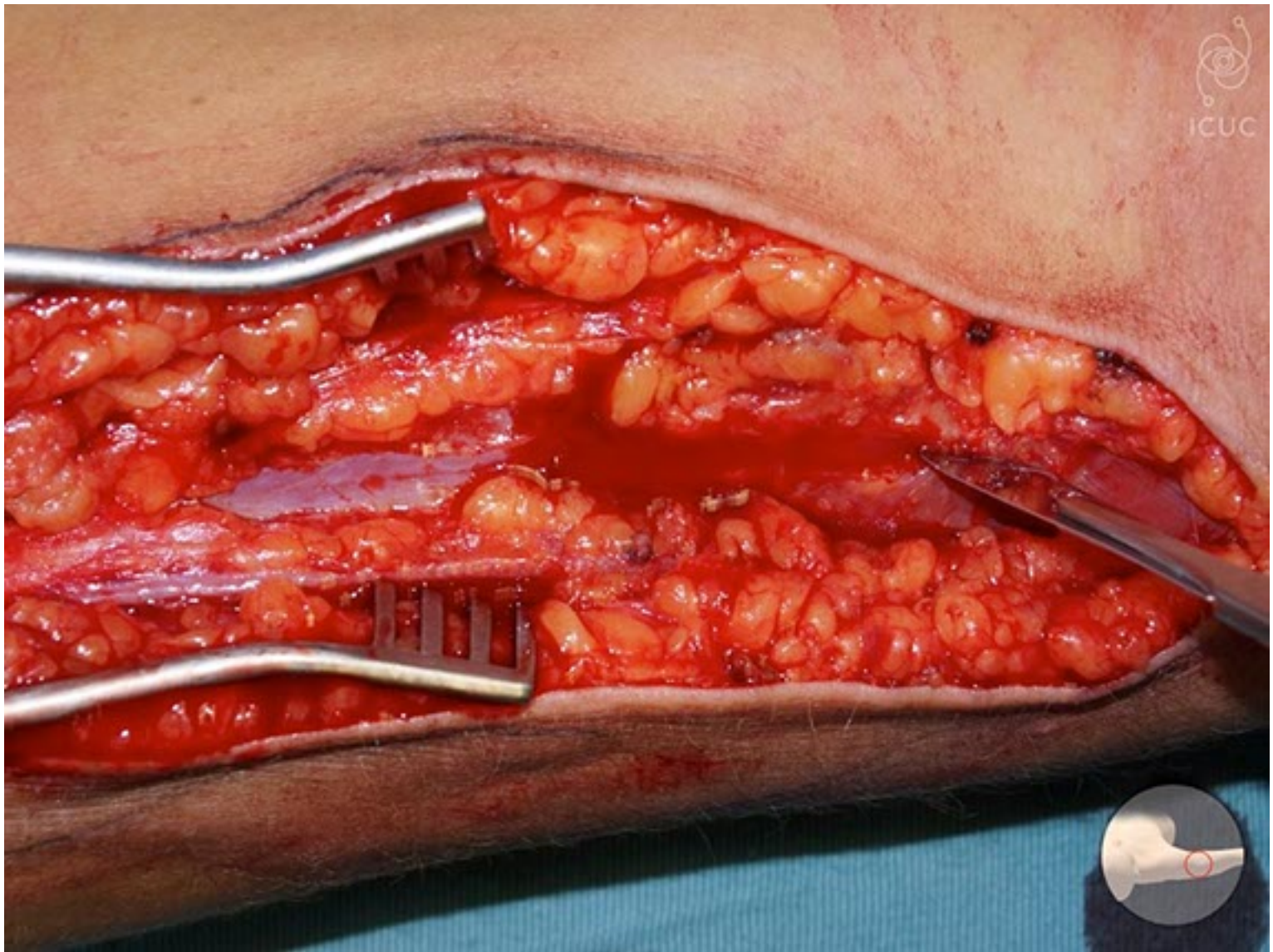...so that the brachii fascia is incised medial to the cephalic vein over the biceps brachii and the brachii fascia.

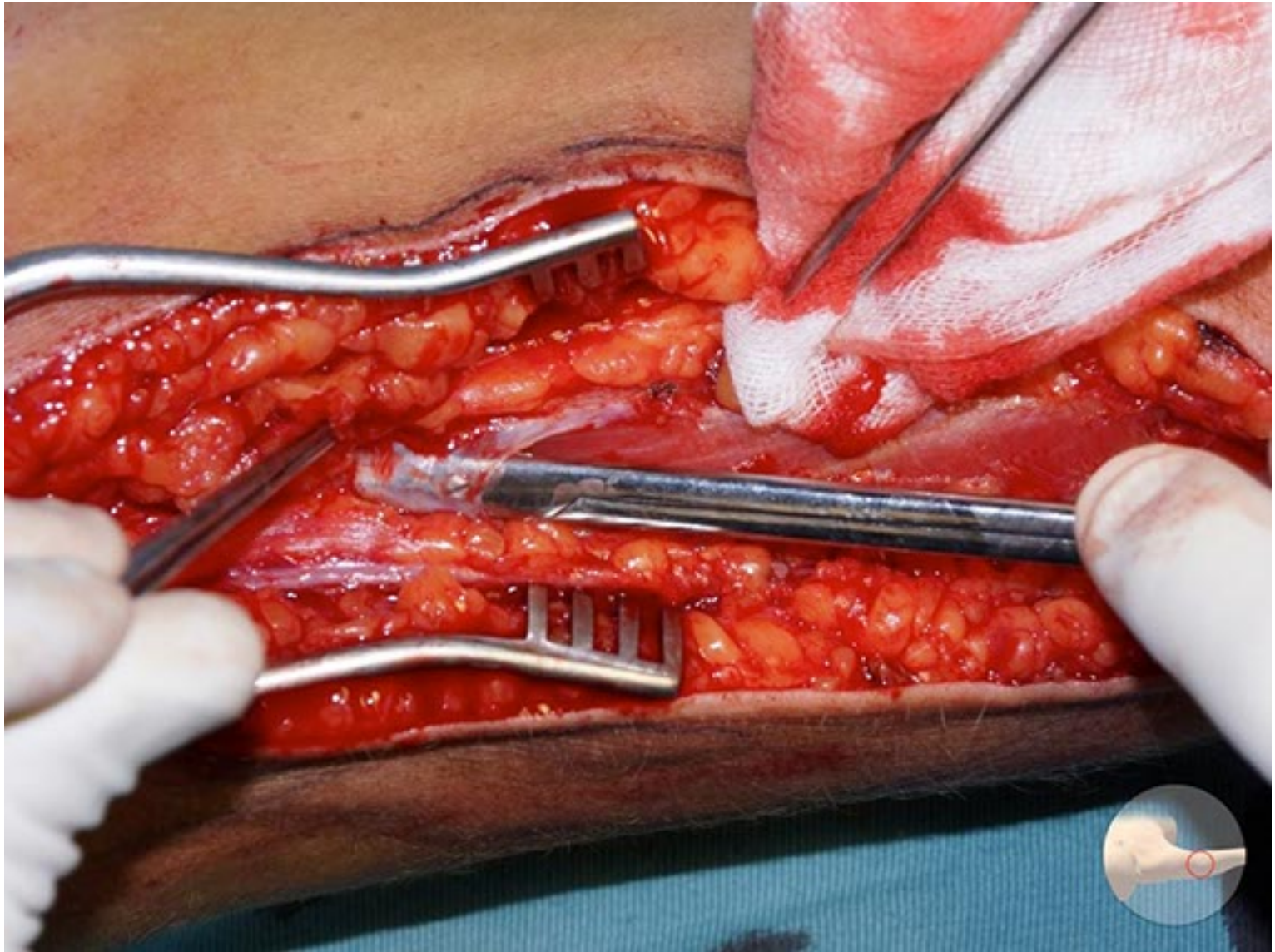


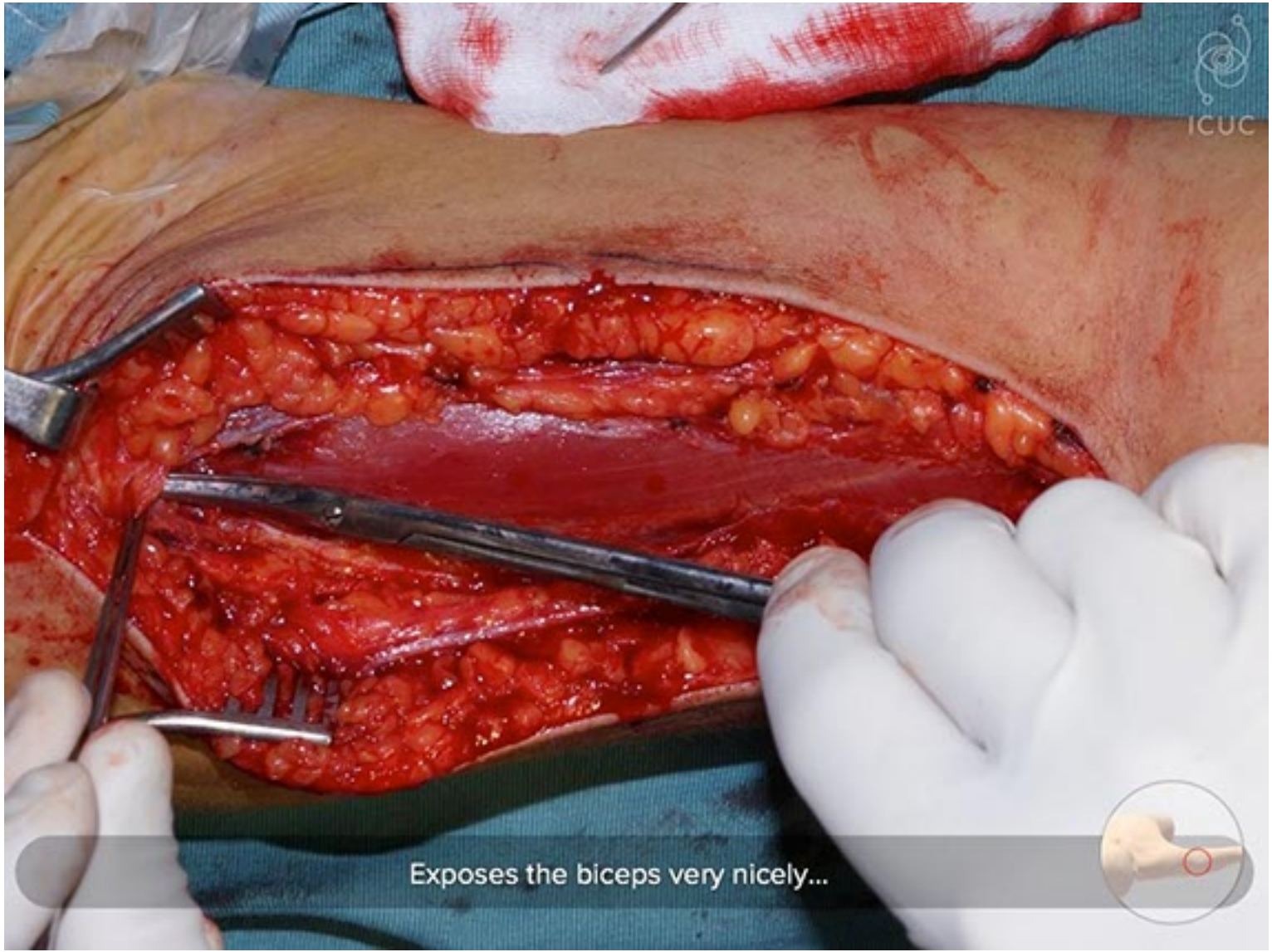




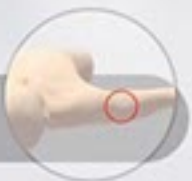
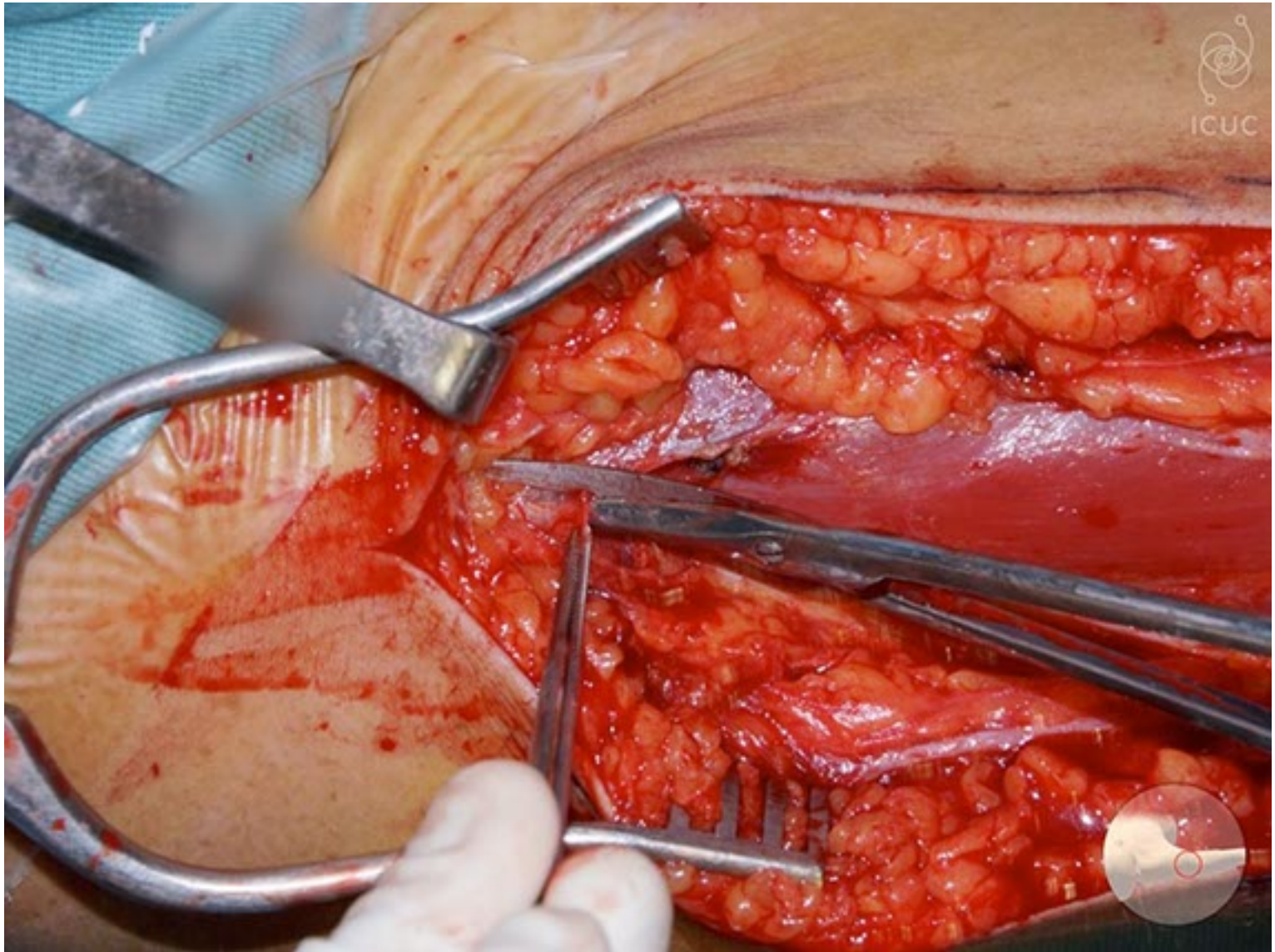




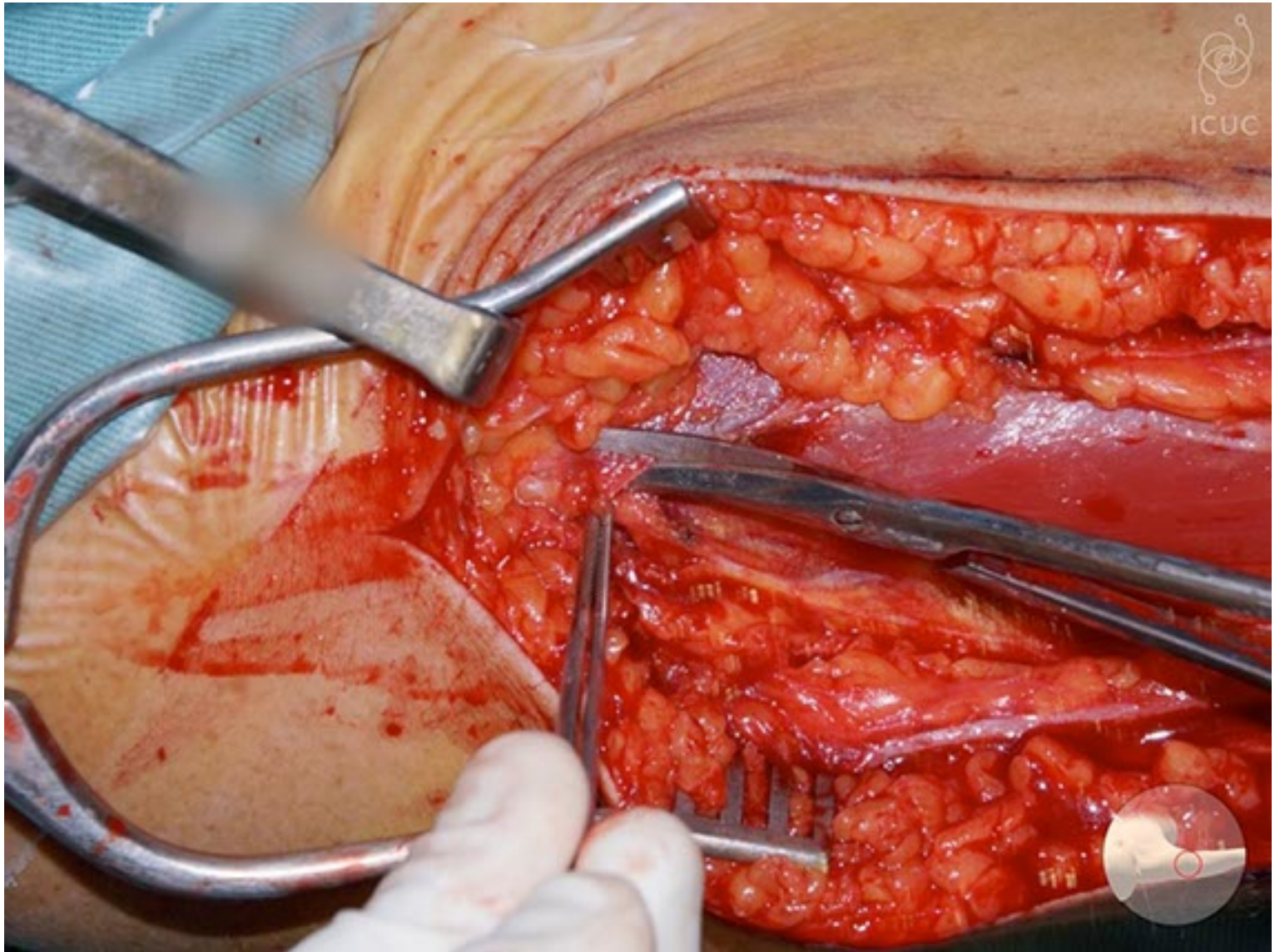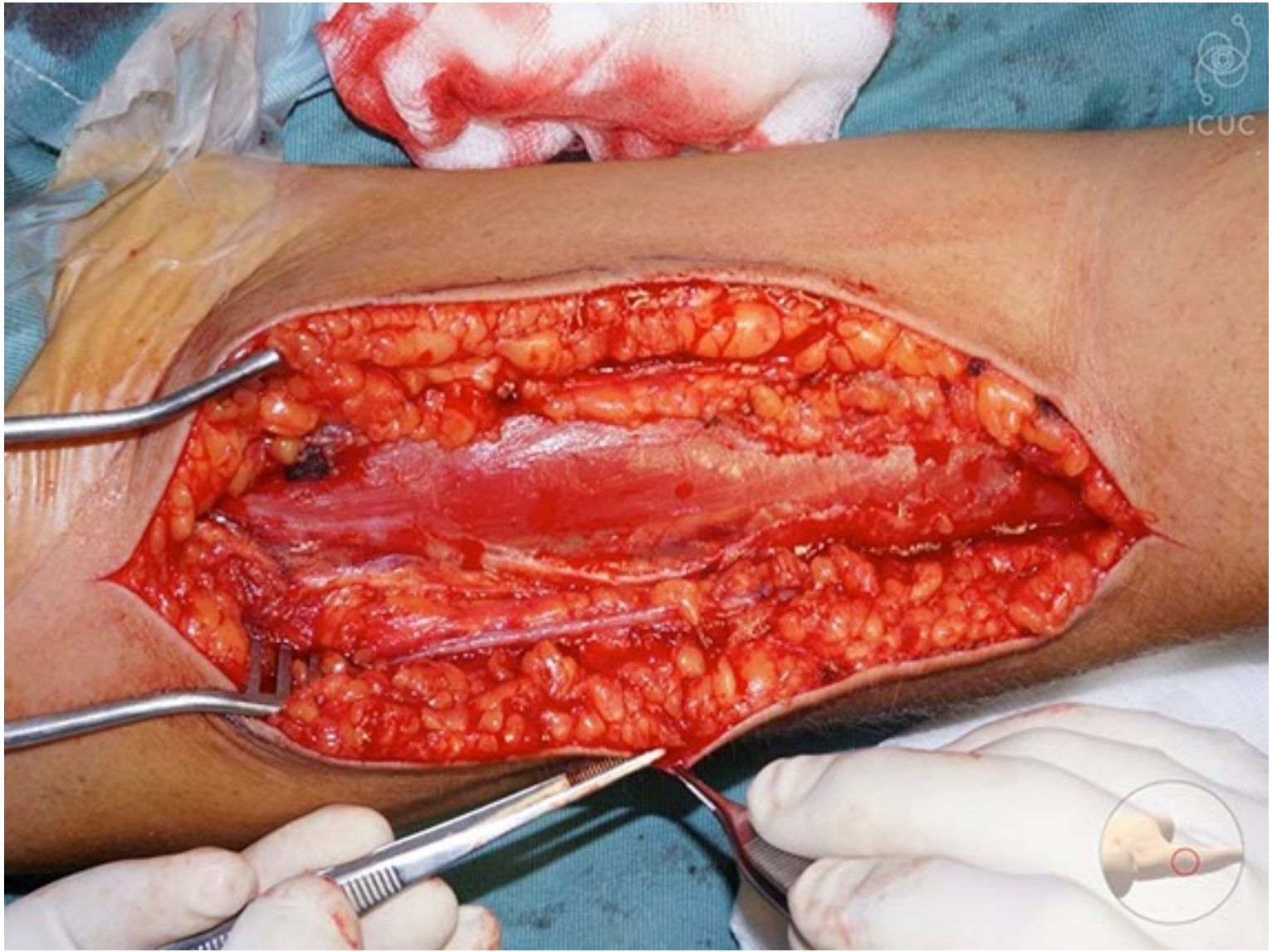


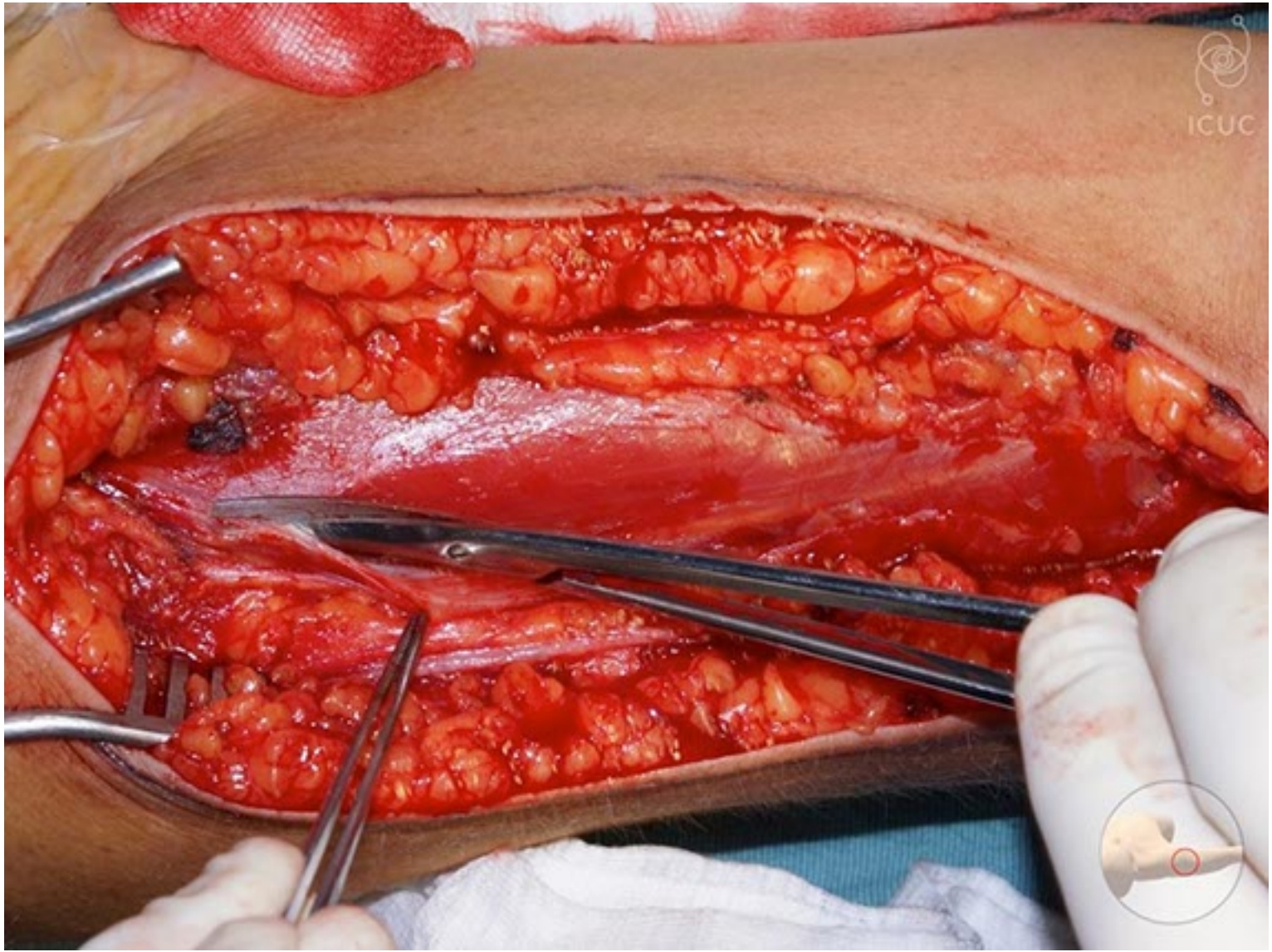
Exposes the biceps very nicely...

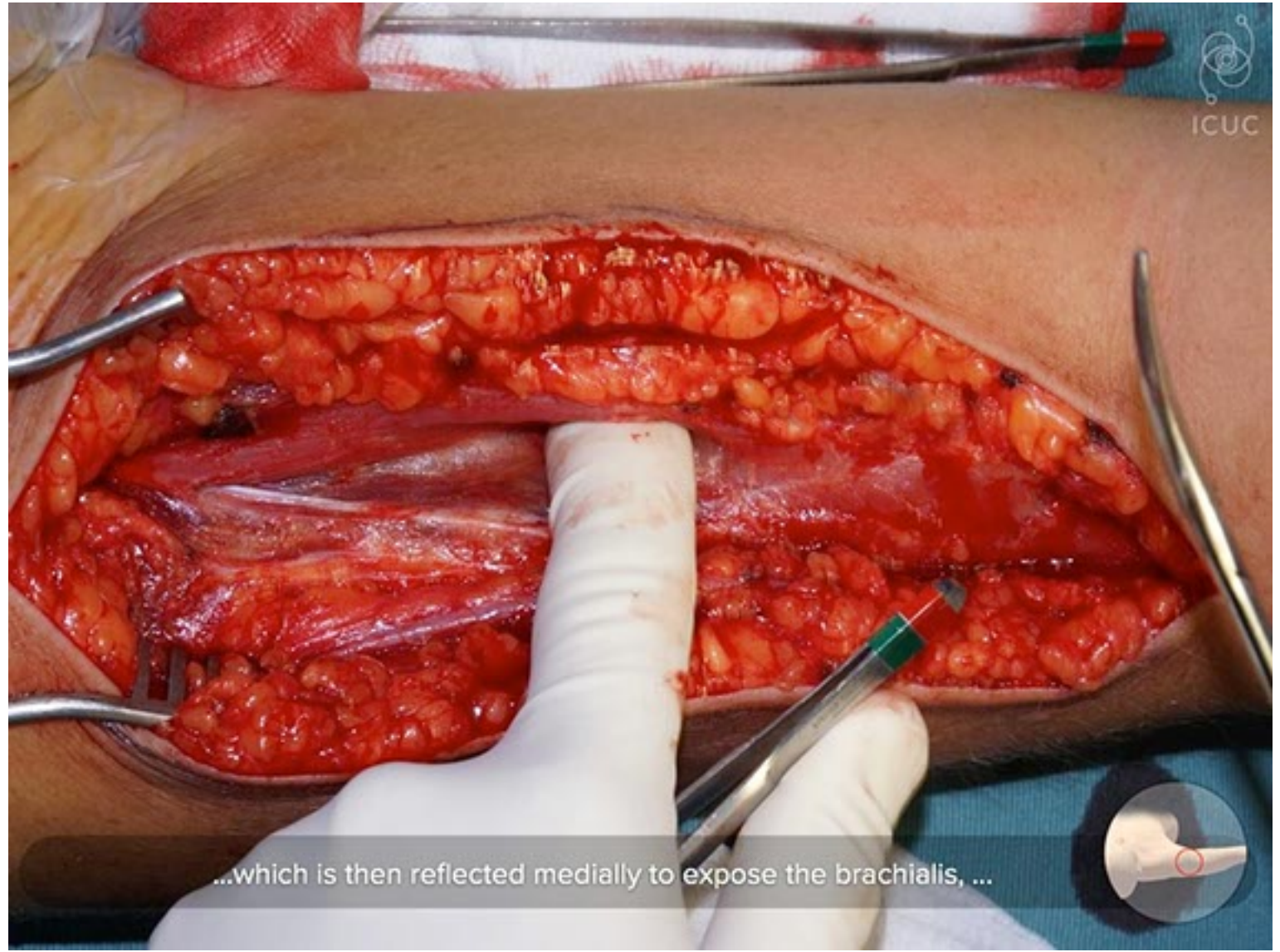




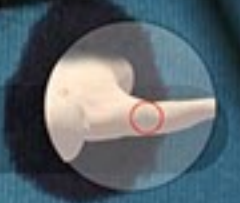
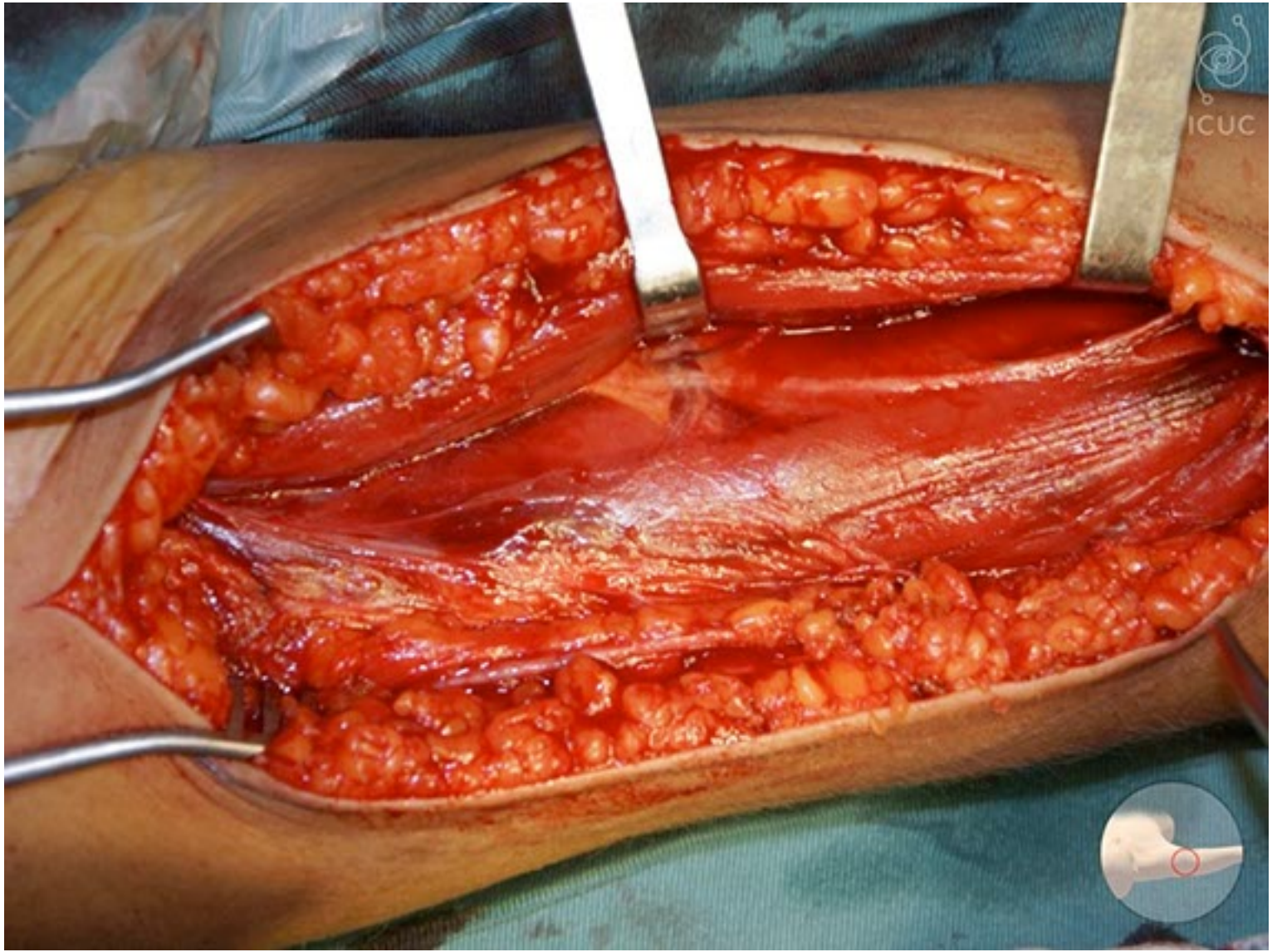


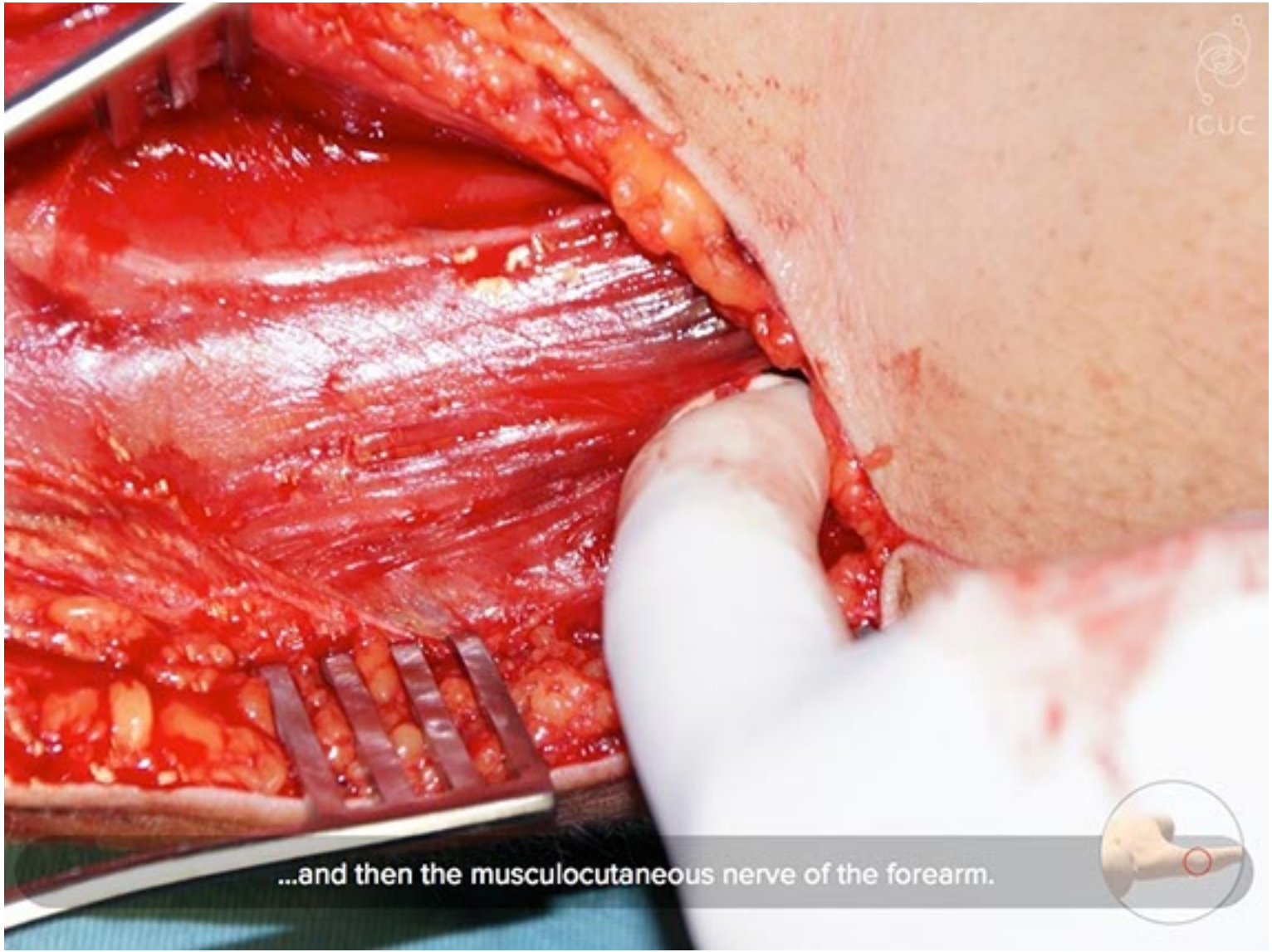




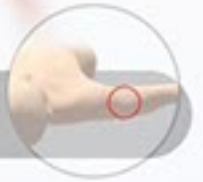...which is then reflected medially to expose the brachialis, ...

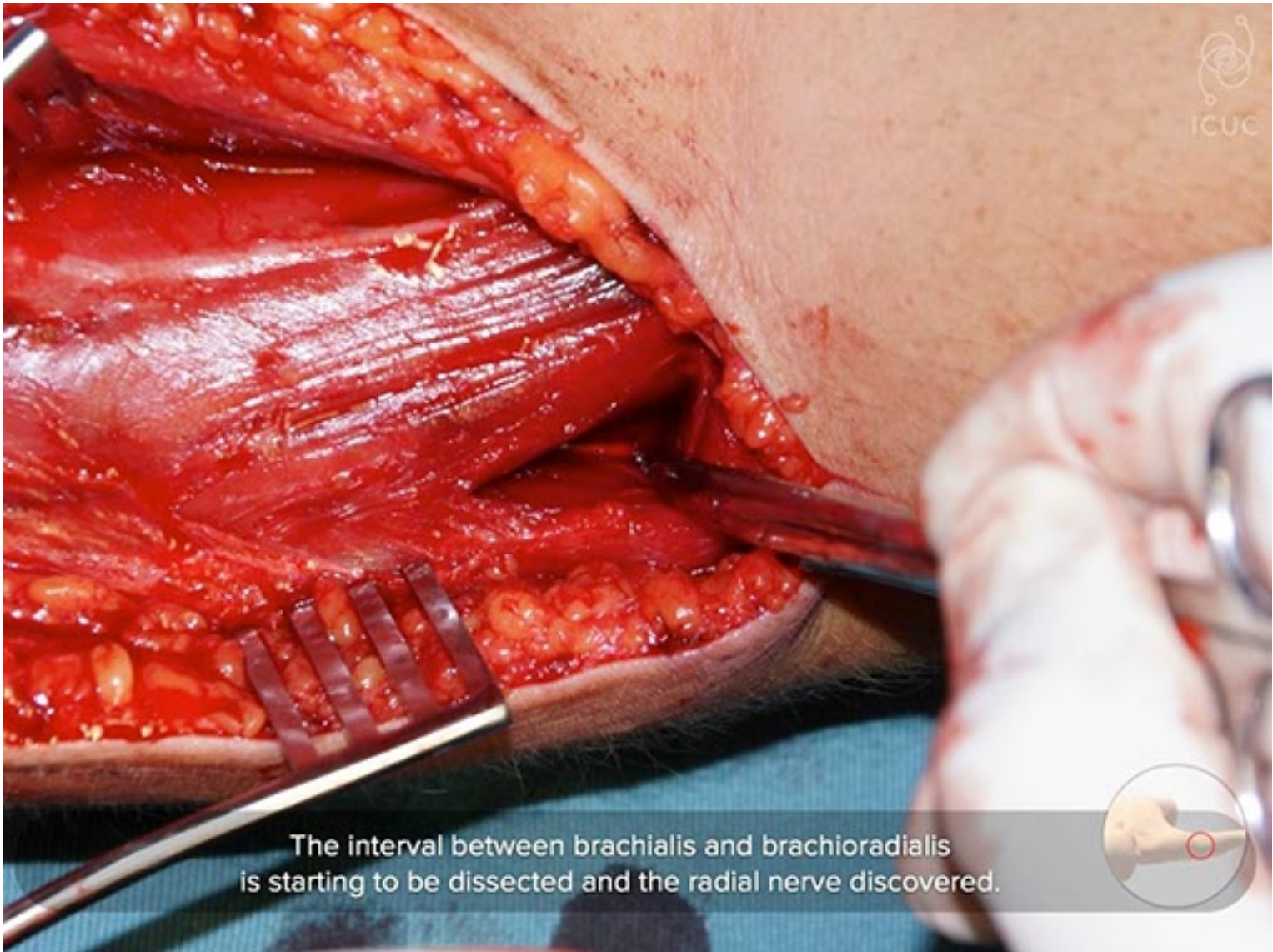




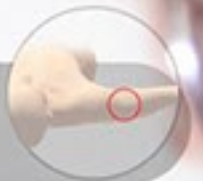
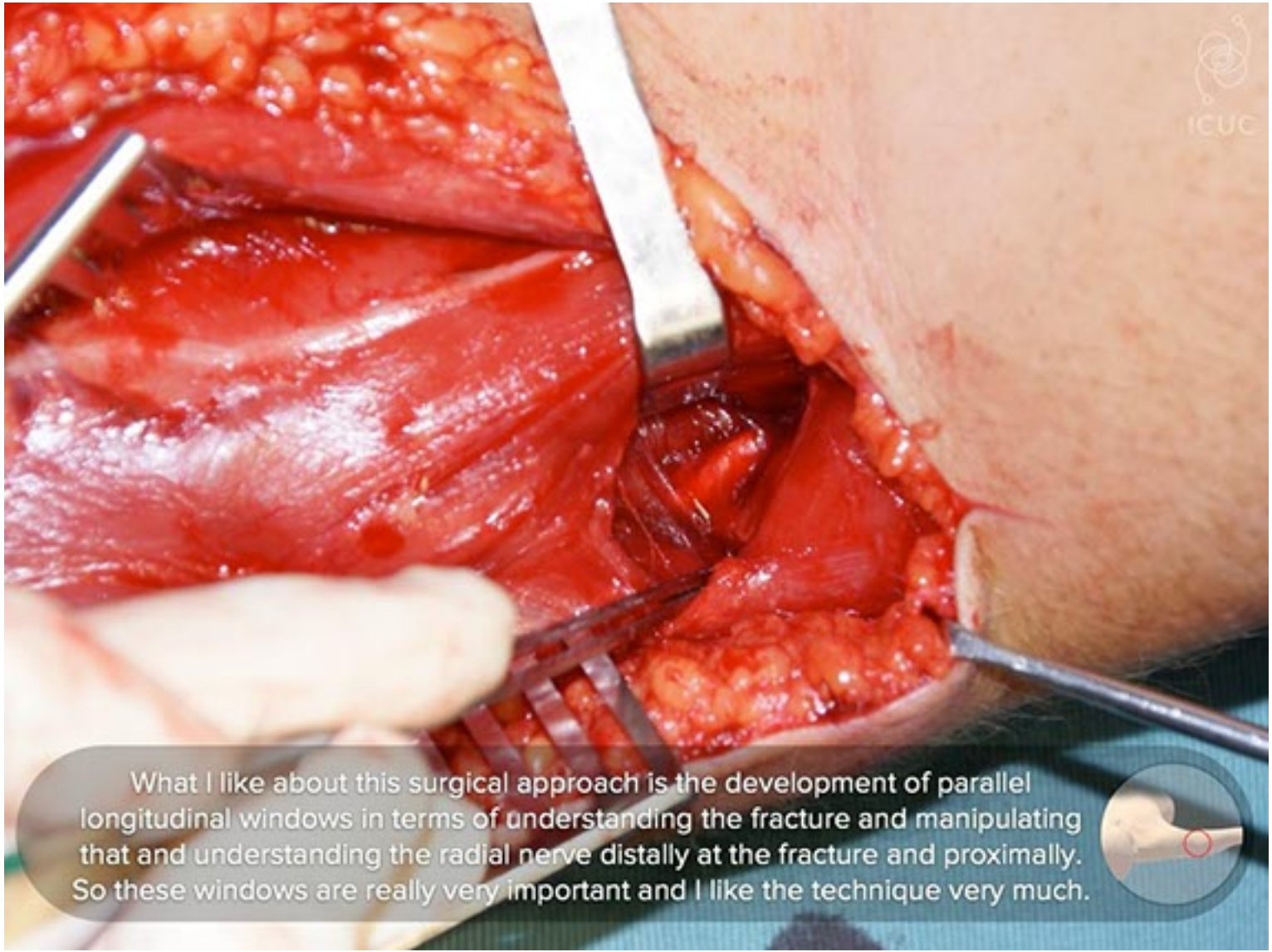
...and then the musculocutaneous nerve of the forearm.



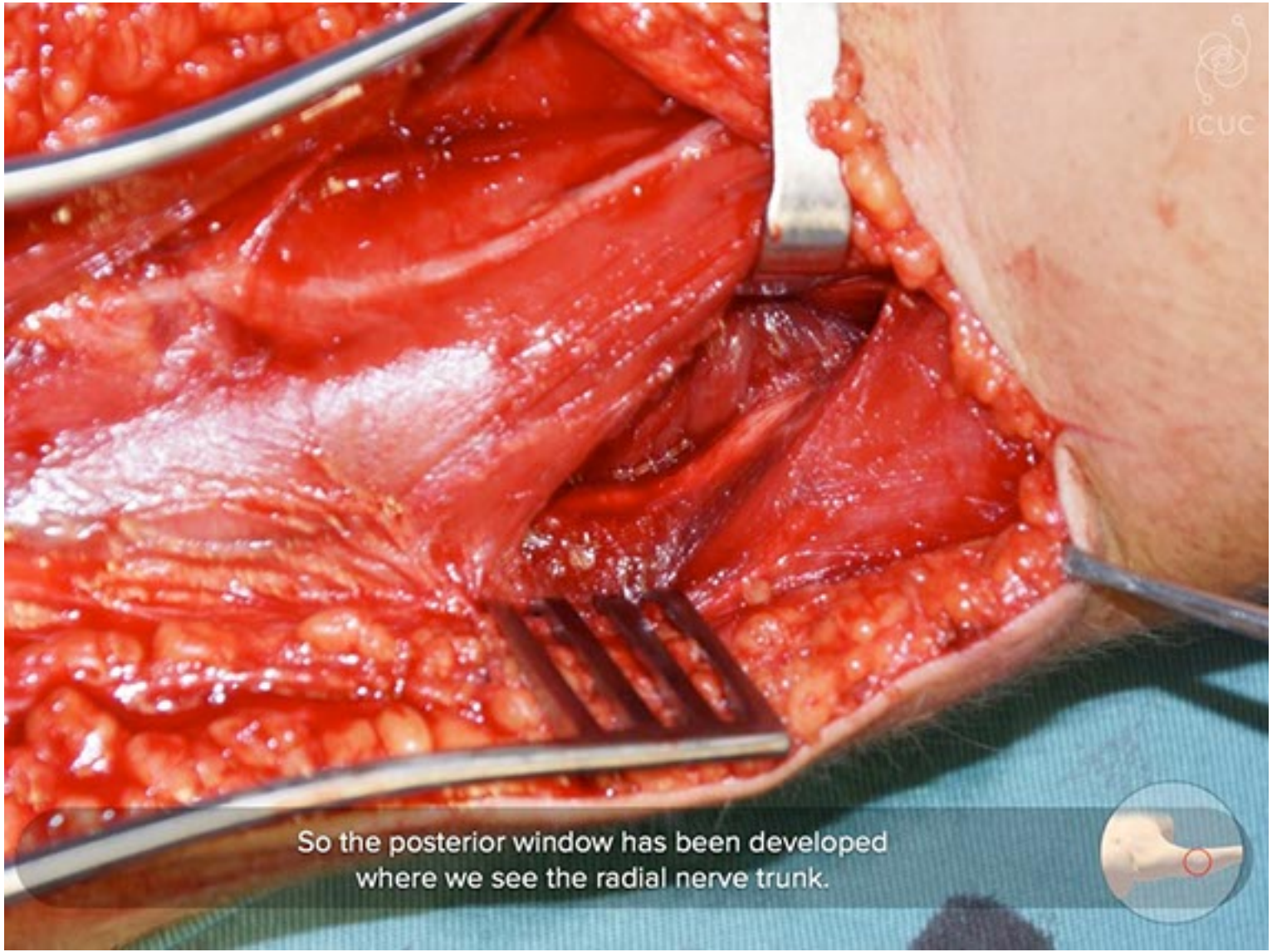


The interval between brachialis and brachioradialis is starting to be dissected and the radial nerve discovered.



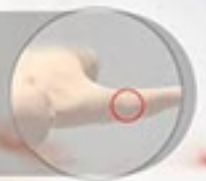

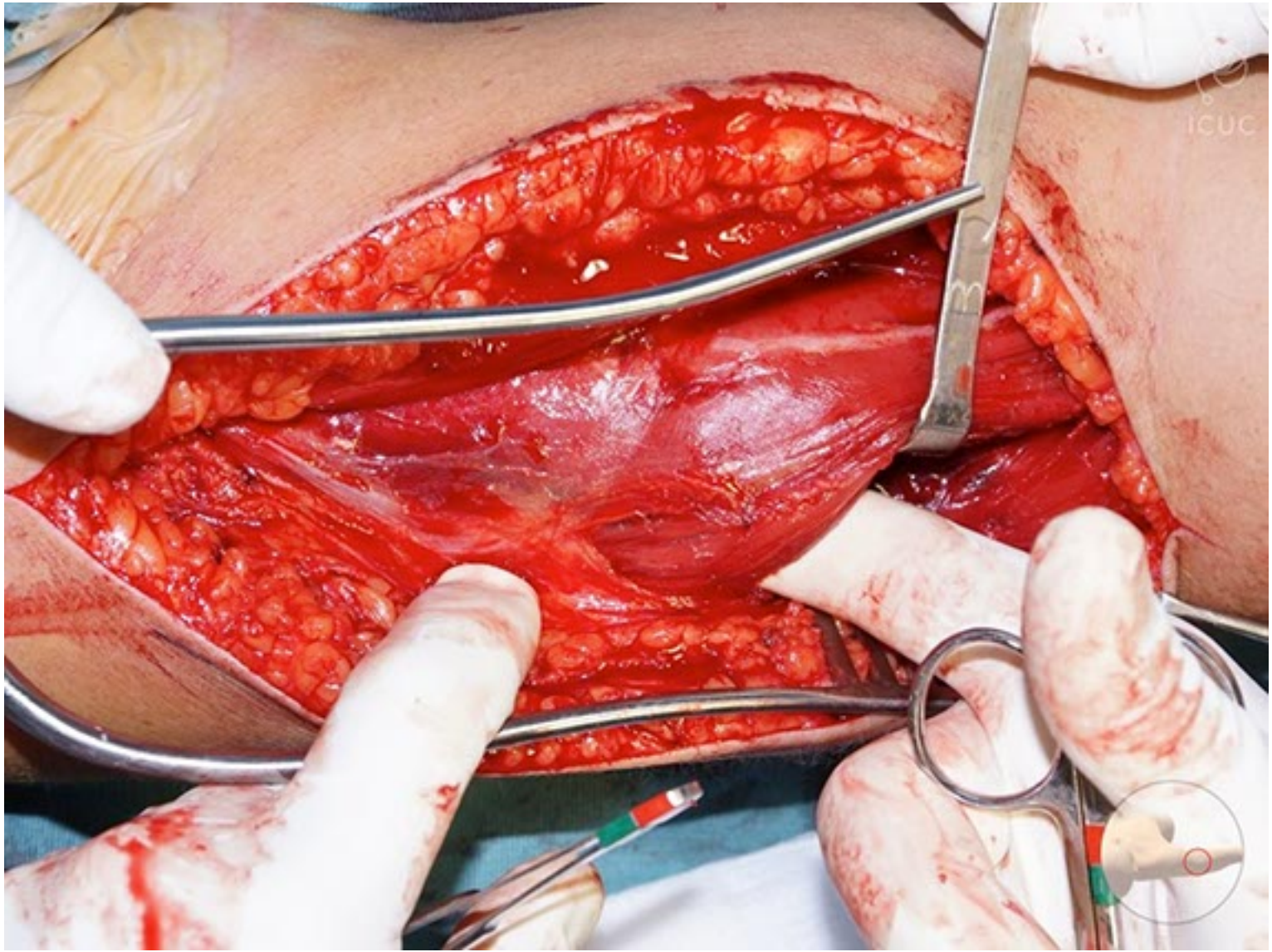
What I like about this surgical approach is the development of parallel longitudinal windows in terms of understanding the fracture and manipulating that and understanding the radial nerve distally at the fracture and proximally. So these windows are really very important and I like the technique very much.

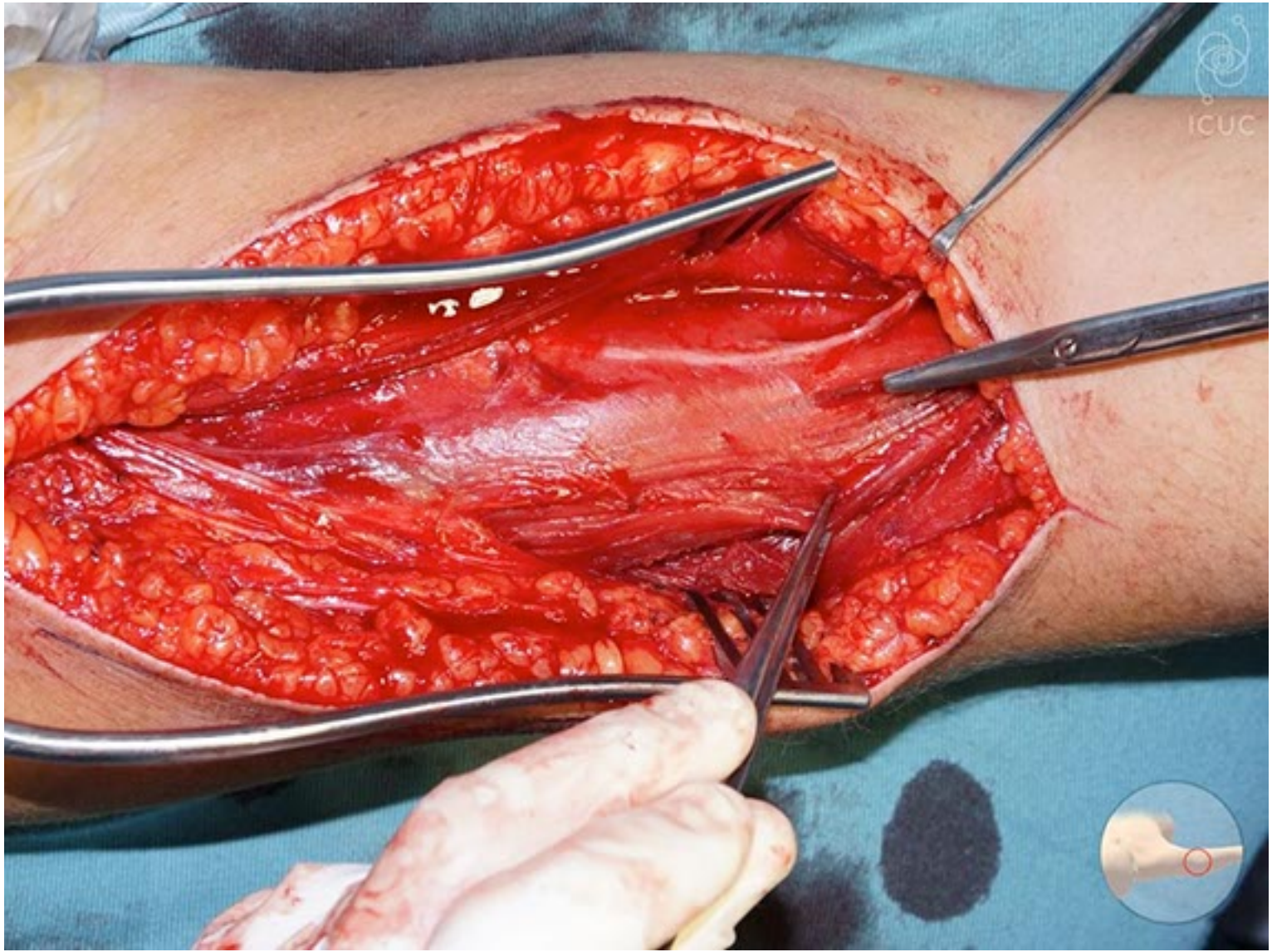


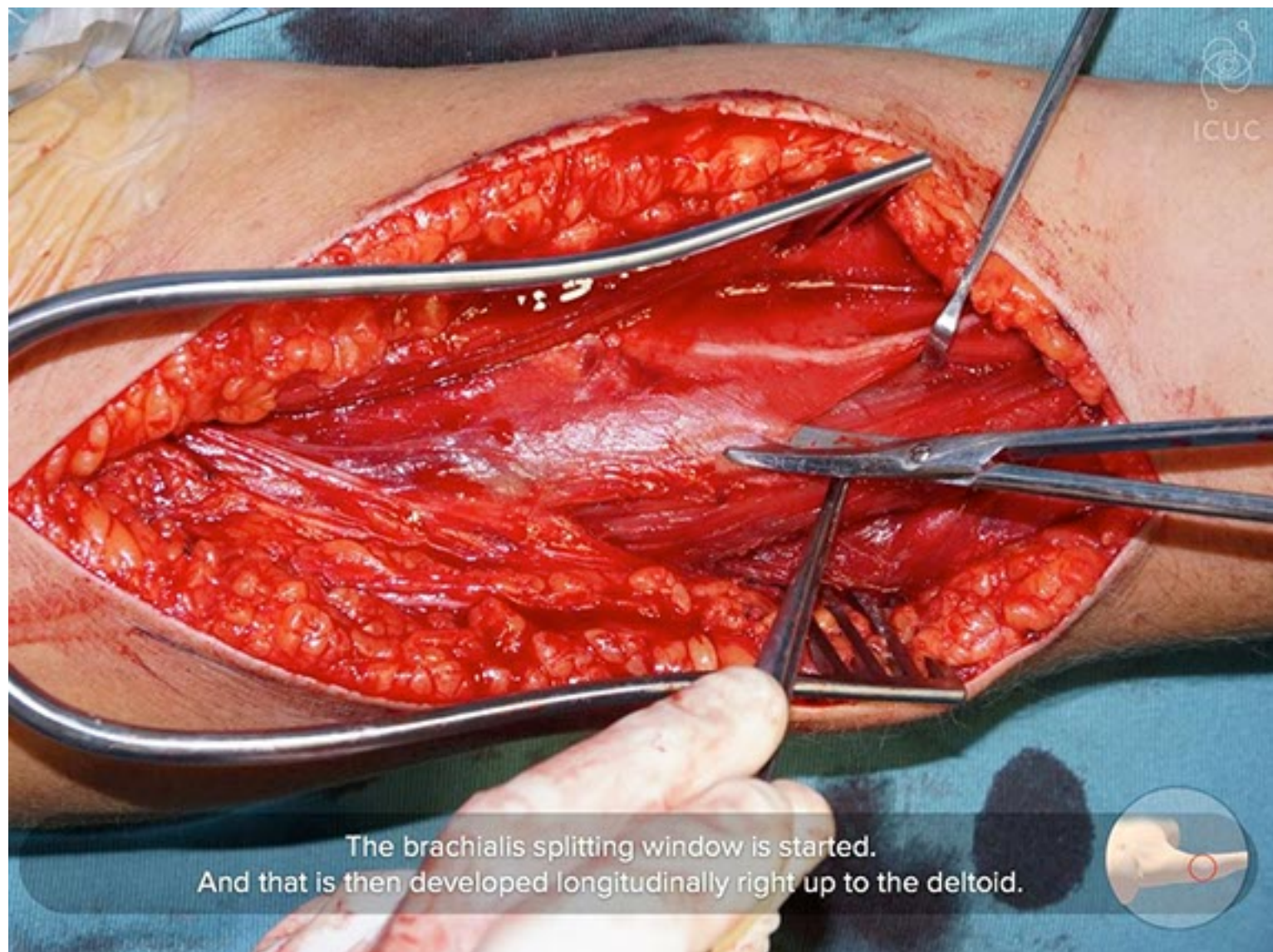
So the posterior window has been developed where we see the radial nerve trunk.

And then following the nerve trunk on the lateral intermuscular septum and taking brachialis off that septum more proximally, the radial nerve is followed up to the humerus.

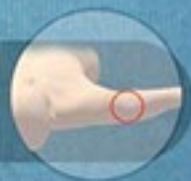

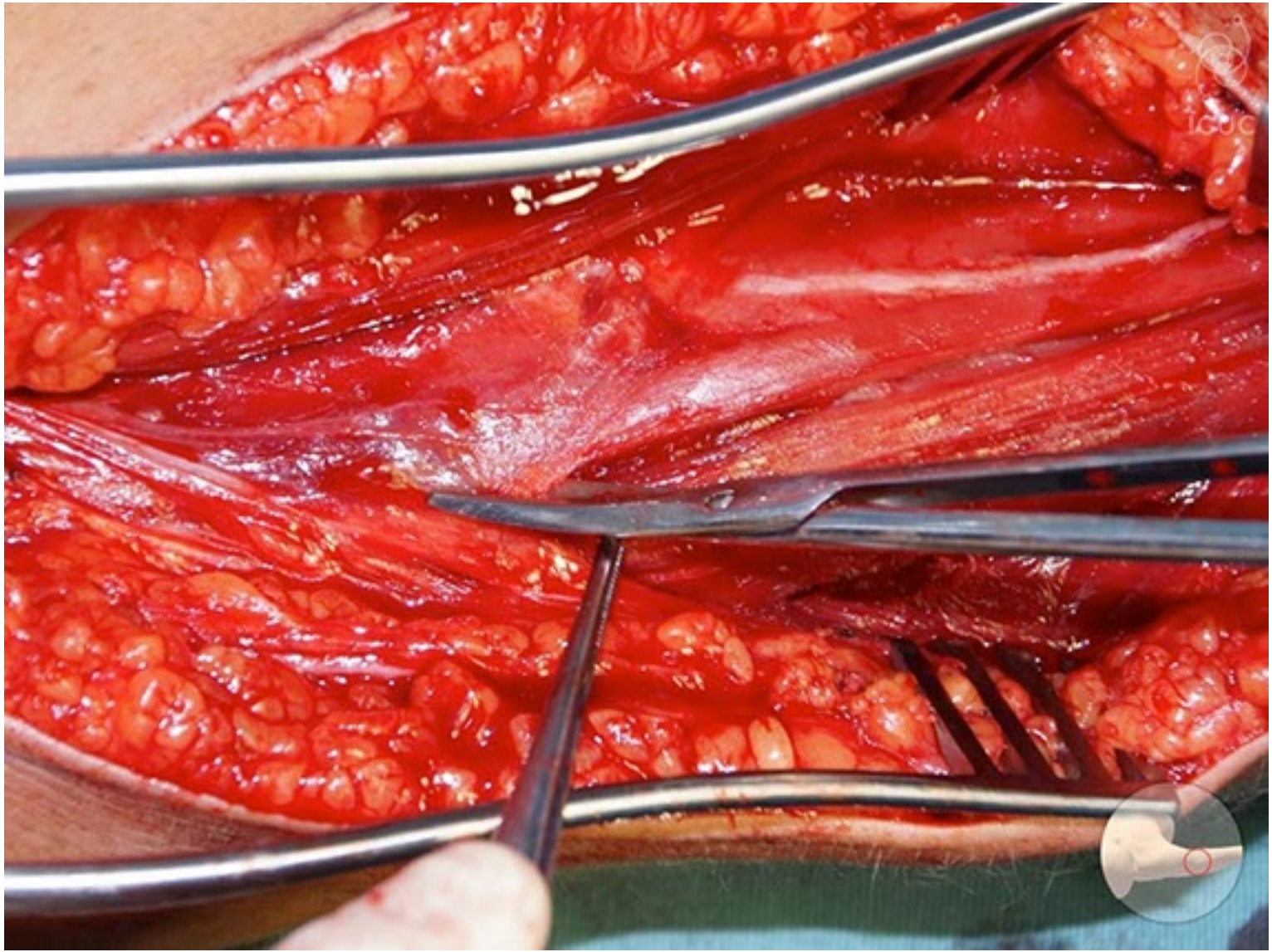



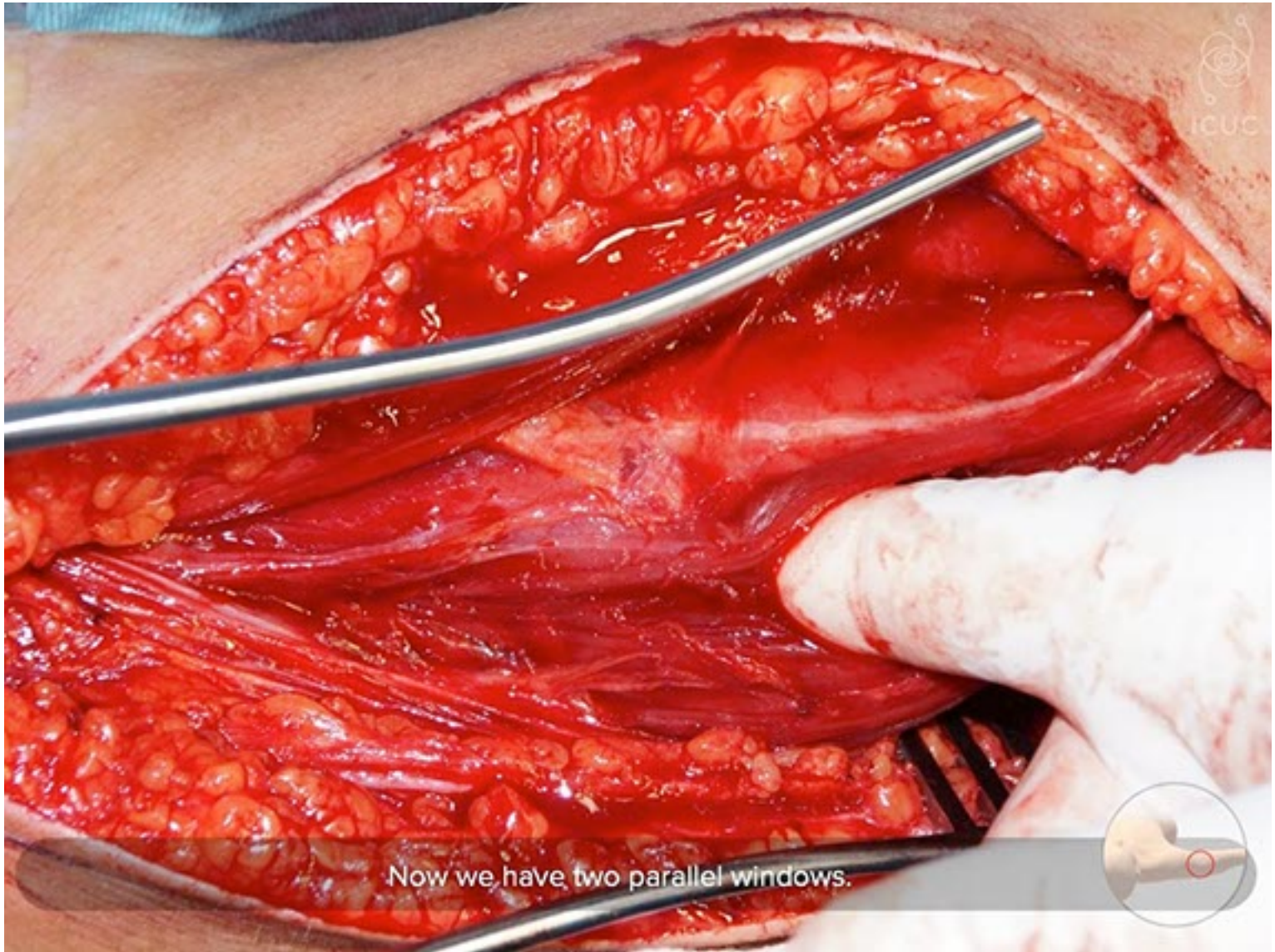



The brachialis splitting window is started.
And that is then developed longitudinally right up to the deltoid.



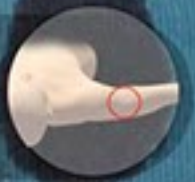

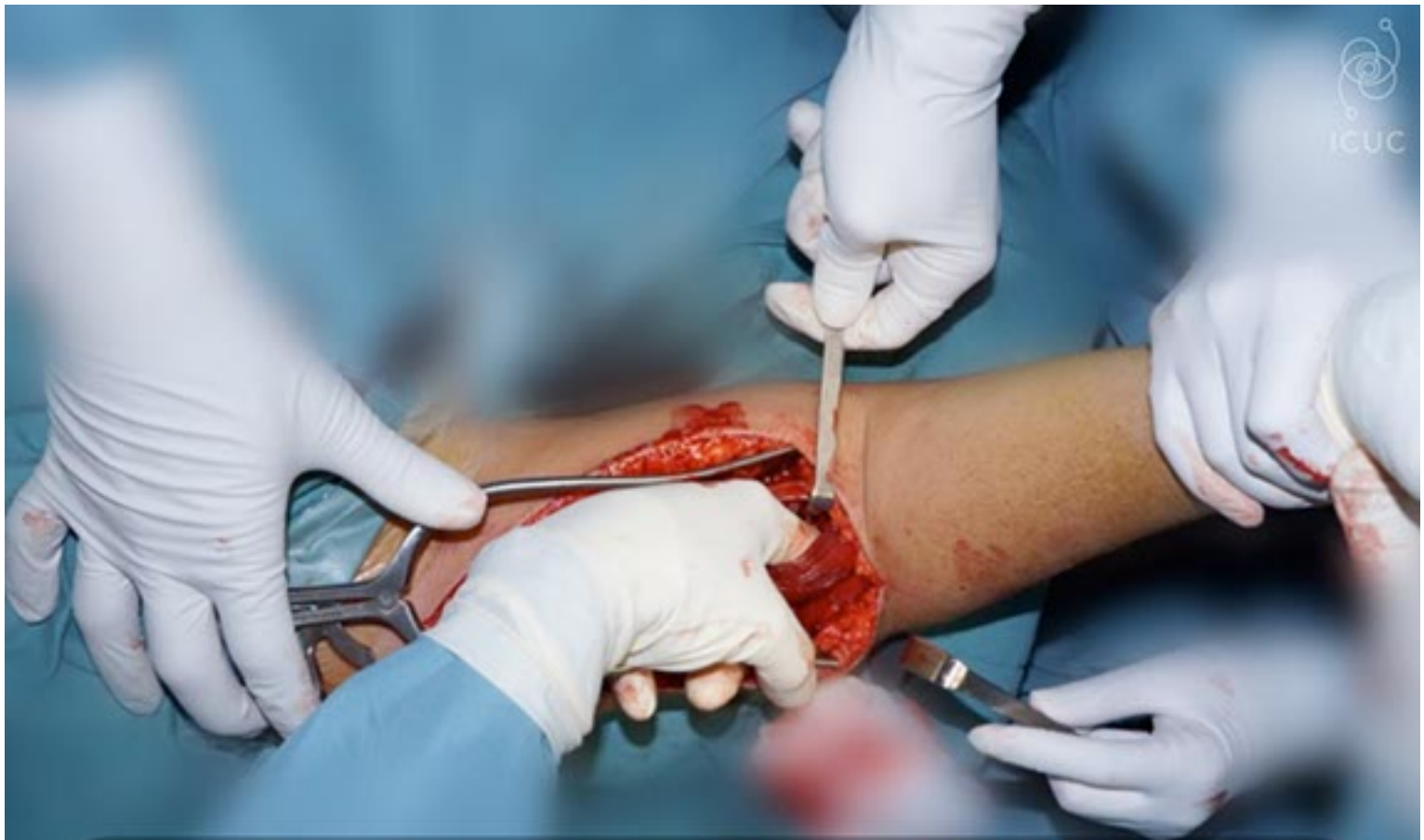


Now we have two parallel windows.

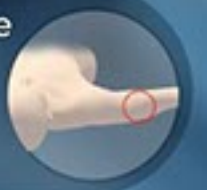

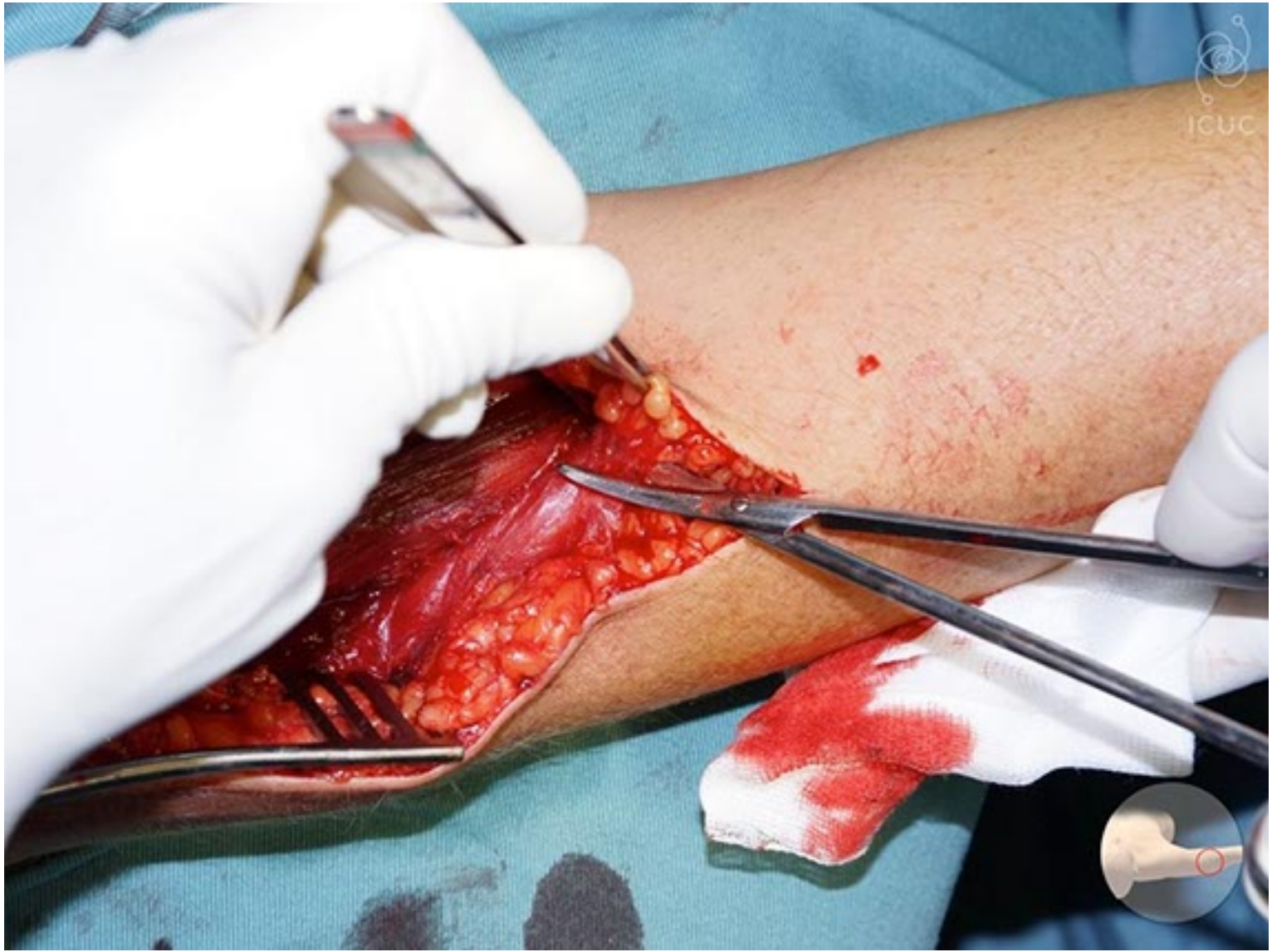One inside brachialis exposing the fracture and one posterior.
And working between these two windows
was a very important aspect to this exposure.

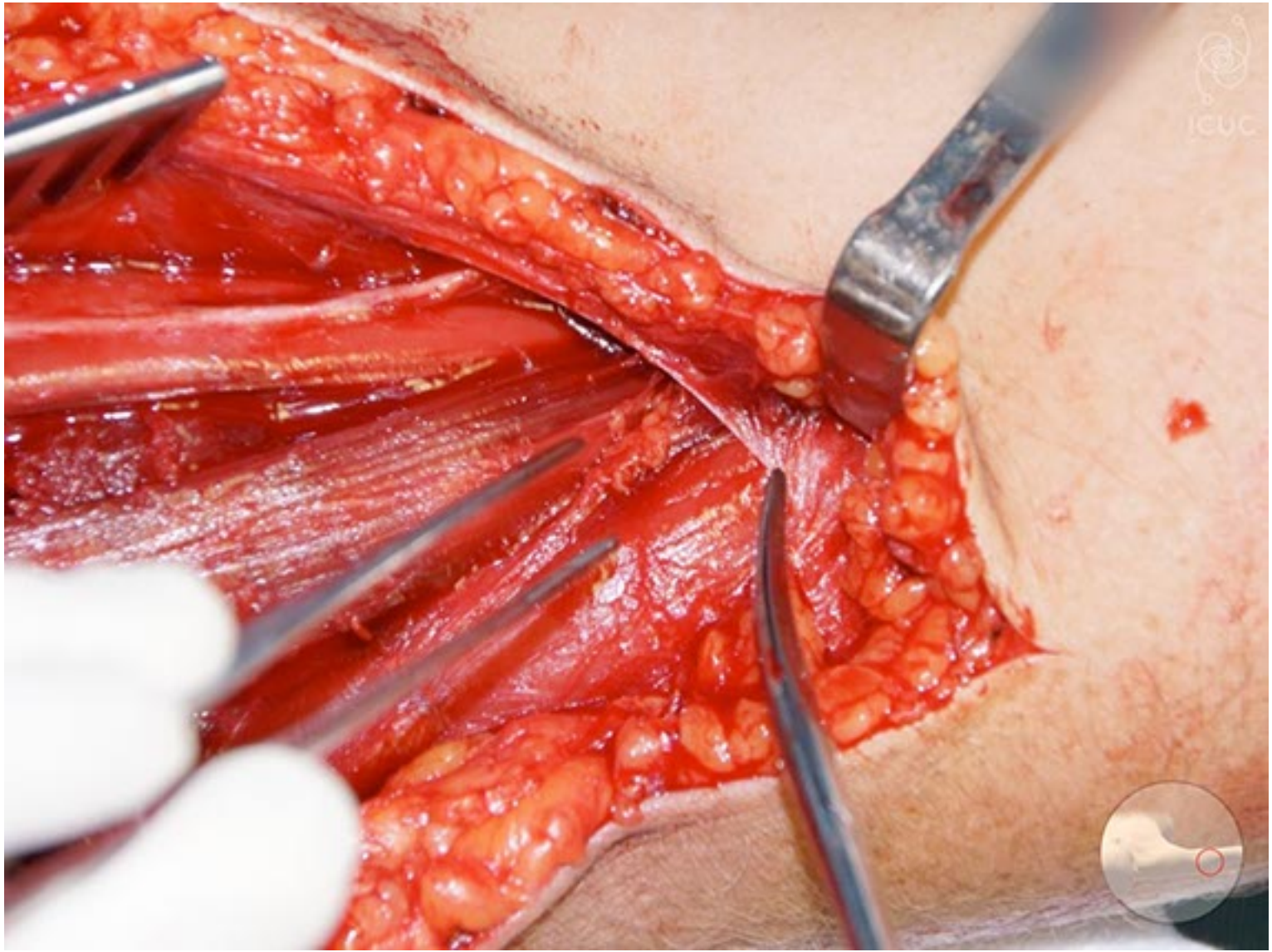


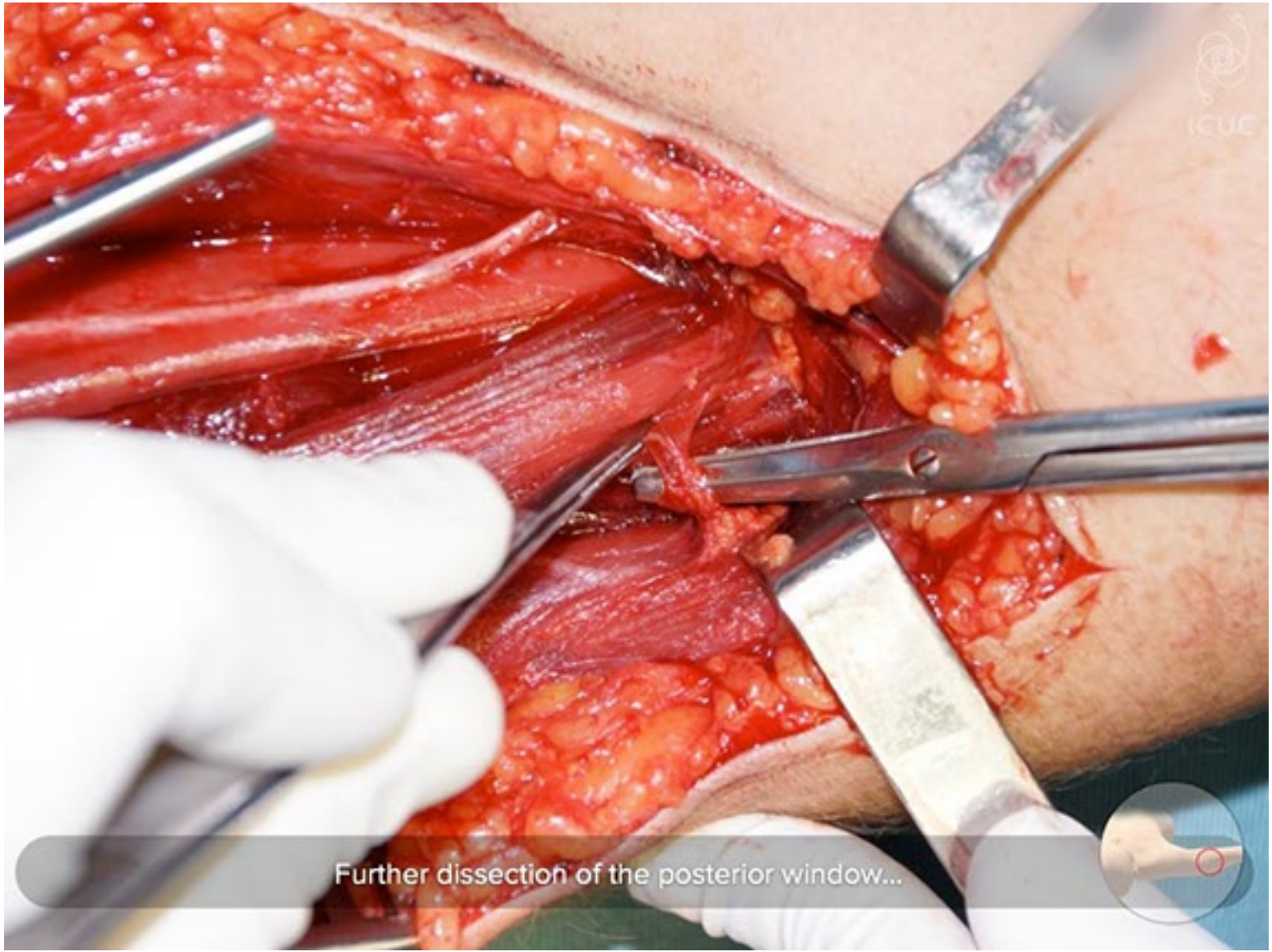


And I think the nice thing that this illustrates is the ability to handle the fracture and the radial nerve simultaneously through different windows. Whether if you only had one window, we'll either be guessing where the radial nerve is, or under powering dissection of the fracture.

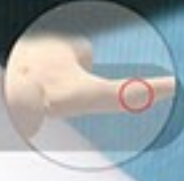


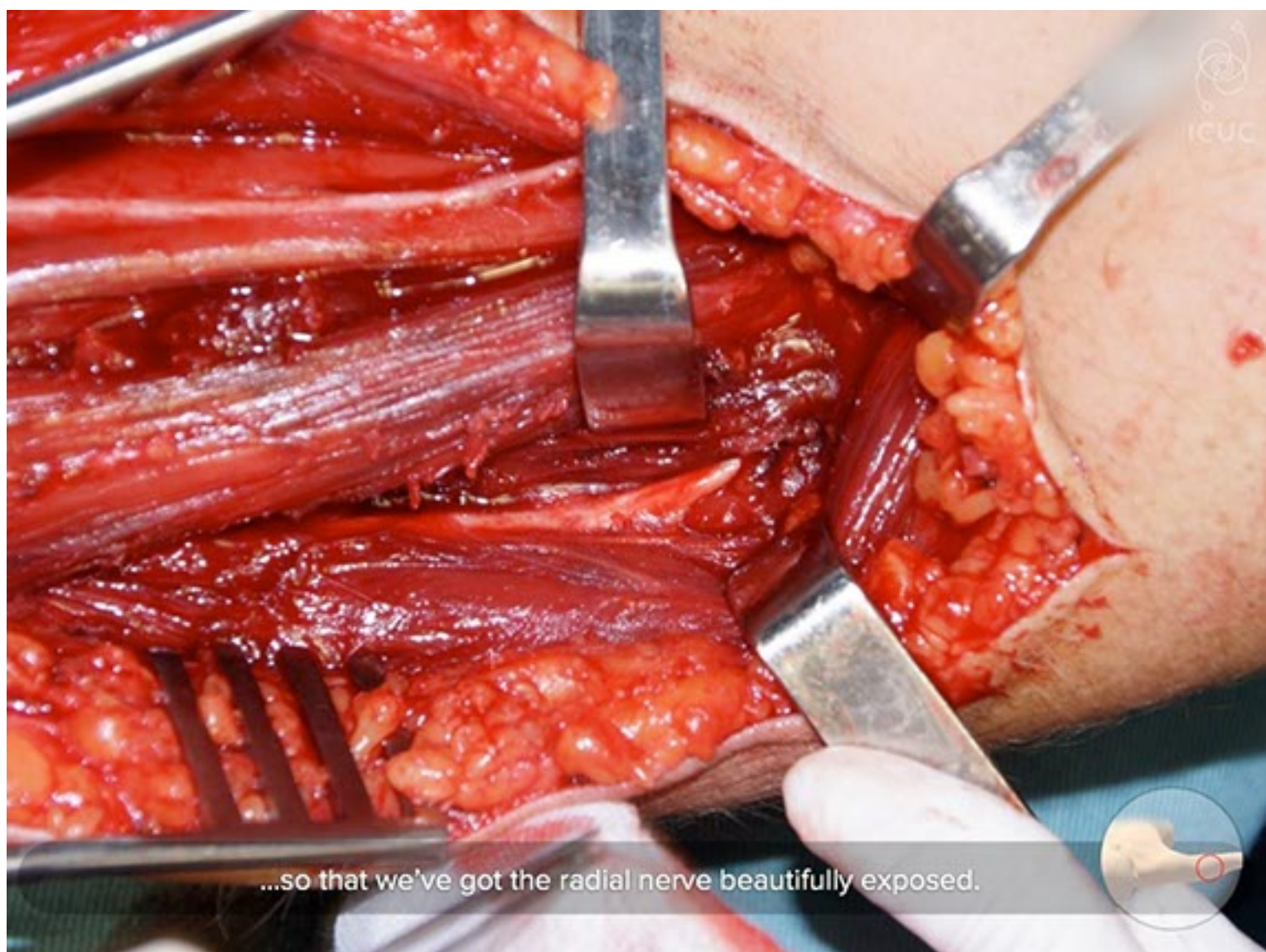




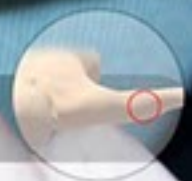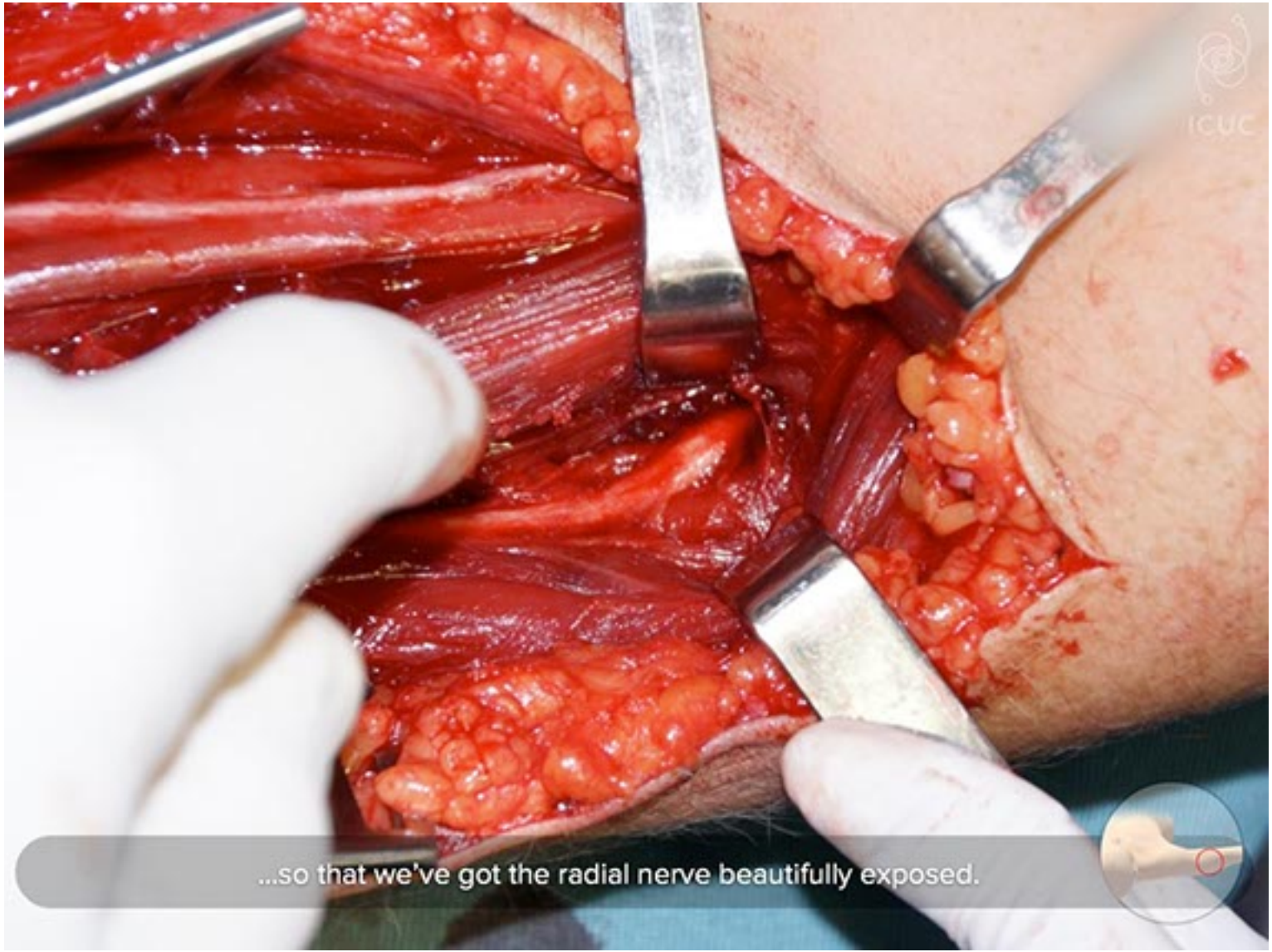Further dissection of the posterior window...



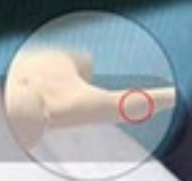

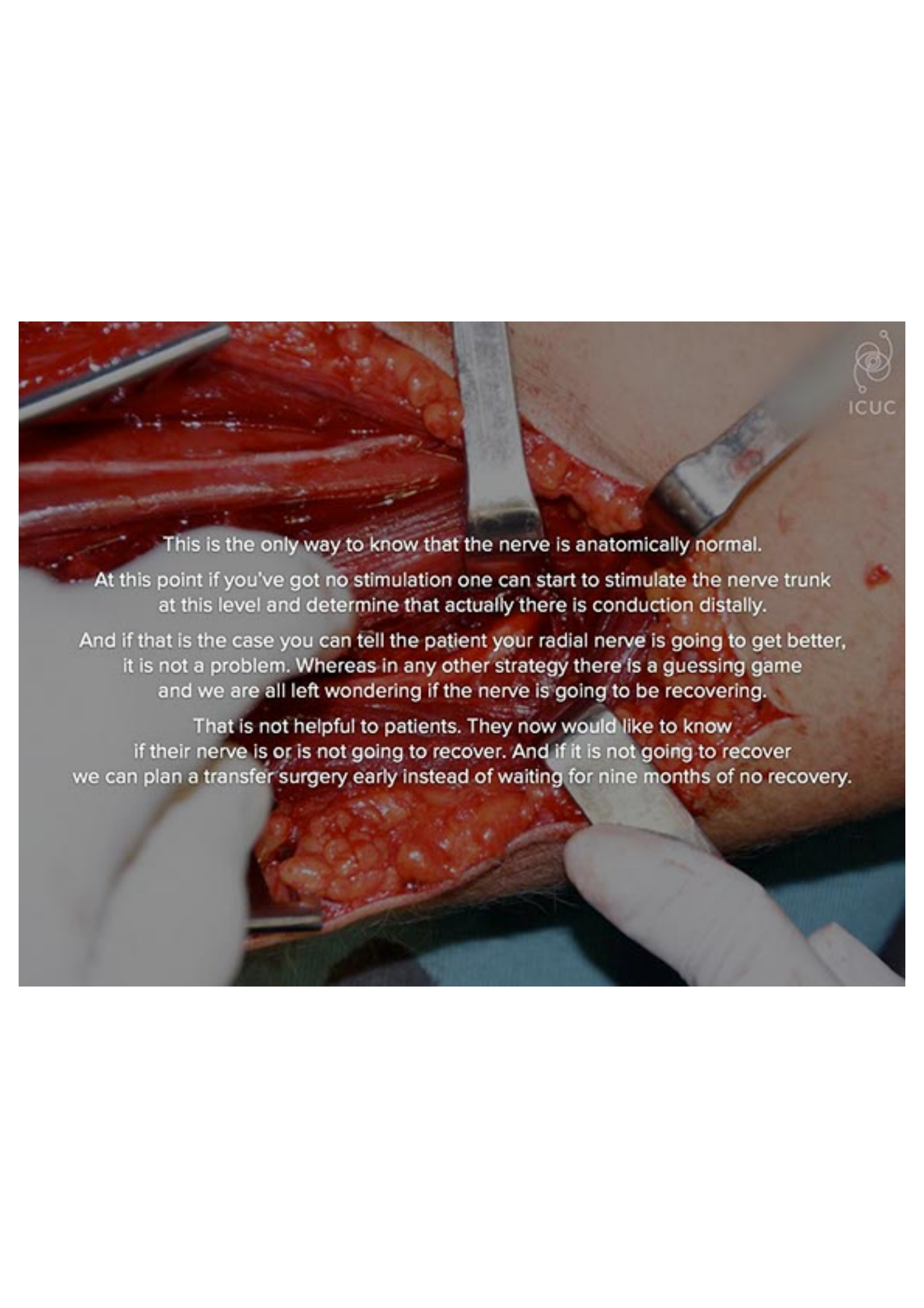
...so that we've got the radial nerve beautifully exposed.





...so that we've got the radial nerve beautifully exposed.



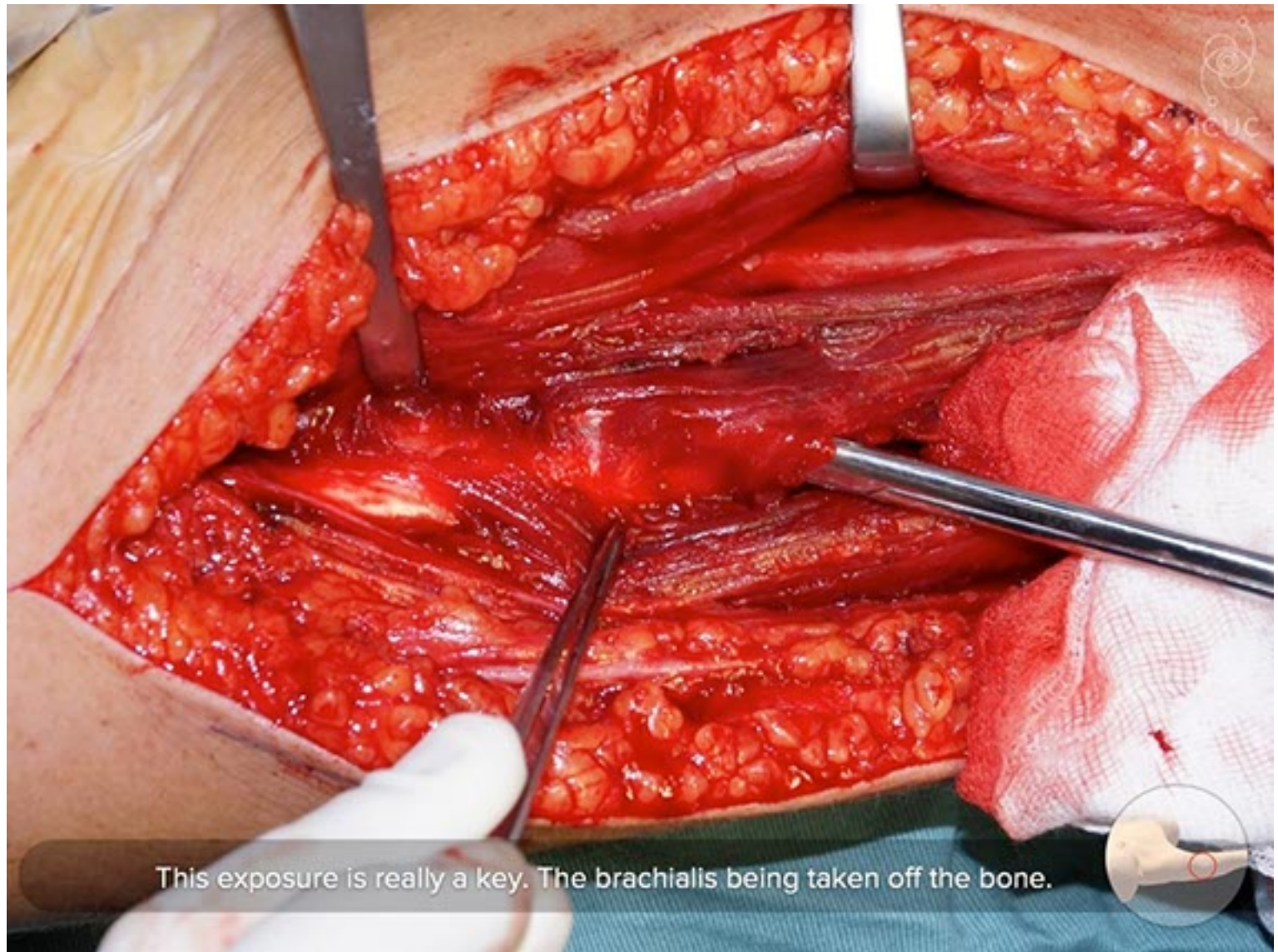

This is the only way to know that the nerve is anatomically normal.

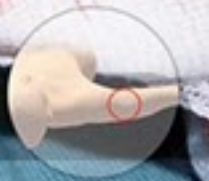At this point if you've got no stimulation one can start to stimulate the nerve trunk at this level and determine that actually there is conduction distally.

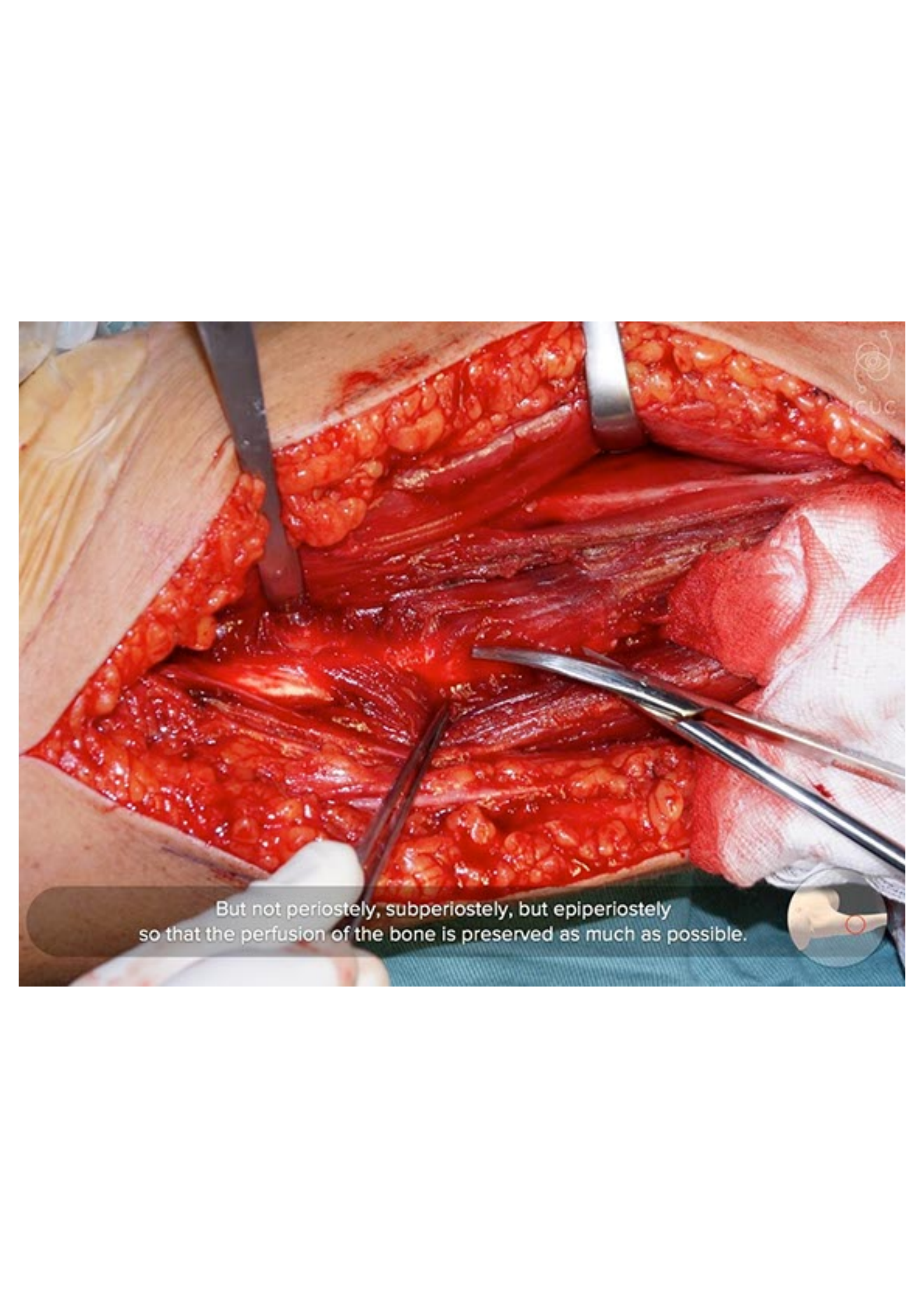
And if that is the case you can tell the patient your radial nerve is going to get better, it is not a problem. Whereas in any other strategy there is a guessing game and we are all left wondering if the nerve is going to be recovering.

That is not helpful to patients. They now would like to know if their nerve is or is not going to recover. And if it is not going to recover we can plan a transfer surgery early instead of waiting for nine months of no recovery.

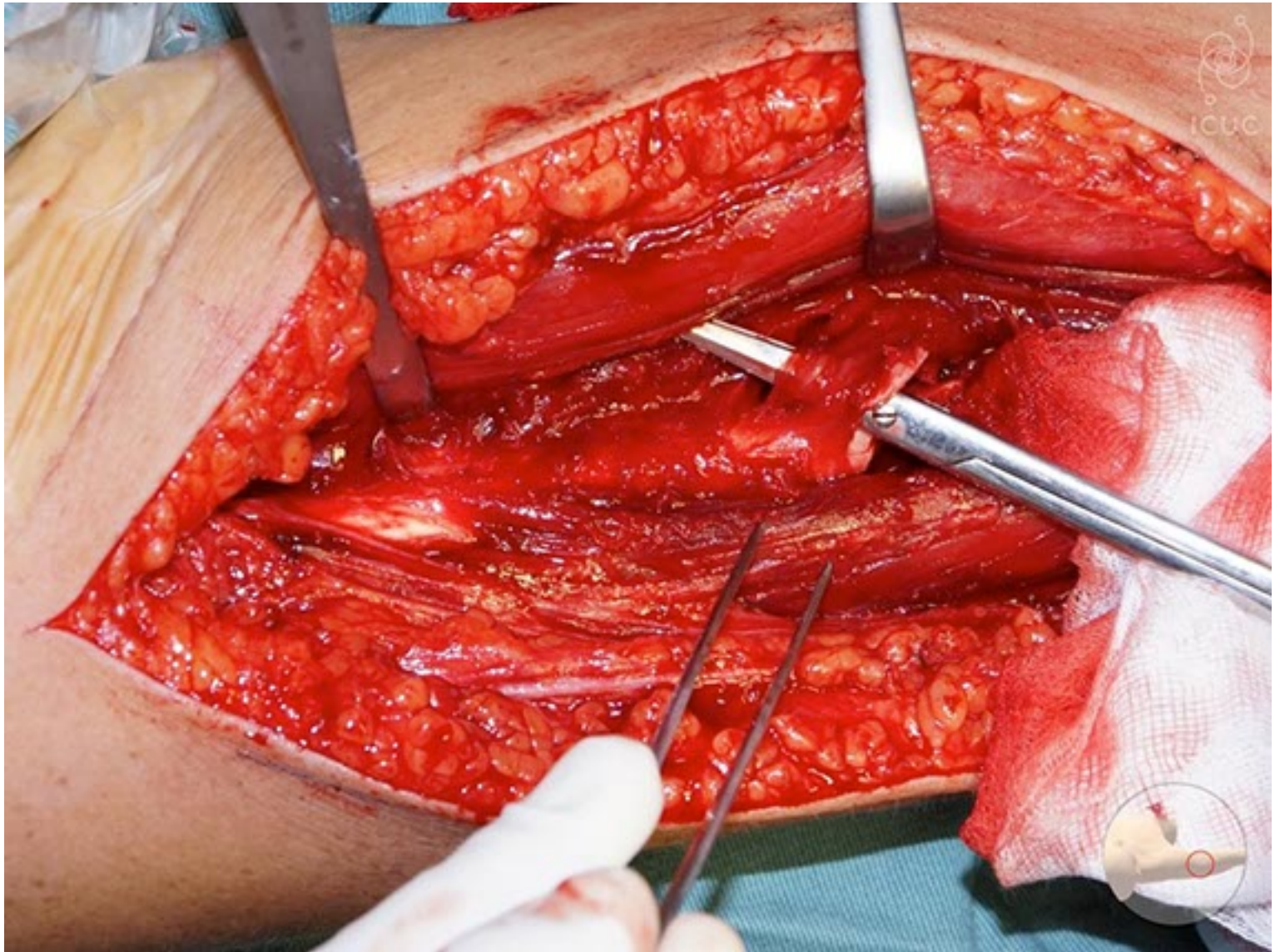


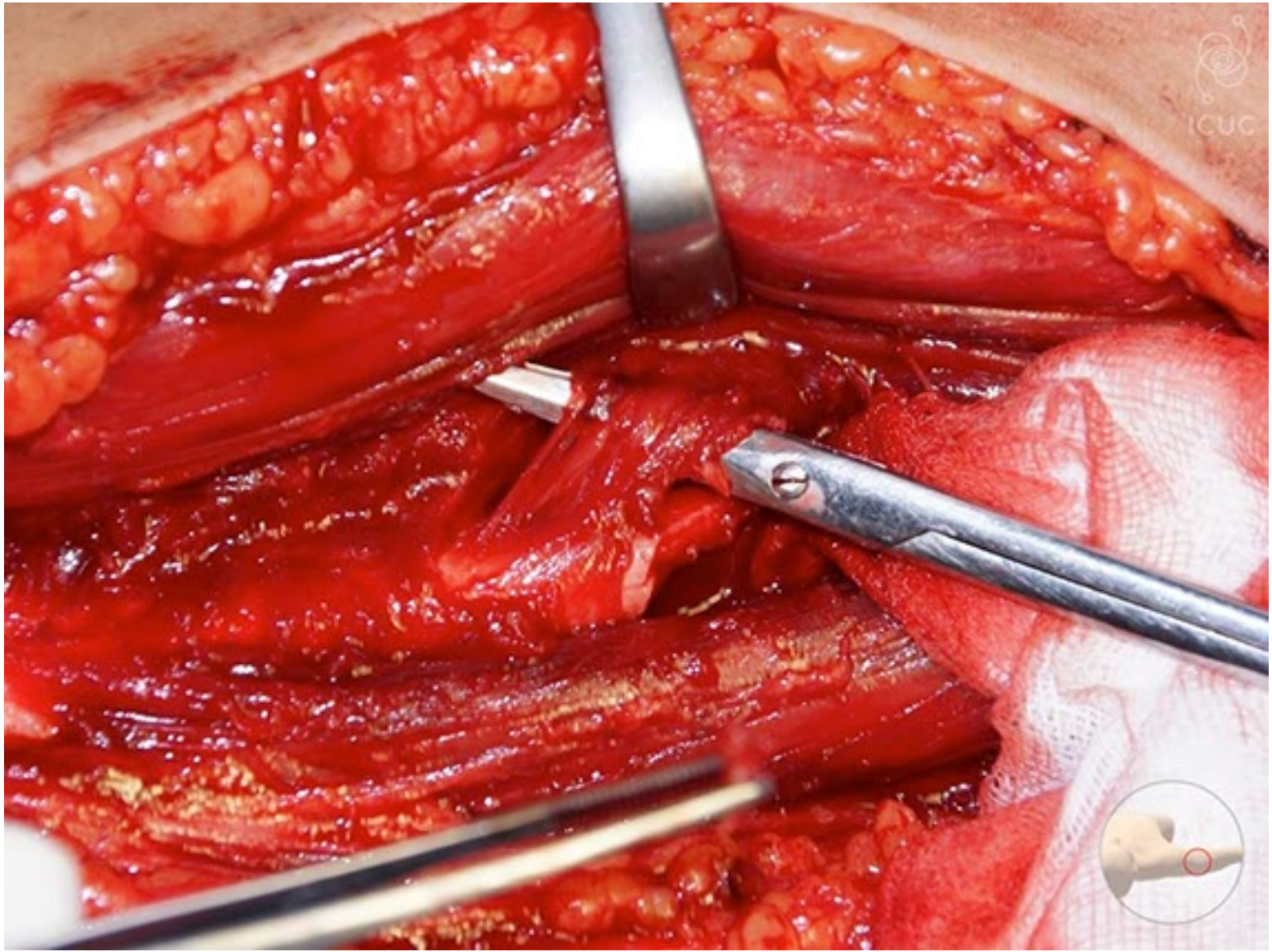
This exposure is really a key. The brachialis being taken off the bone.



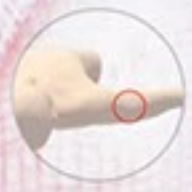An intraoperative photograph showing a surgical dissection of a bone. The bone is the central focus, surrounded by muscle and soft tissue. Surgical instruments, including a scalpel and forceps, are visible. The dissection is performed epiperiosteally, meaning the periosteum is being lifted off the bone from the outside. A small circular inset in the bottom right corner shows a diagram of a bone with a red circle highlighting the epiperiosteal dissection site. In the top right corner, there is a logo for 'ruc' with a stylized eye icon.

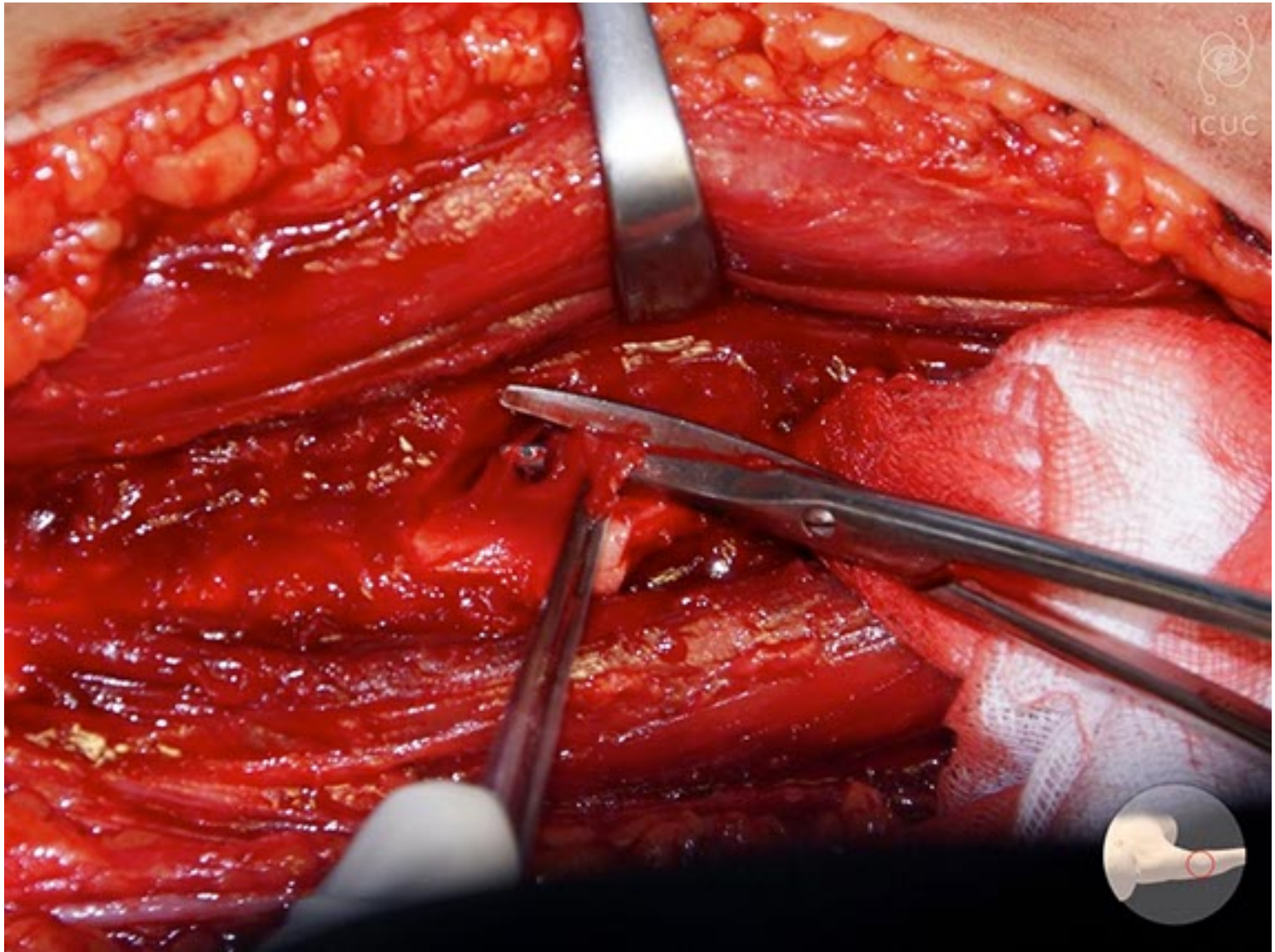But not periosteally, subperiosteally, but epiperiosteally
so that the perfusion of the bone is preserved as much as possible.

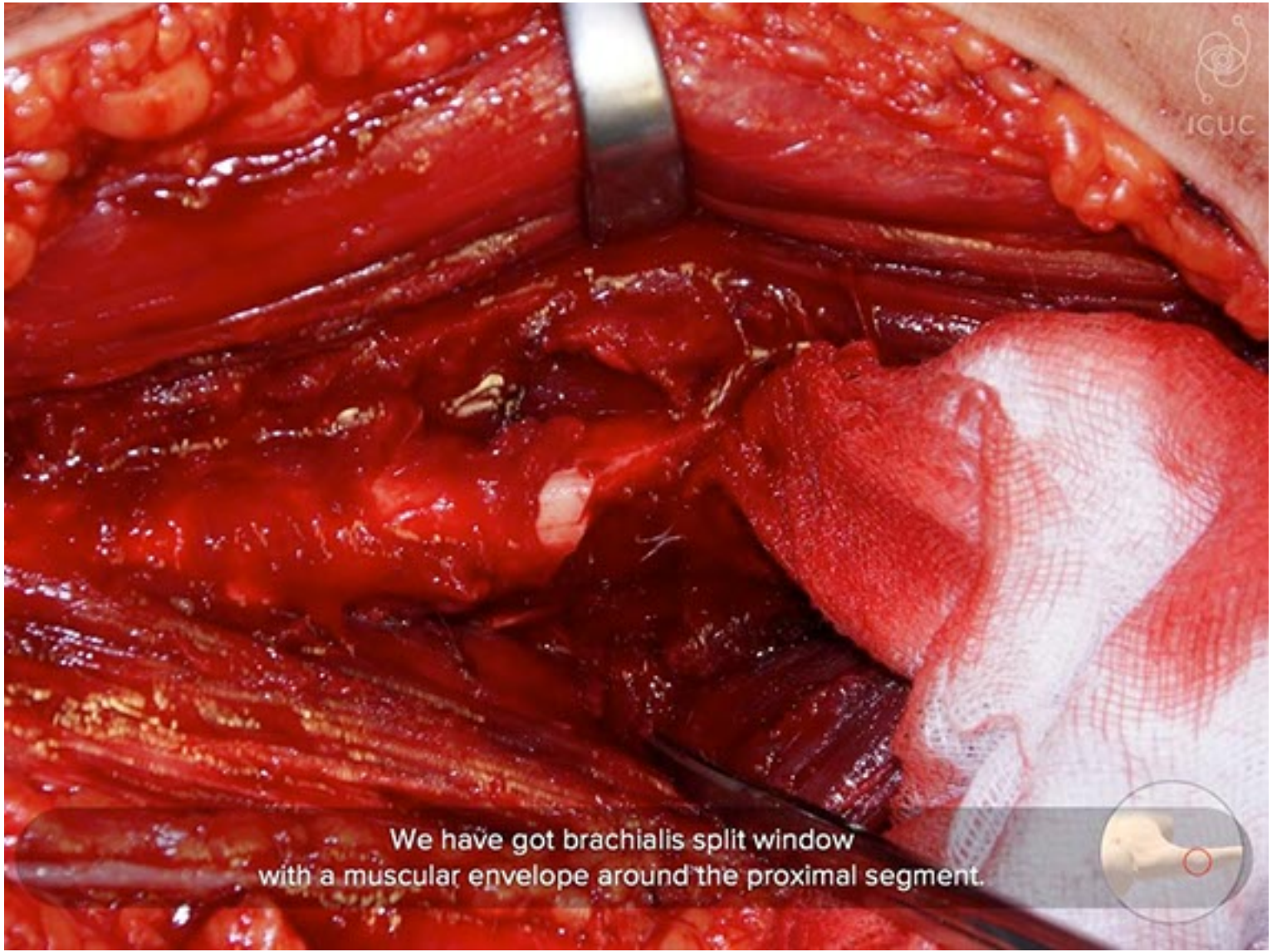



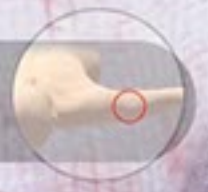icuc

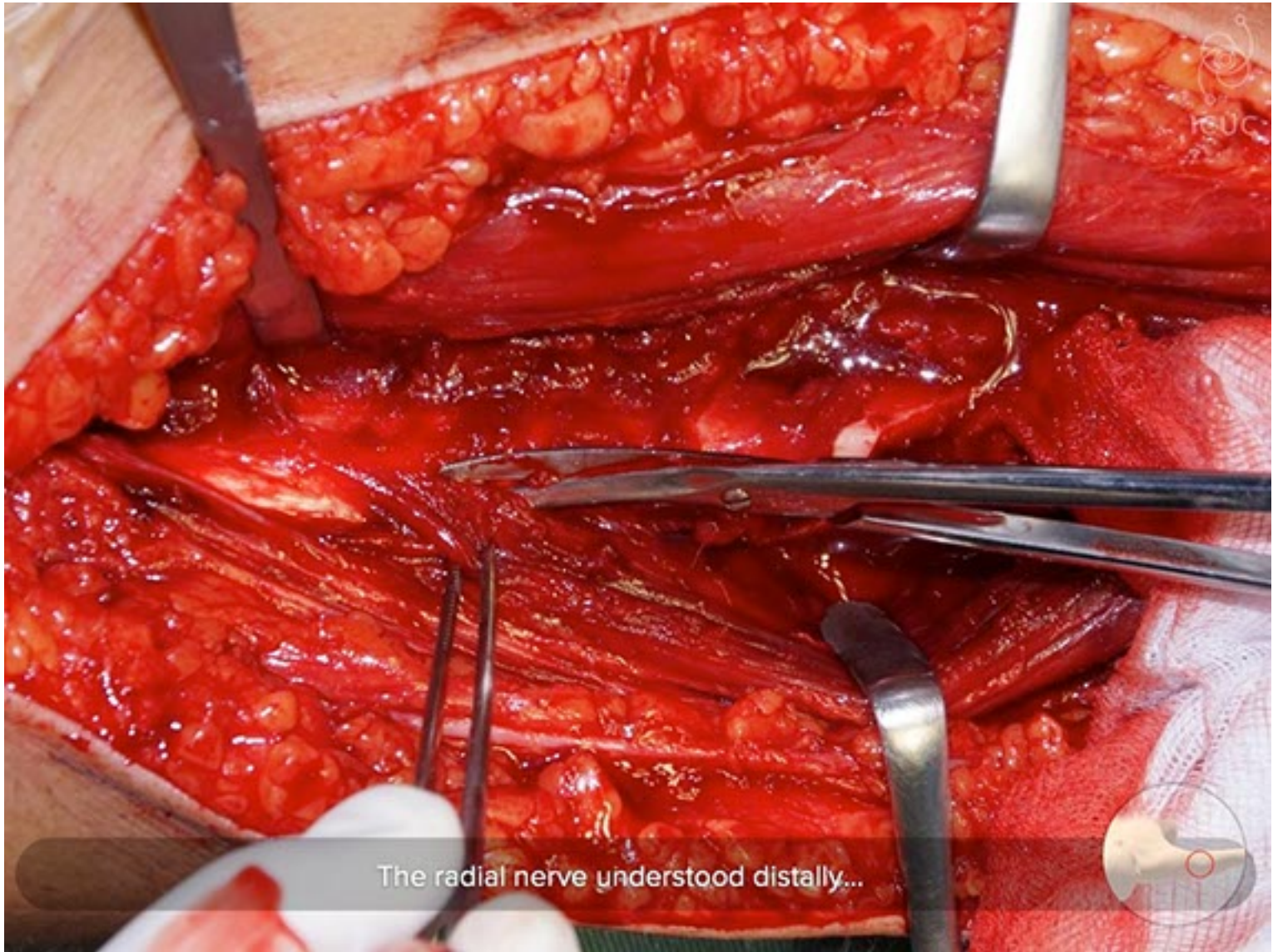



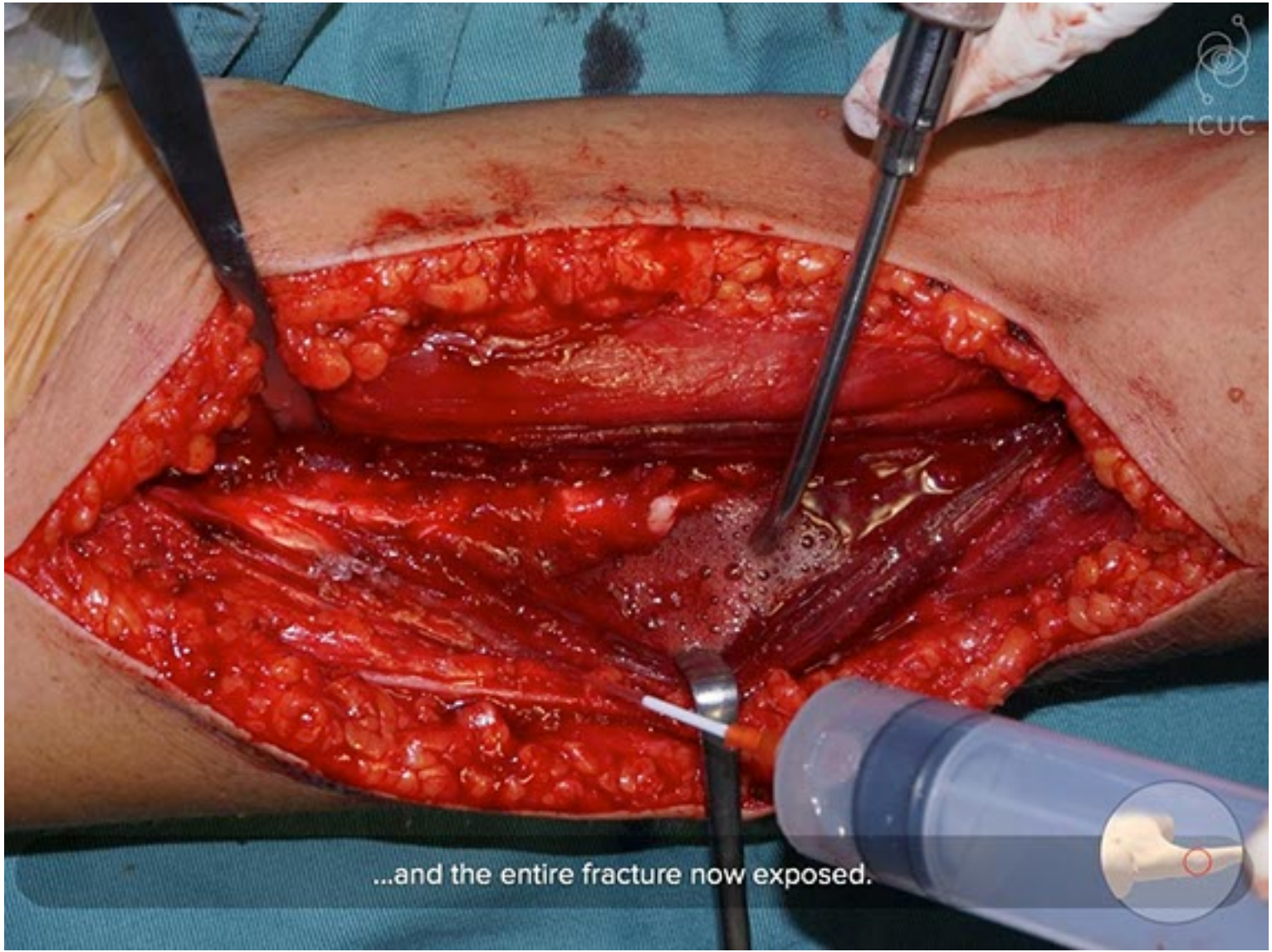


We have got brachialis split window with a muscular envelope around the proximal segment.

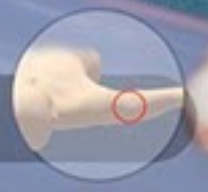


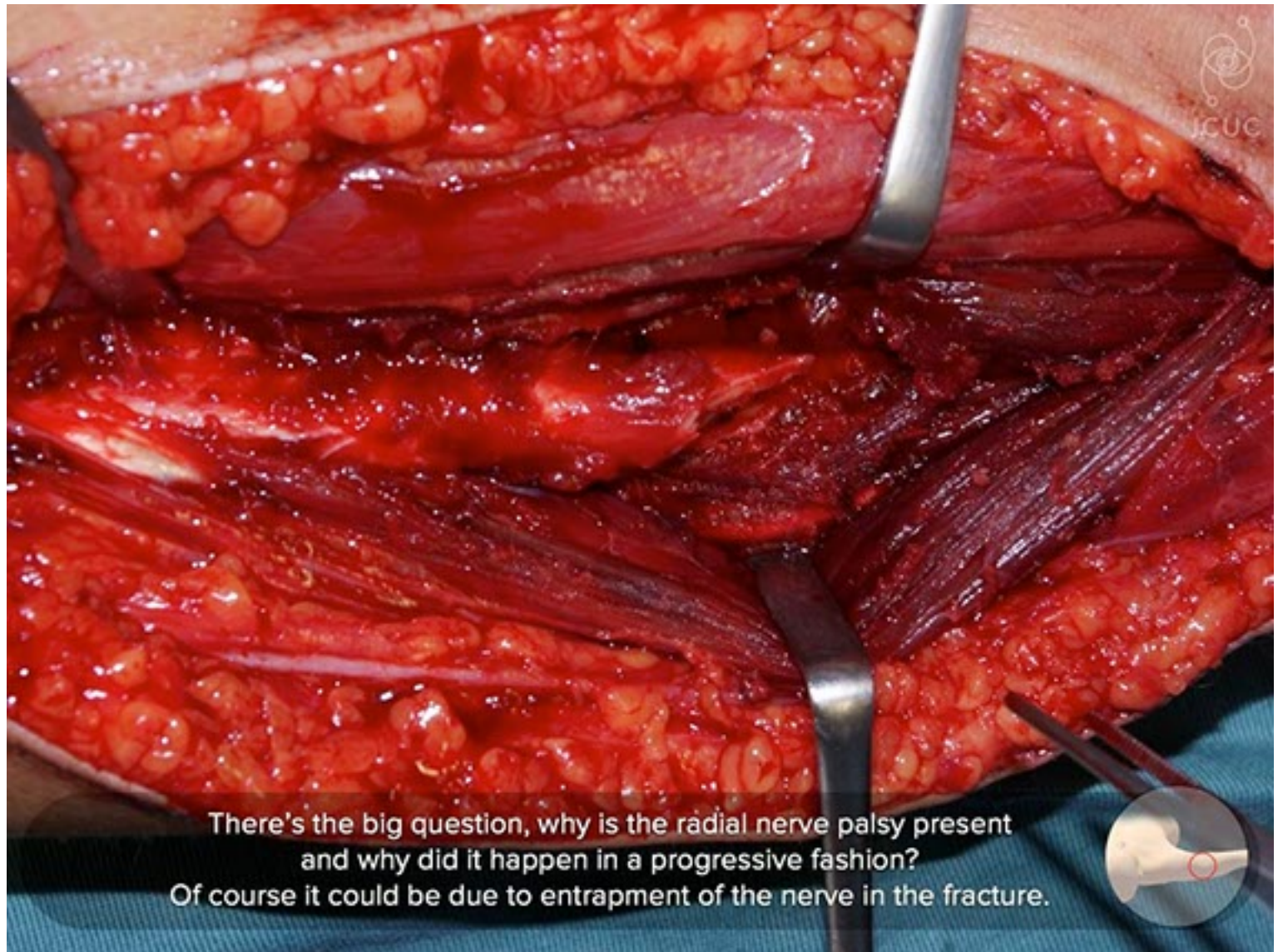
The radial nerve understood distally...

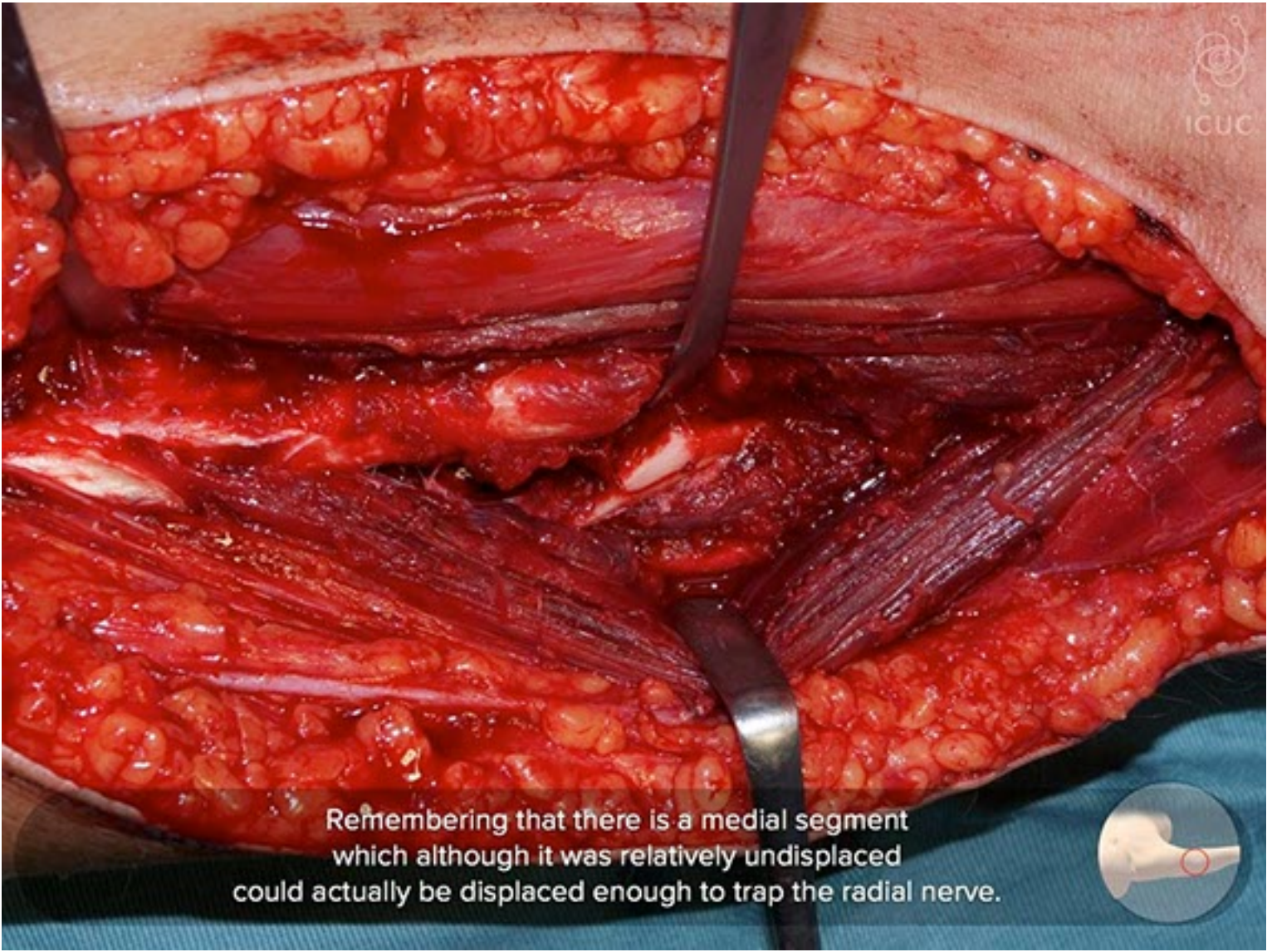


...and the entire fracture now exposed.

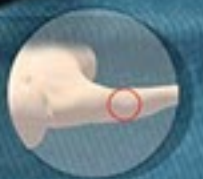




There's the big question, why is the radial nerve palsy present and why did it happen in a progressive fashion? Of course it could be due to entrapment of the nerve in the fracture.



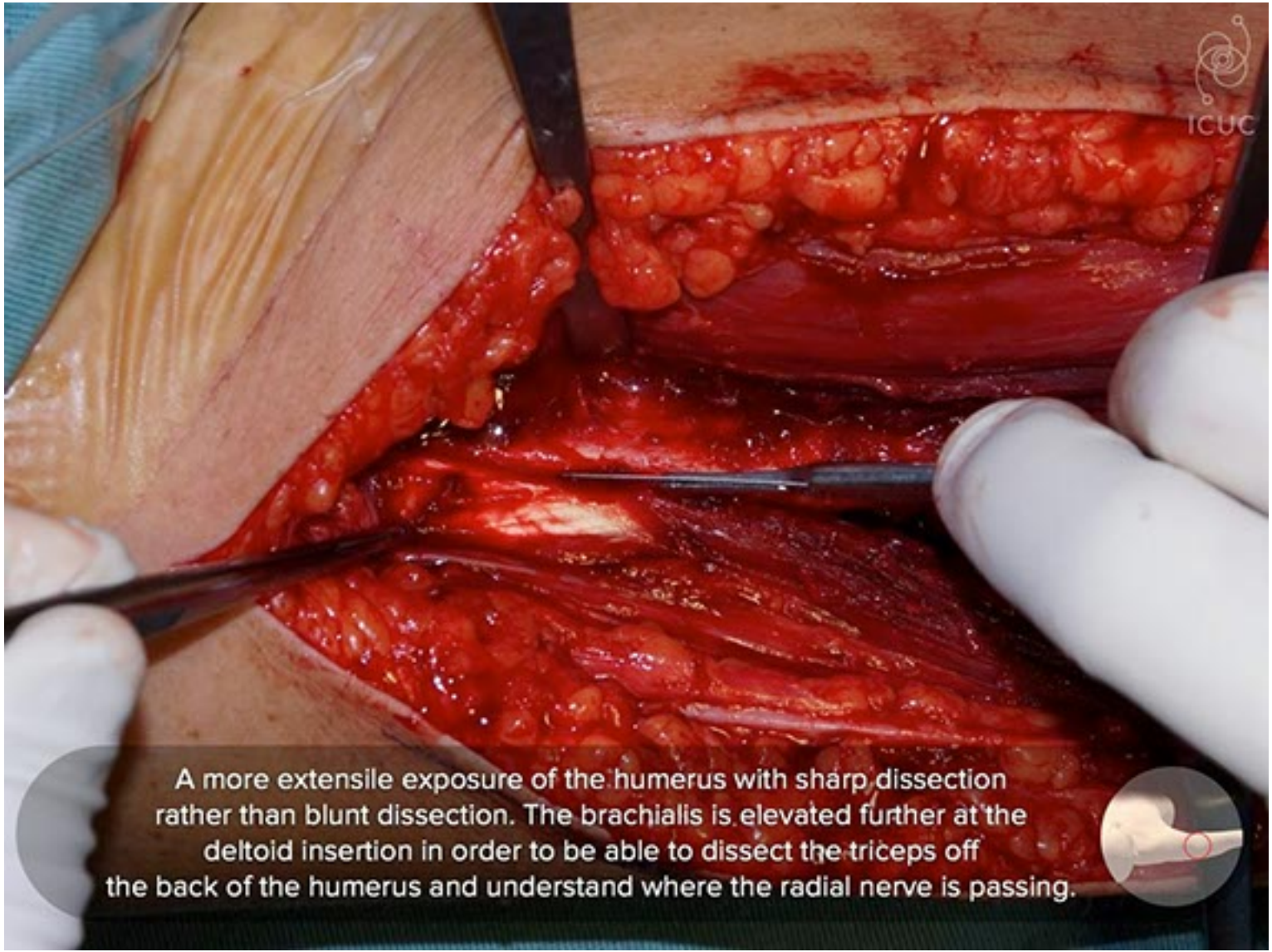
Remembering that there is a medial segment
which although it was relatively undisplaced
could actually be displaced enough to trap the radial nerve.



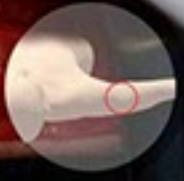

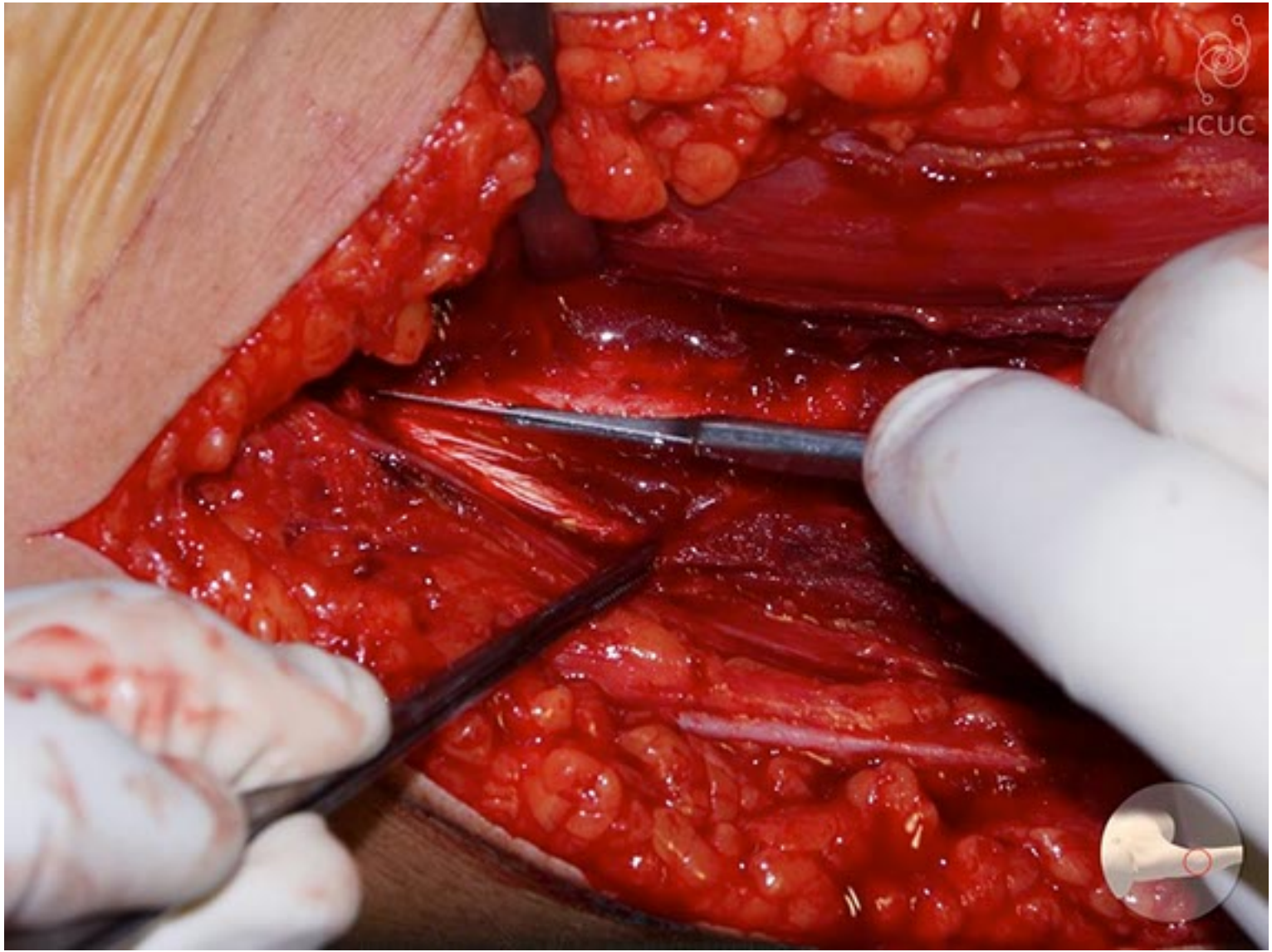
Now the next segment of the dissection is all about understanding the radial nerve in relation to the fracture.

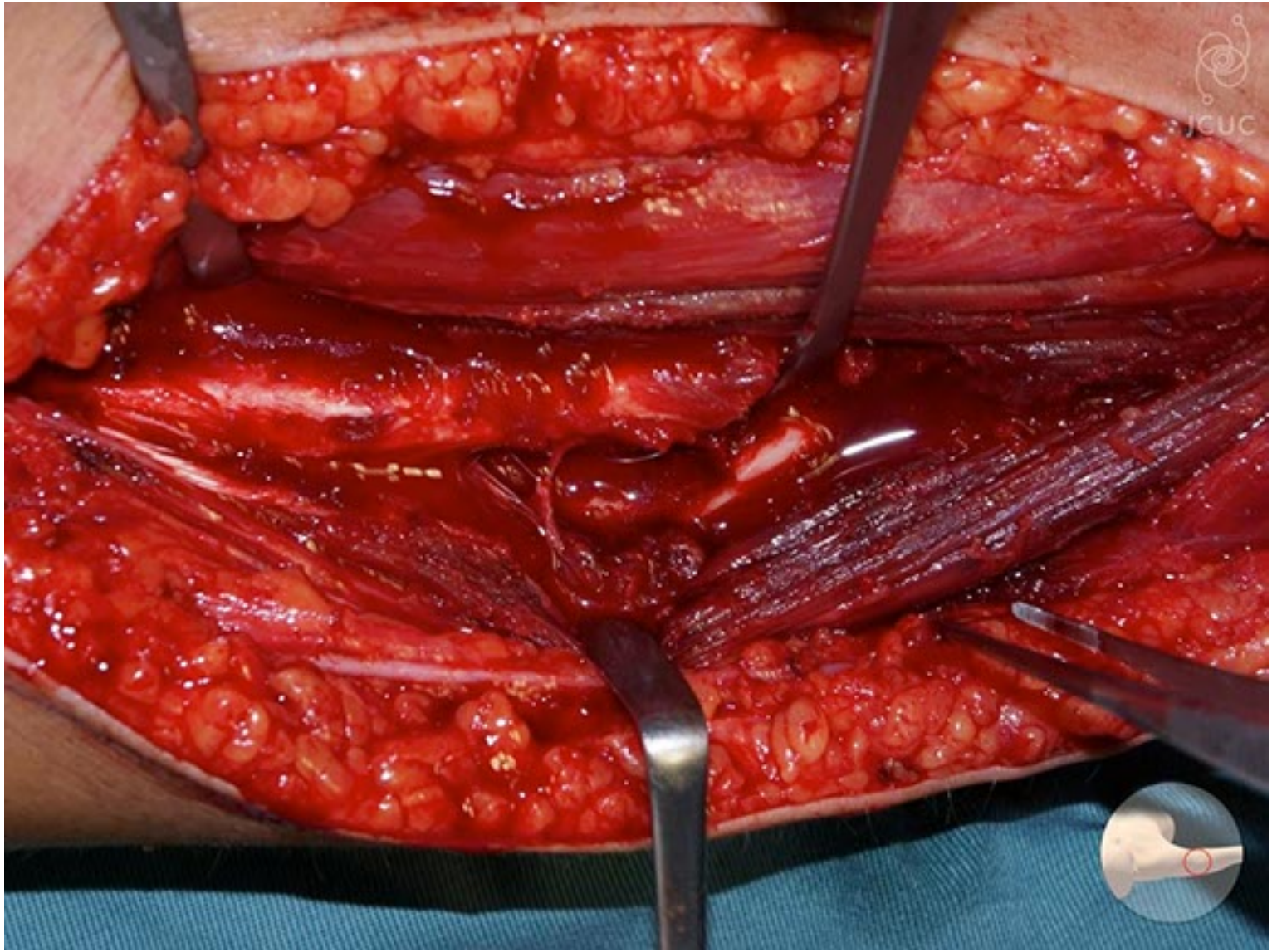




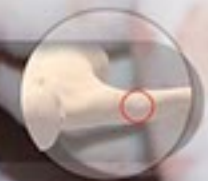A more extensive exposure of the humerus with sharp dissection rather than blunt dissection. The brachialis is elevated further at the deltoid insertion in order to be able to dissect the triceps off the back of the humerus and understand where the radial nerve is passing.

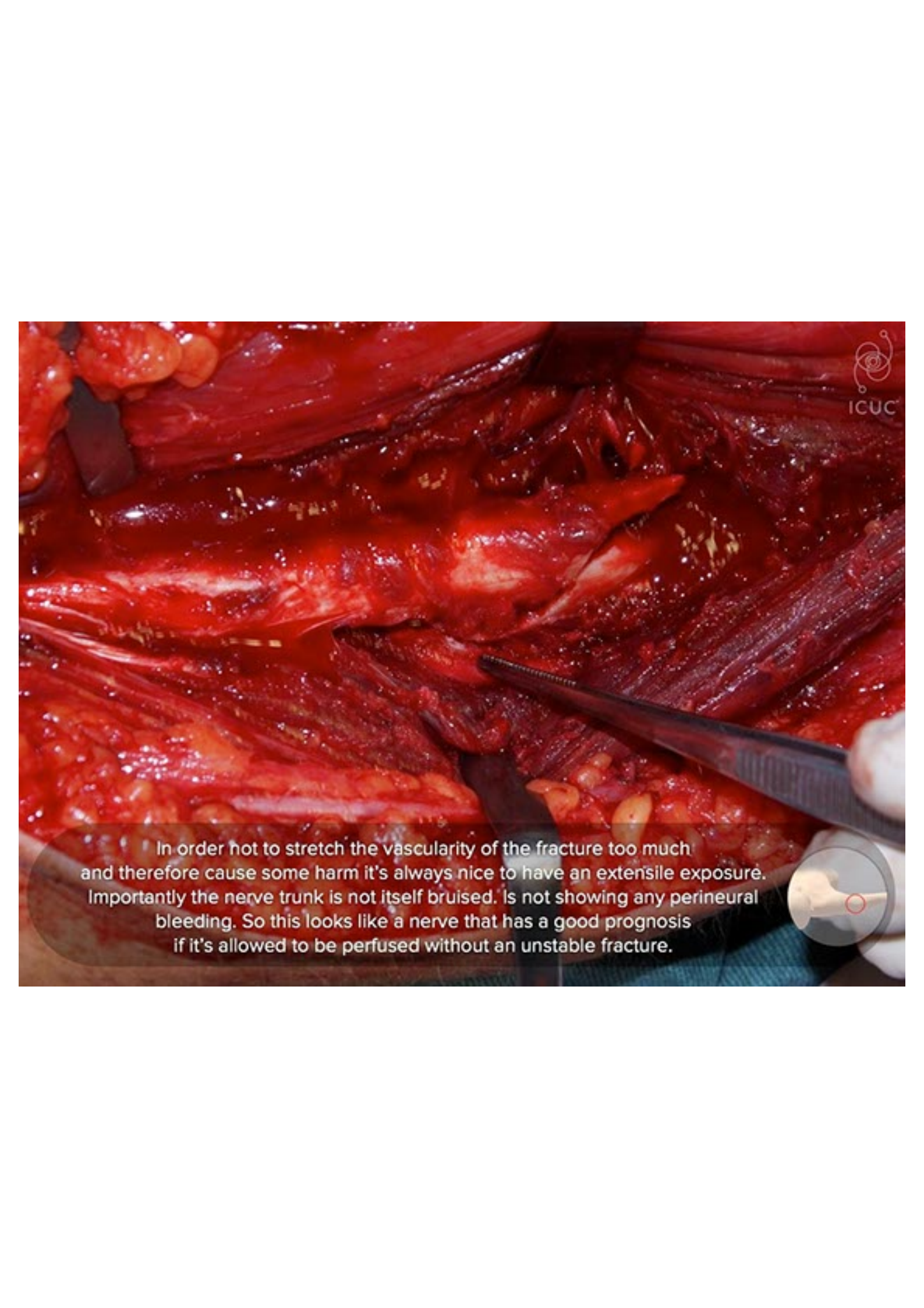






Clear evidence of the nerve slightly swollen and very close to the apex of the distal humerus segment which is probably the culprit.

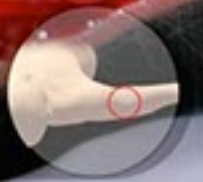


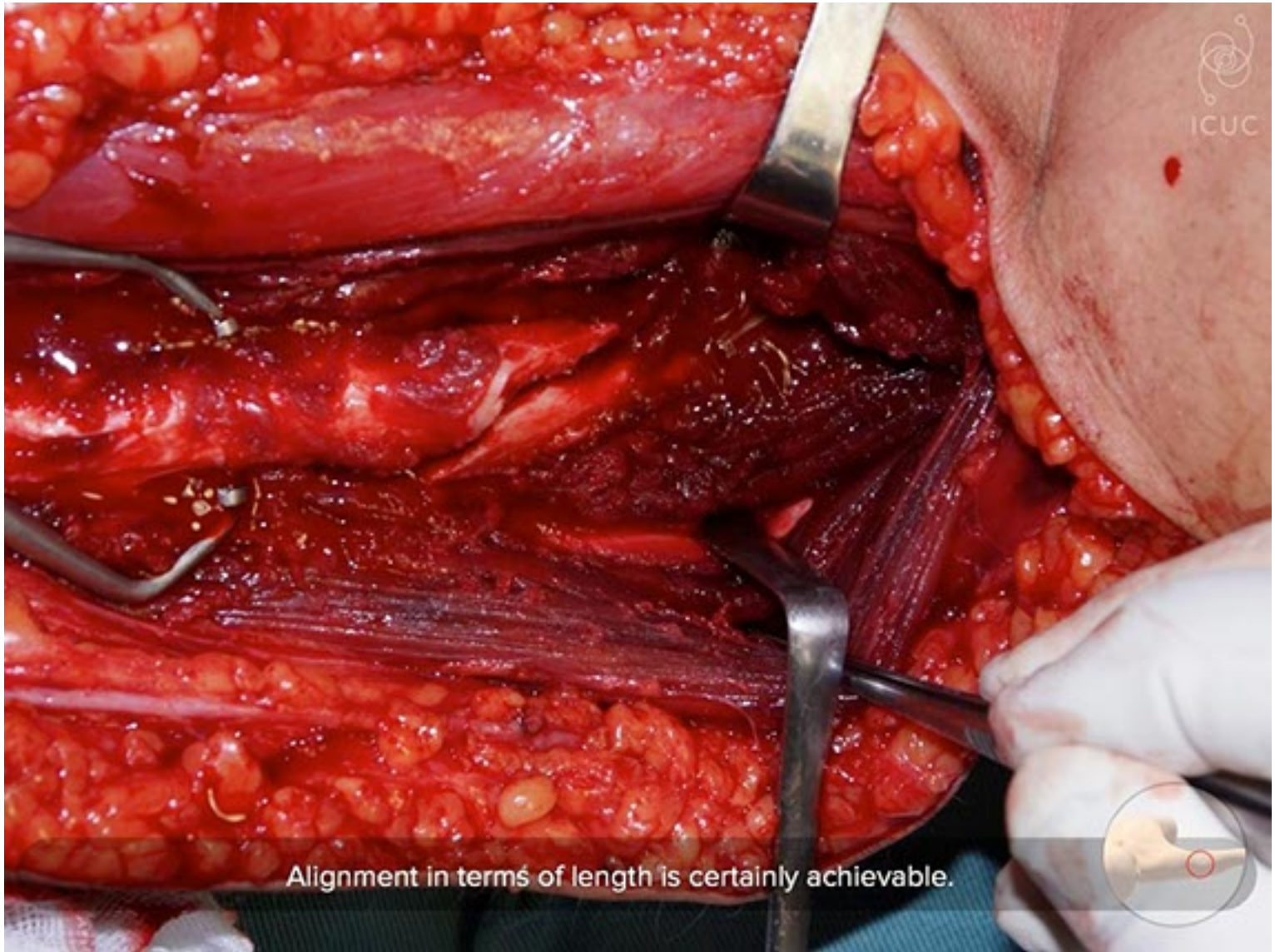
In order not to stretch the vascularity of the fracture too much and therefore cause some harm it's always nice to have an extensile exposure. Importantly the nerve trunk is not itself bruised. Is not showing any perineural bleeding. So this looks like a nerve that has a good prognosis if it's allowed to be perfused without an unstable fracture.

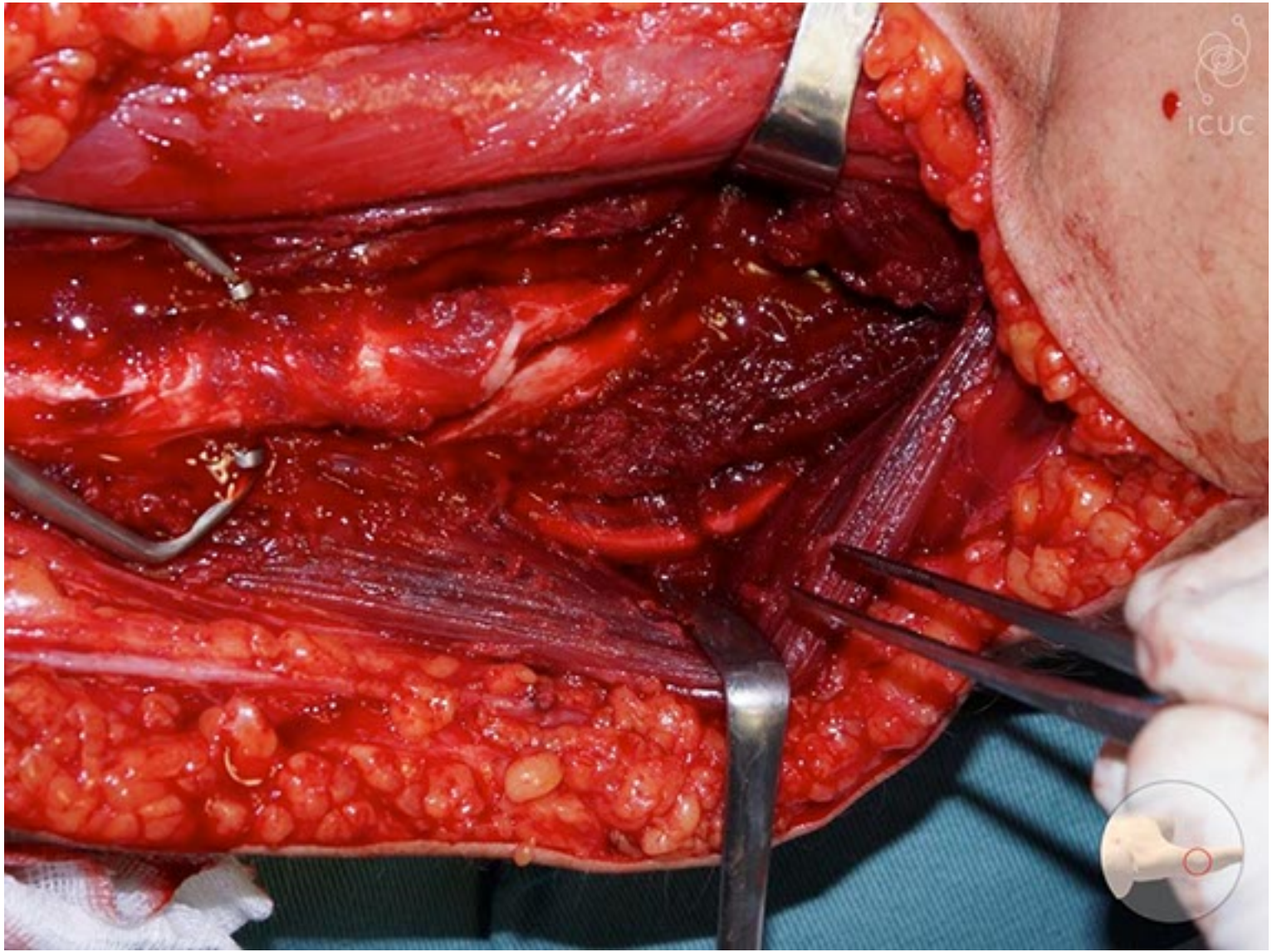


Having discovered the radial nerve and made sure it's safe and mobile from the fracture site, the next sequence is all about how to understand the adaptability of the fracture.

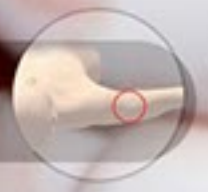


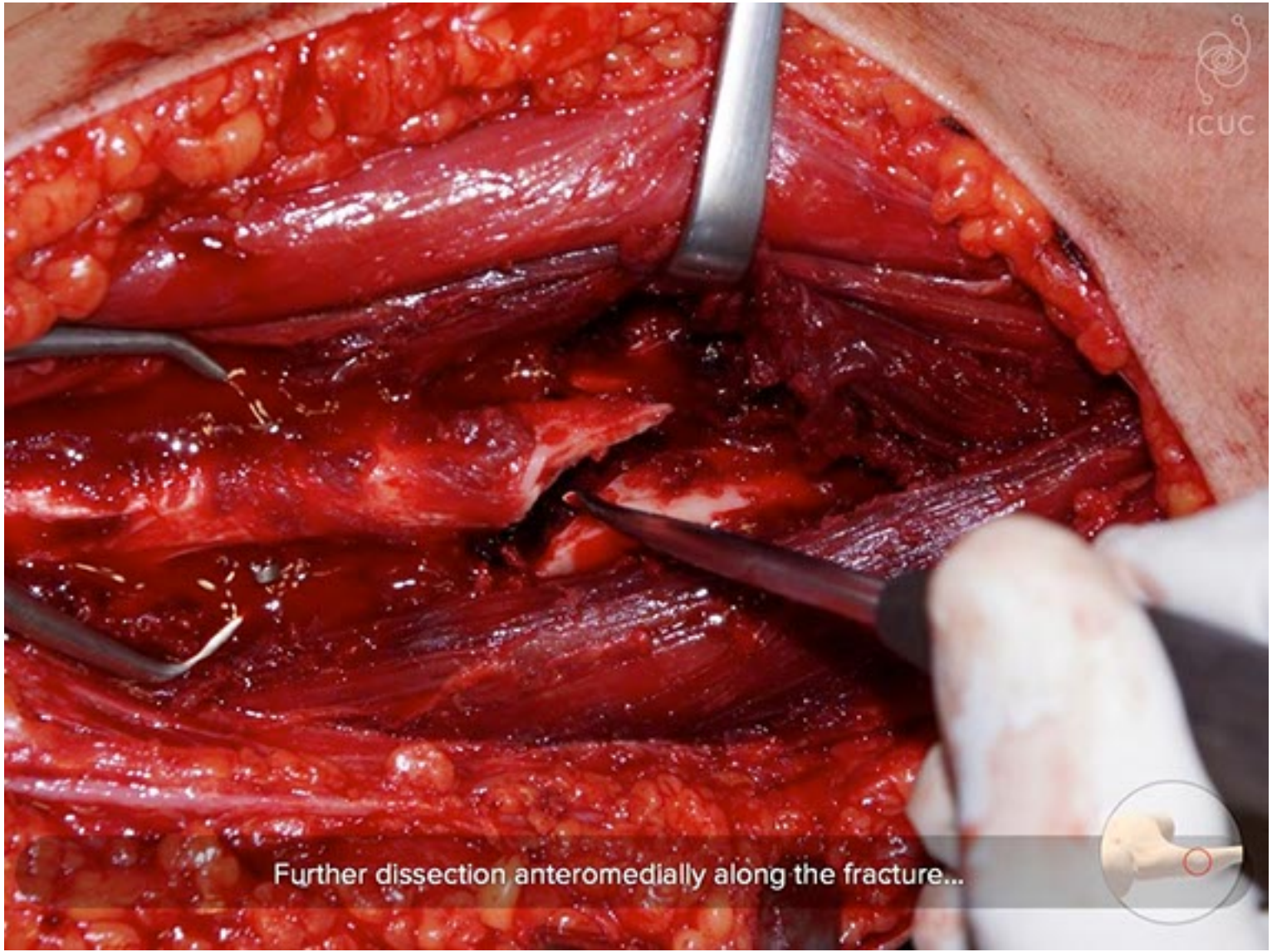
Alignment in terms of length is certainly achievable.

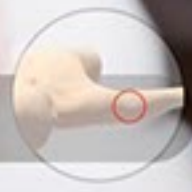

Alignment in terms of rotation becomes apparently rather more difficult.
And always there is a concern about the radial nerve.

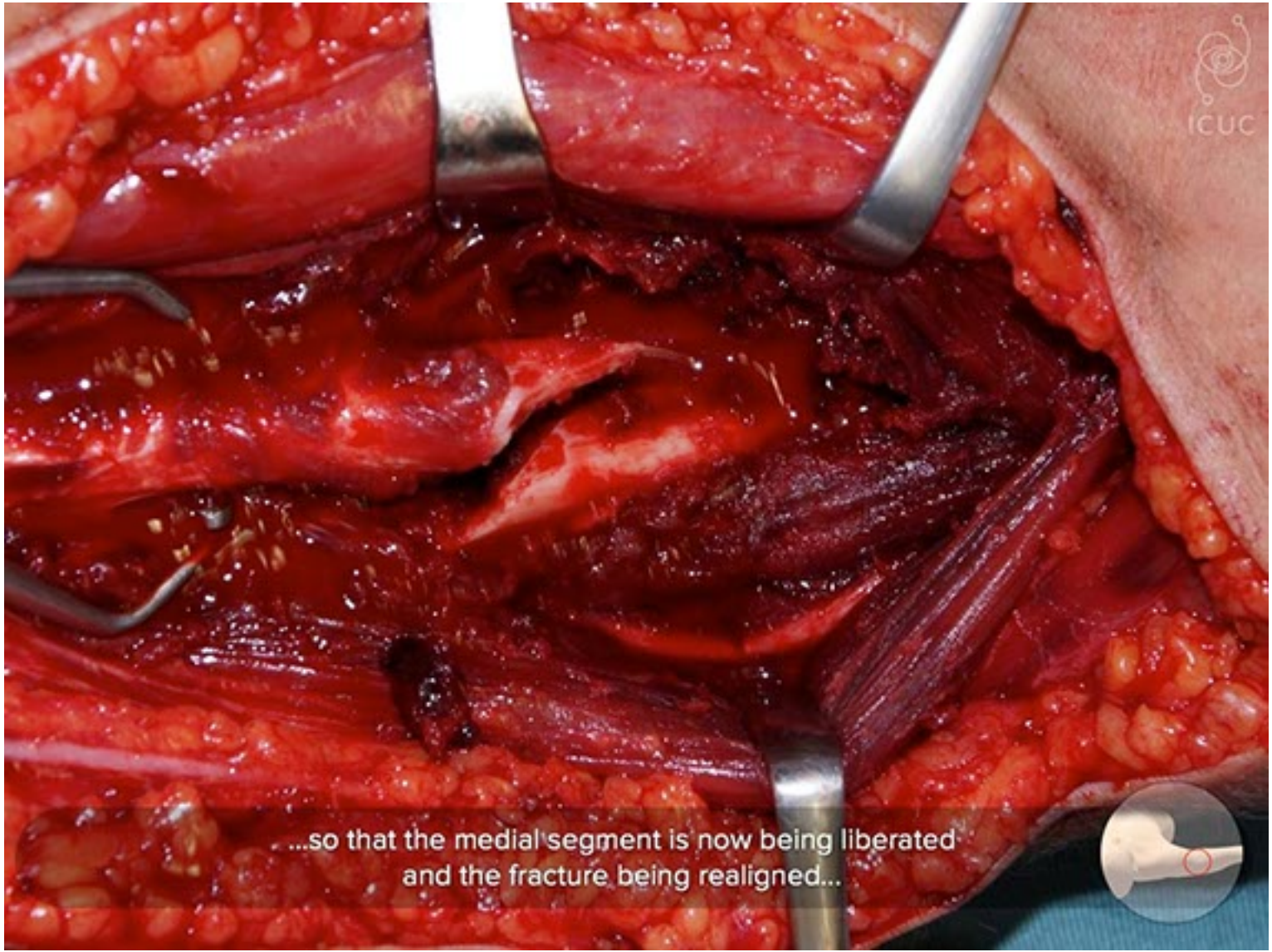
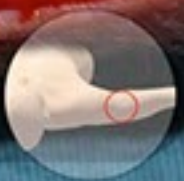



Further dissection anteromedially along the fracture...



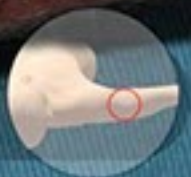...so that the medial segment is now being liberated and the fracture being realigned...

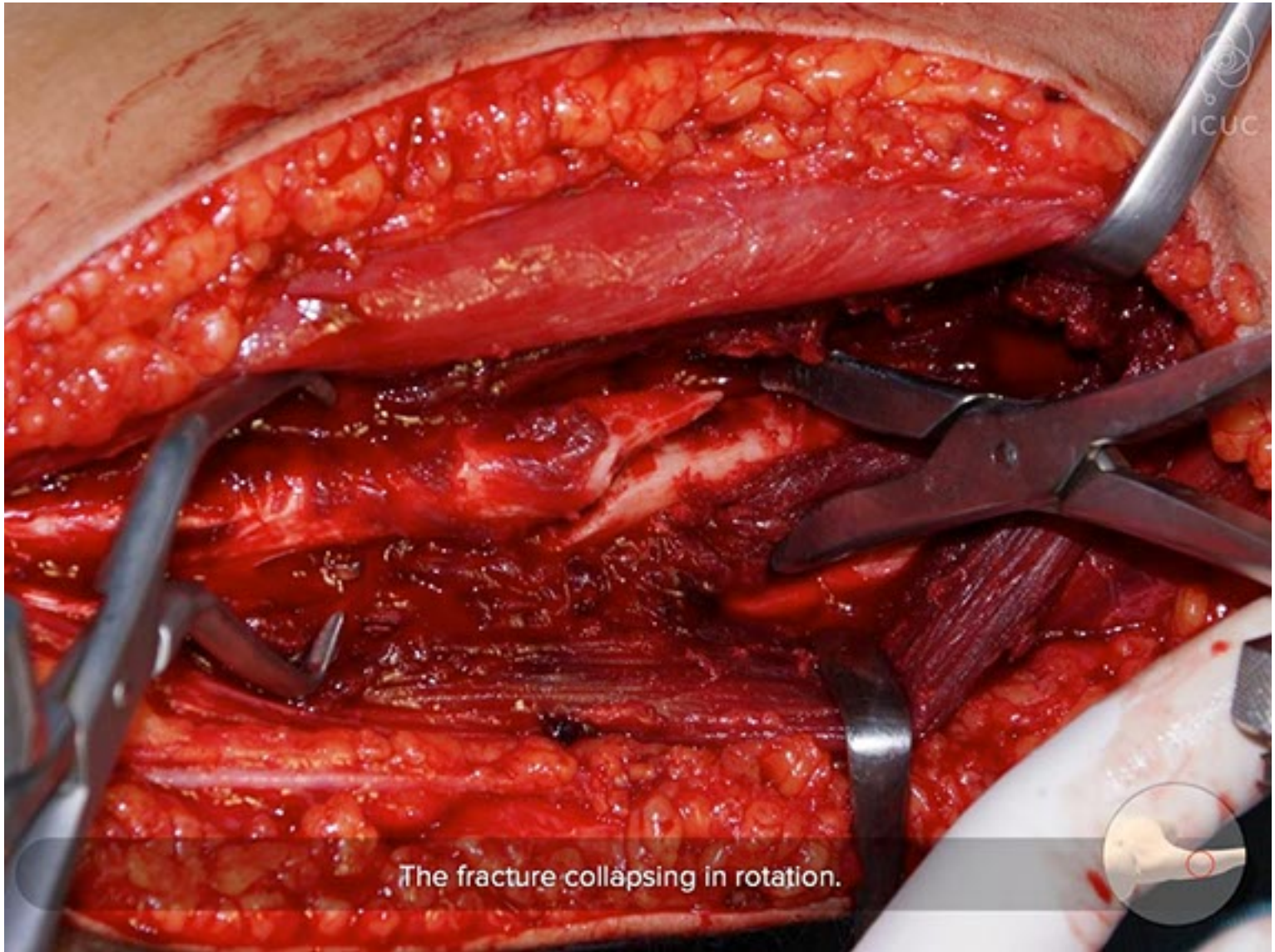



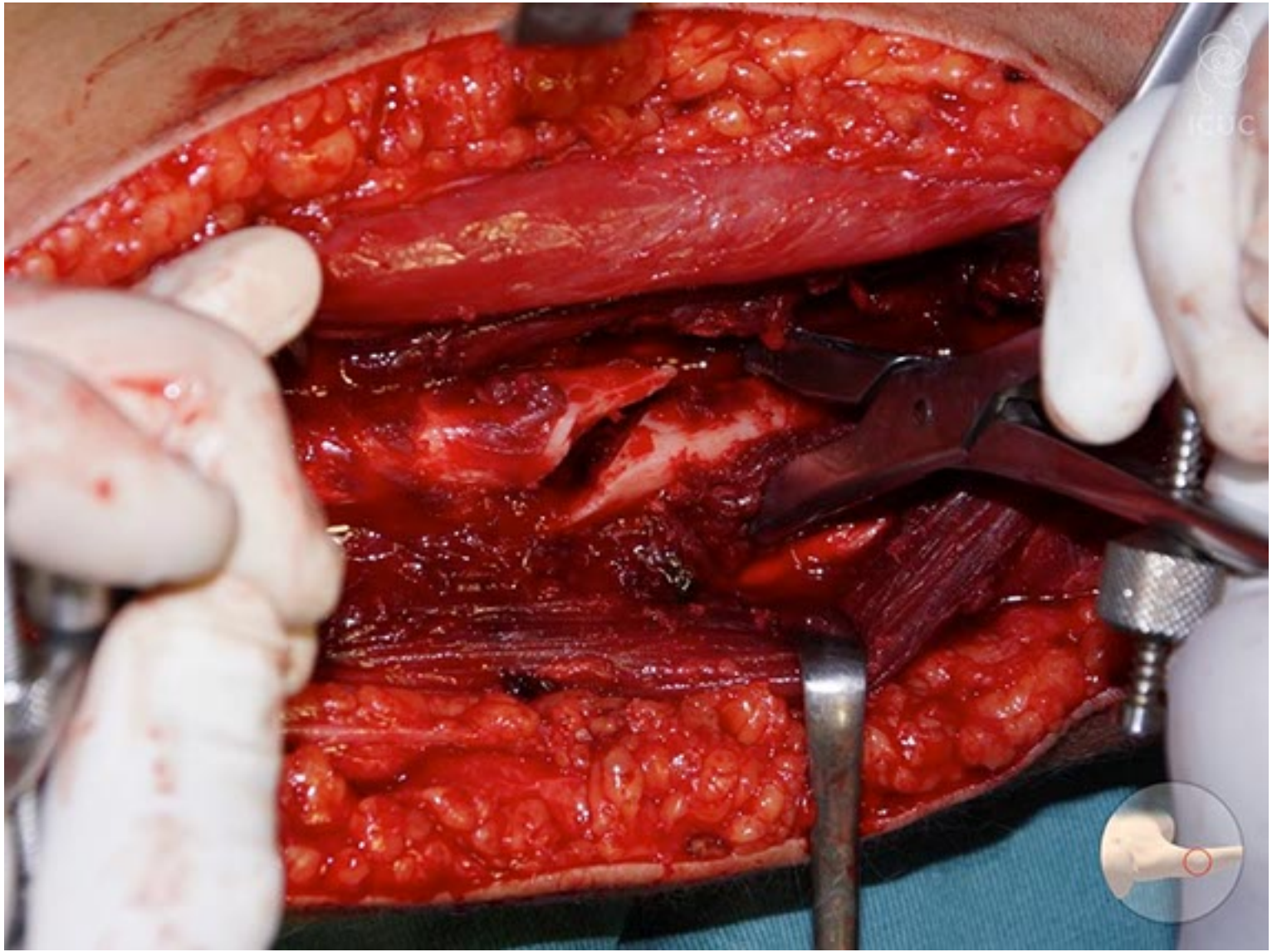
...while making sure the medial segment doesn't block the reduction.

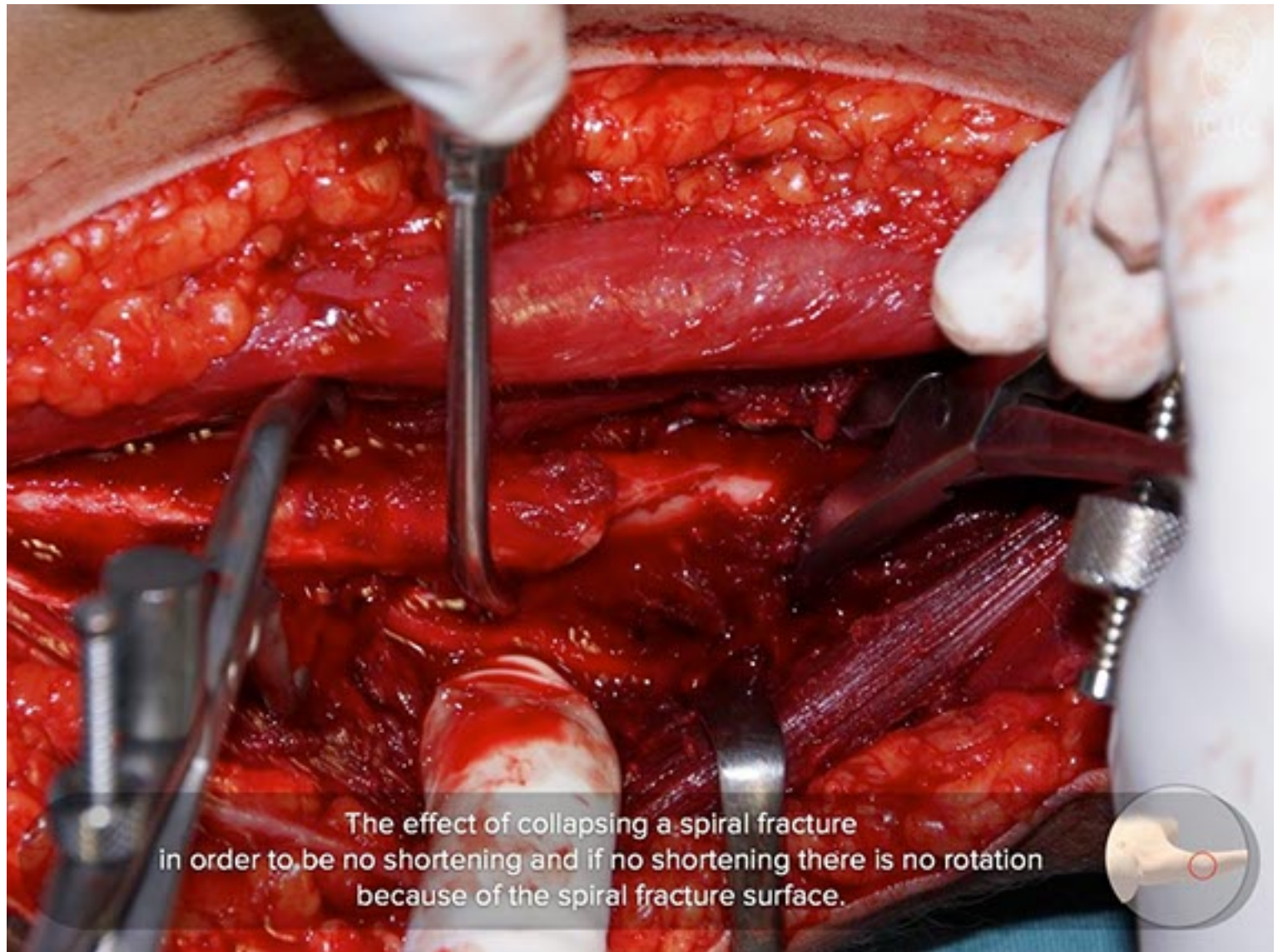Further adaptation demonstrates actually how difficult such a relatively simple looking fracture can be to align* when there is no medial buttress.



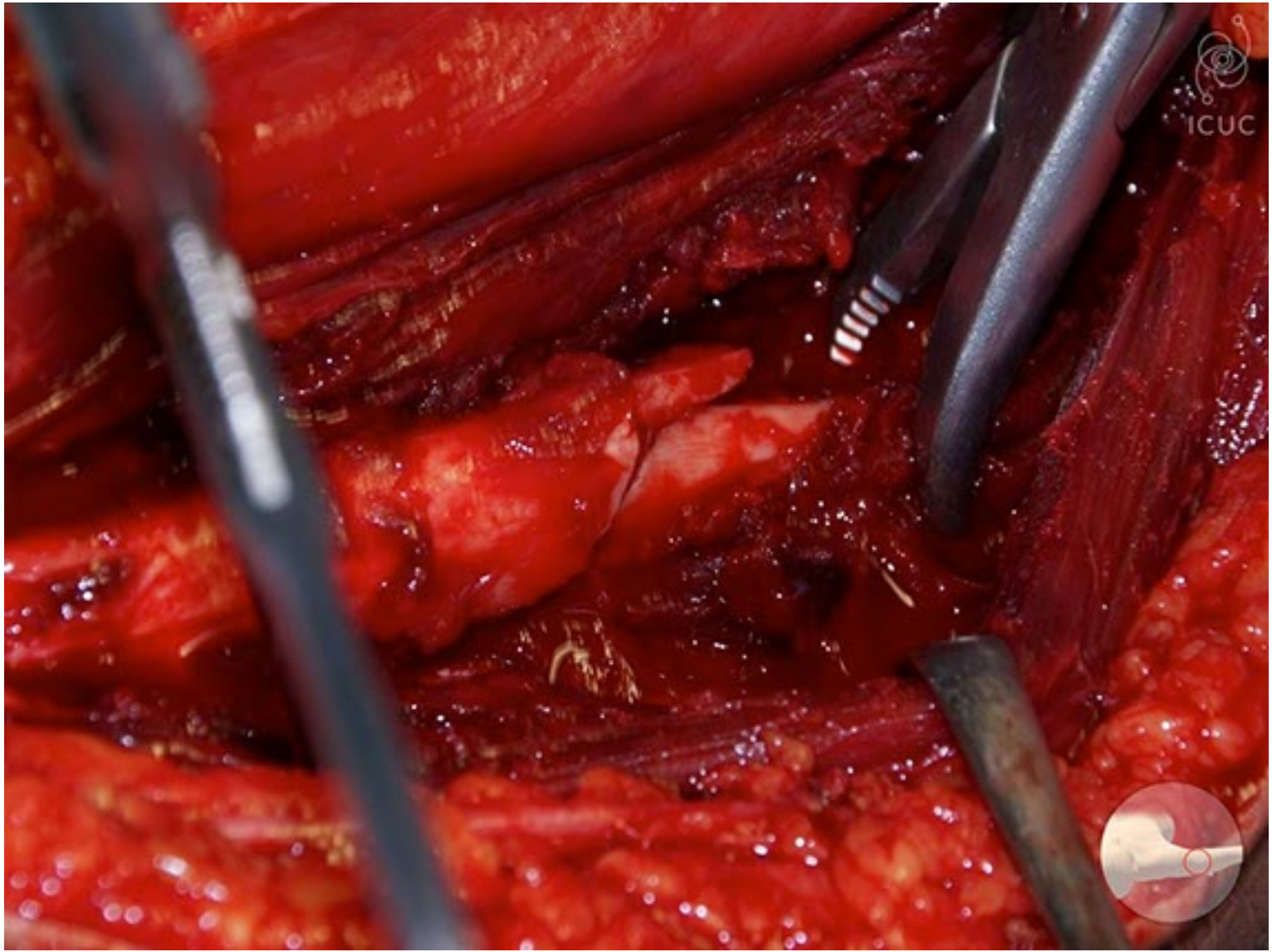


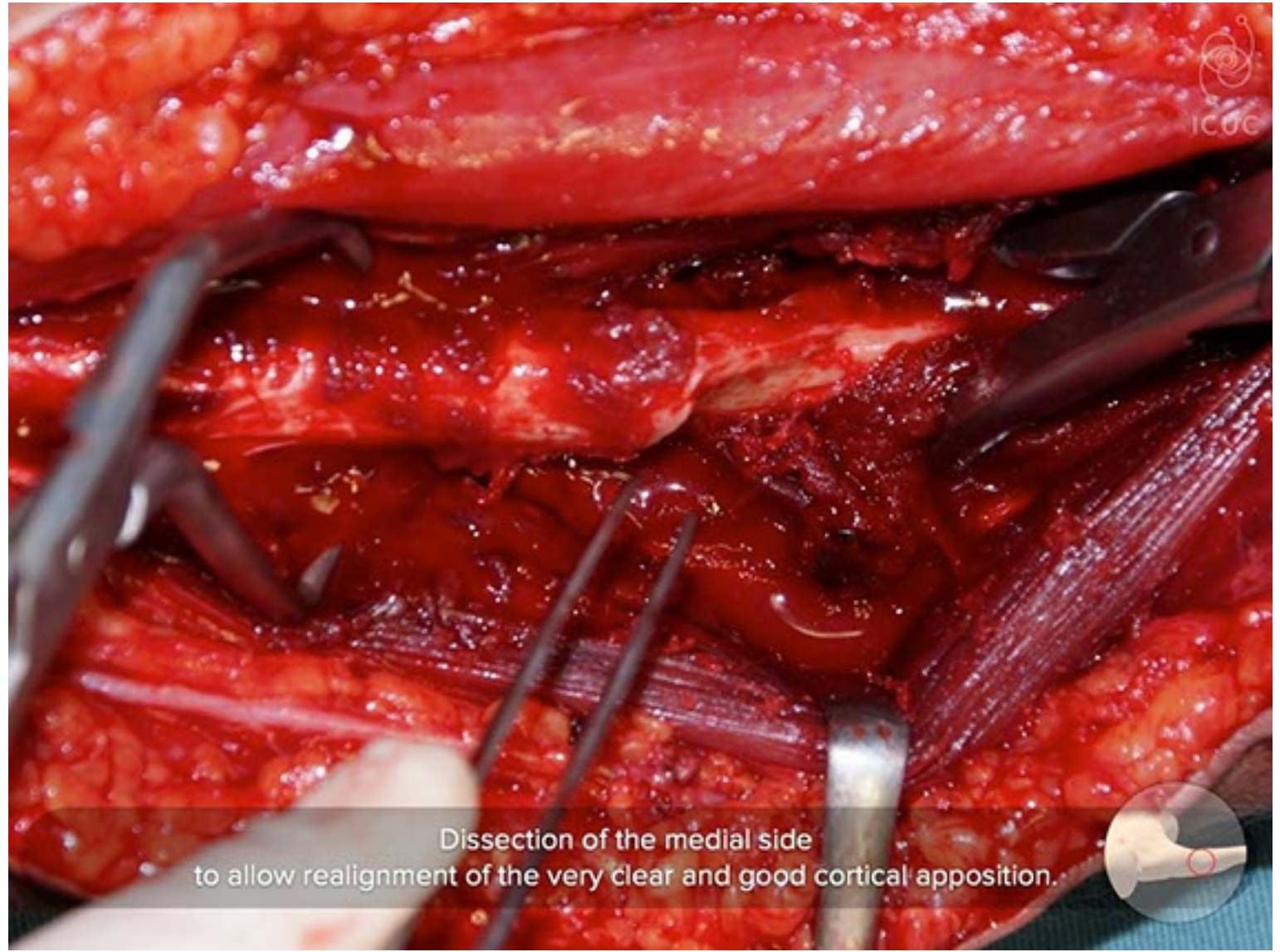
The fracture collapsing in rotation.





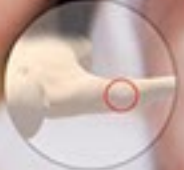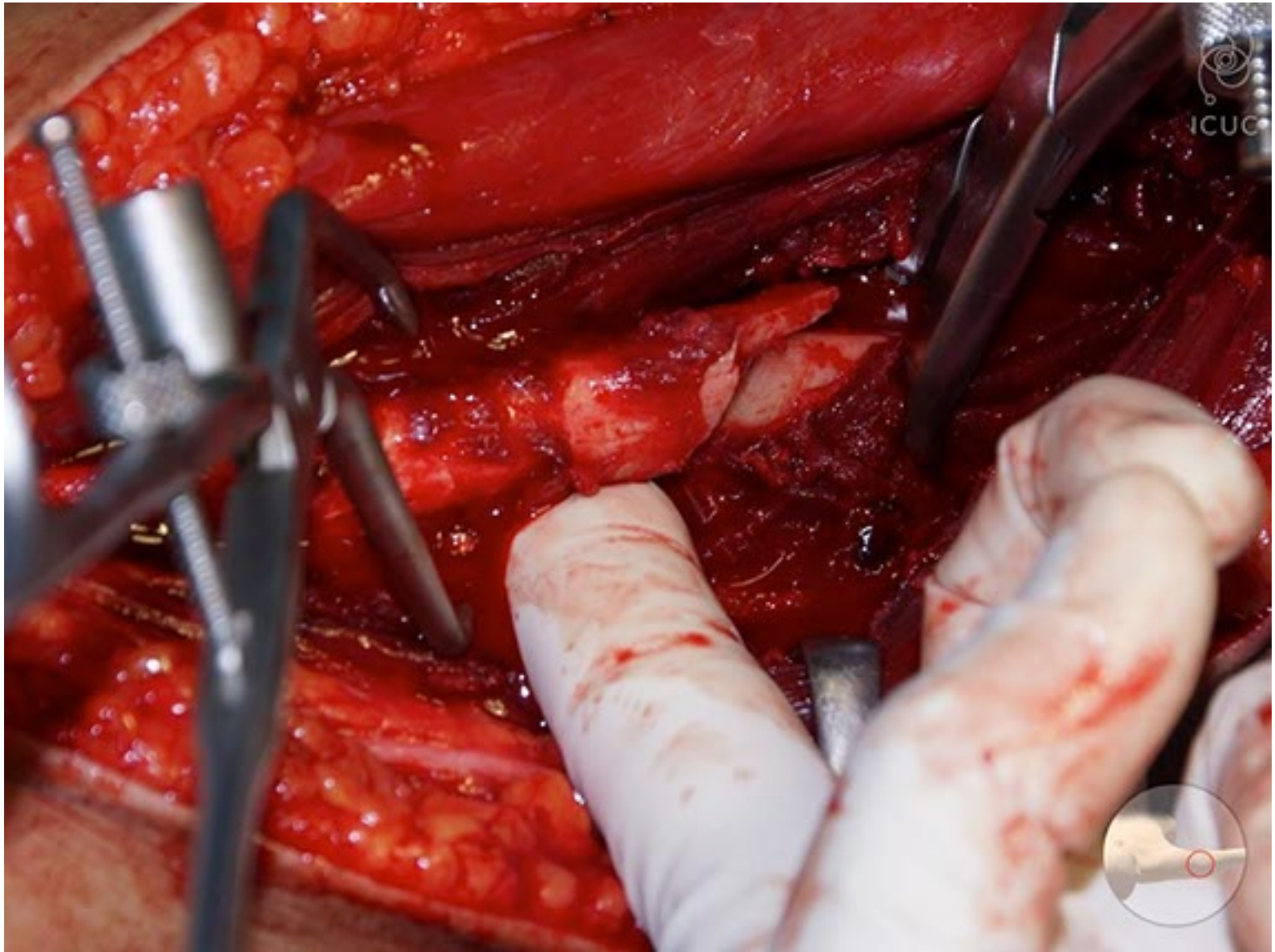
The effect of collapsing a spiral fracture in order to be no shortening and if no shortening there is no rotation because of the spiral fracture surface.

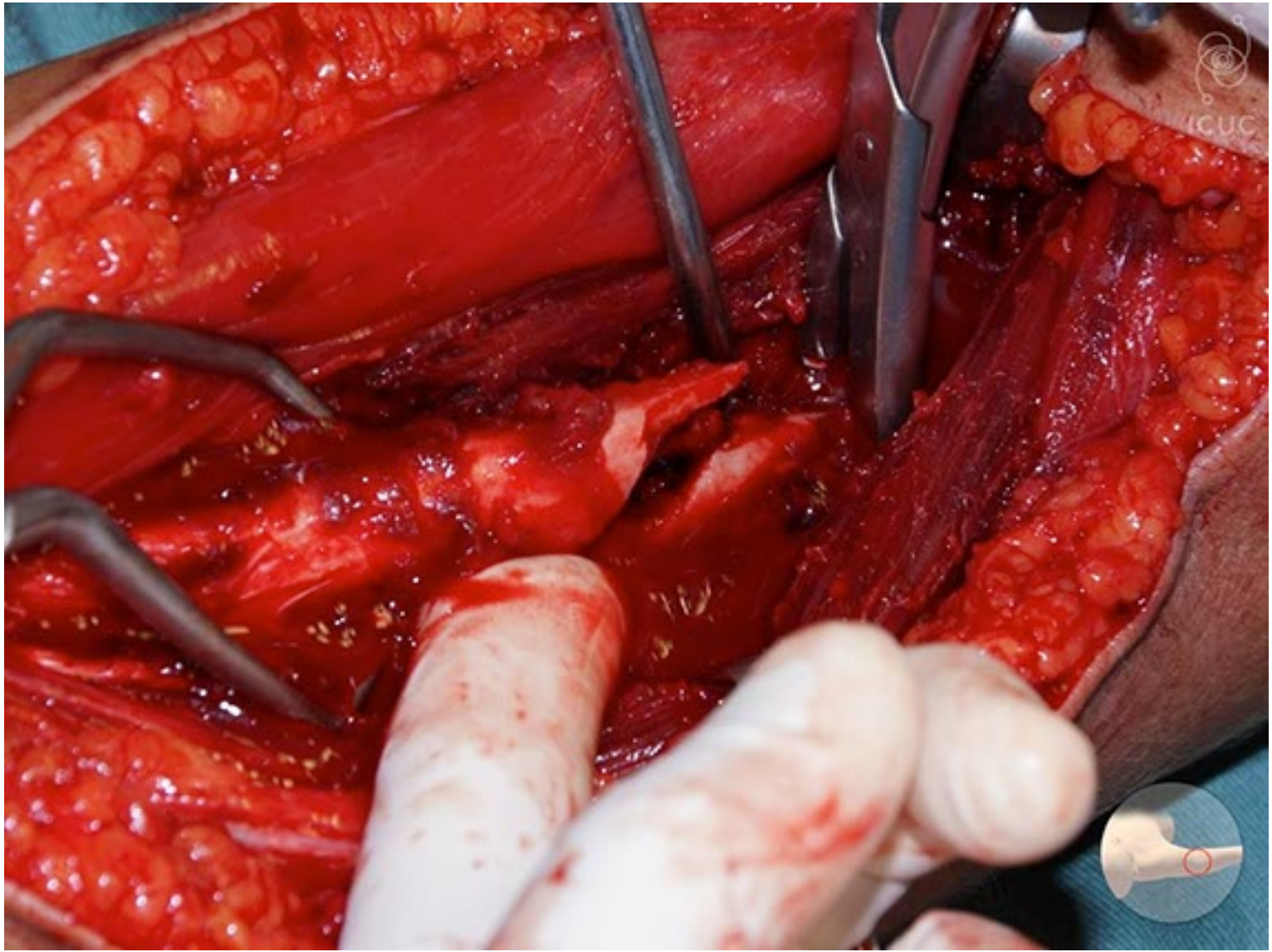


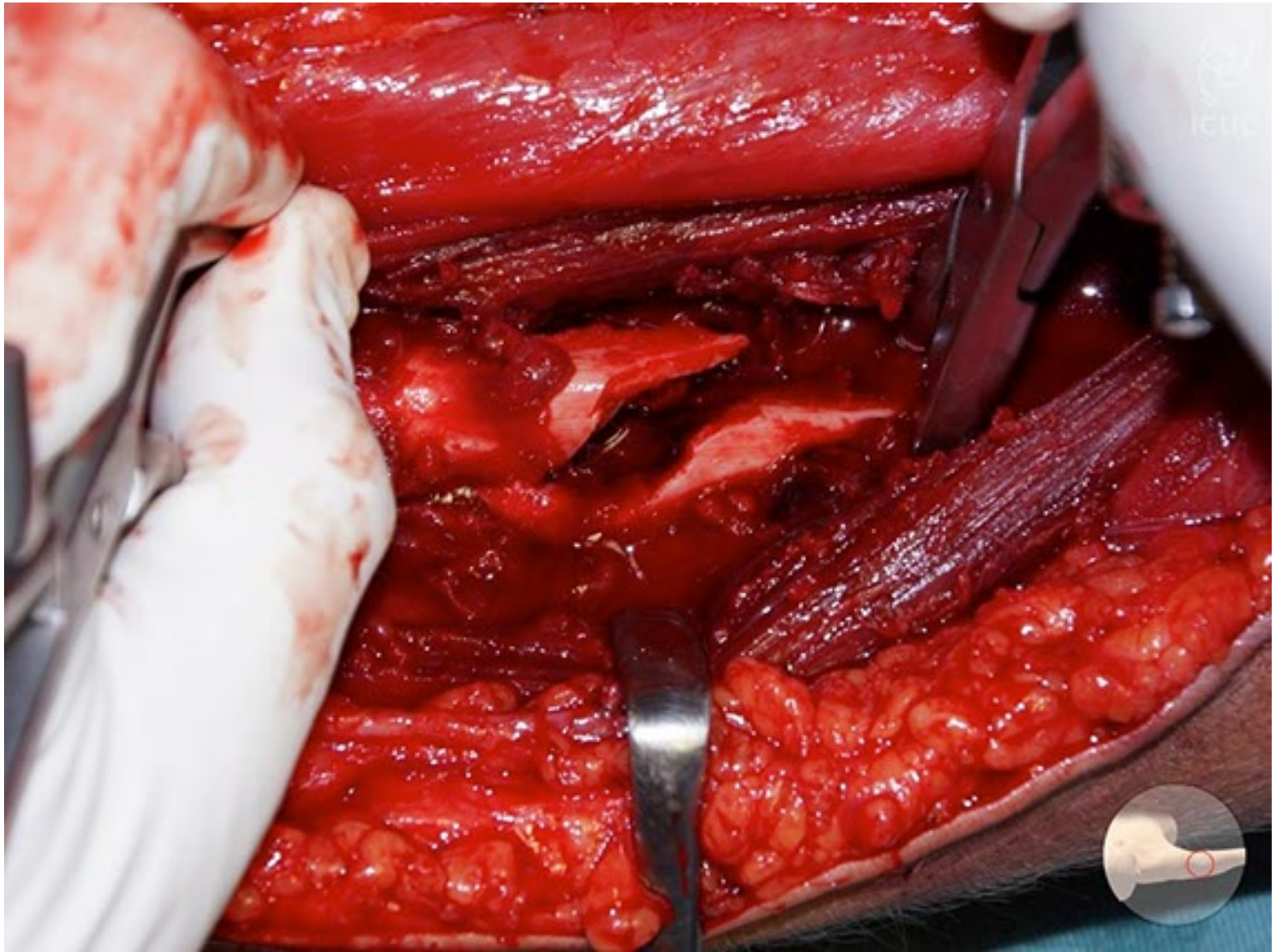

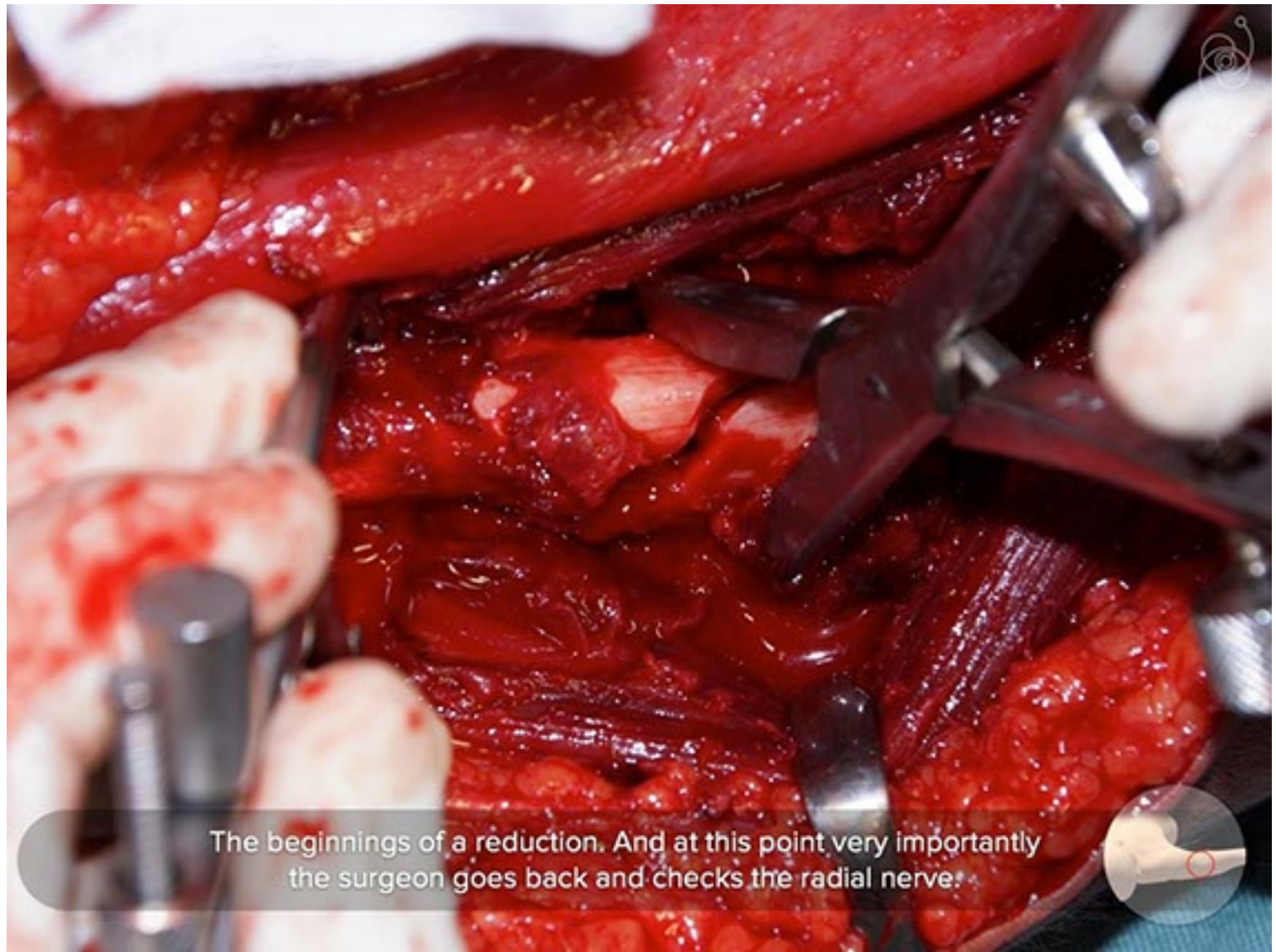
Dissection of the medial side to allow realignment of the very clear and good cortical apposition.





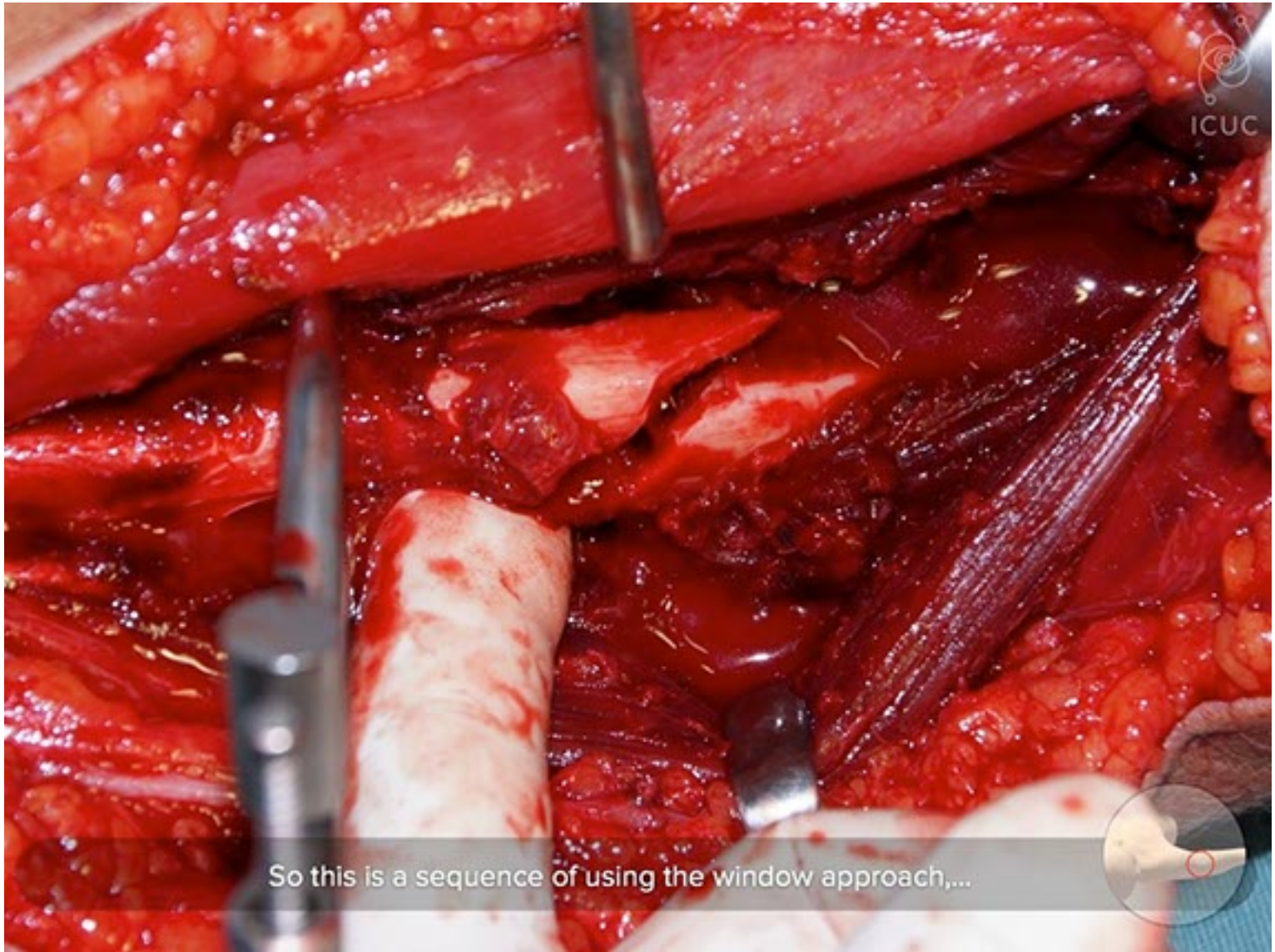




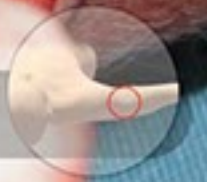

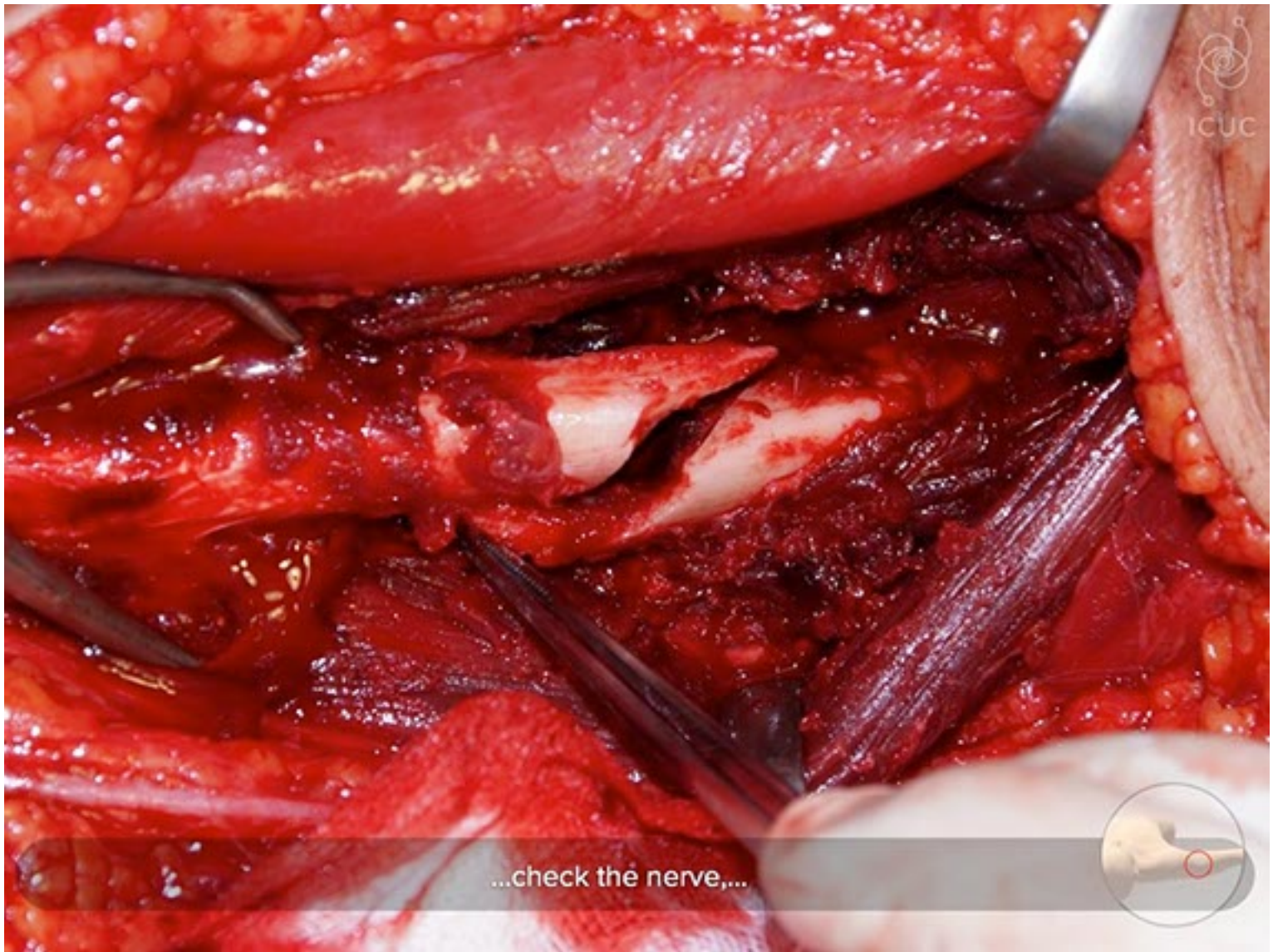
The beginnings of a reduction. And at this point very importantly the surgeon goes back and checks the radial nerve!



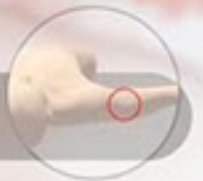

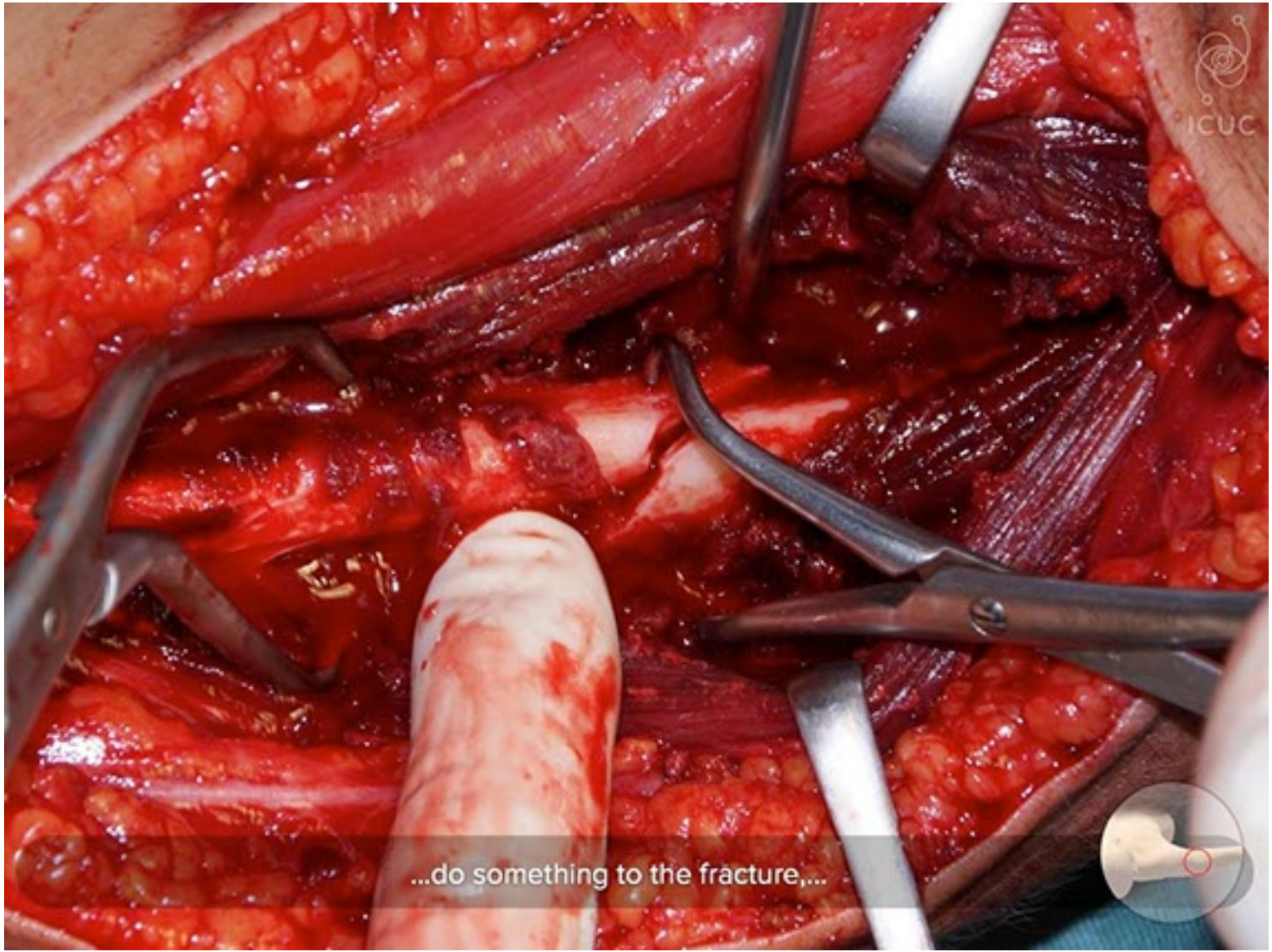So this is a sequence of using the window approach,...



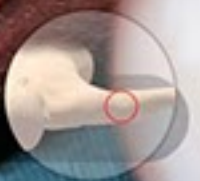

...check the nerve,...





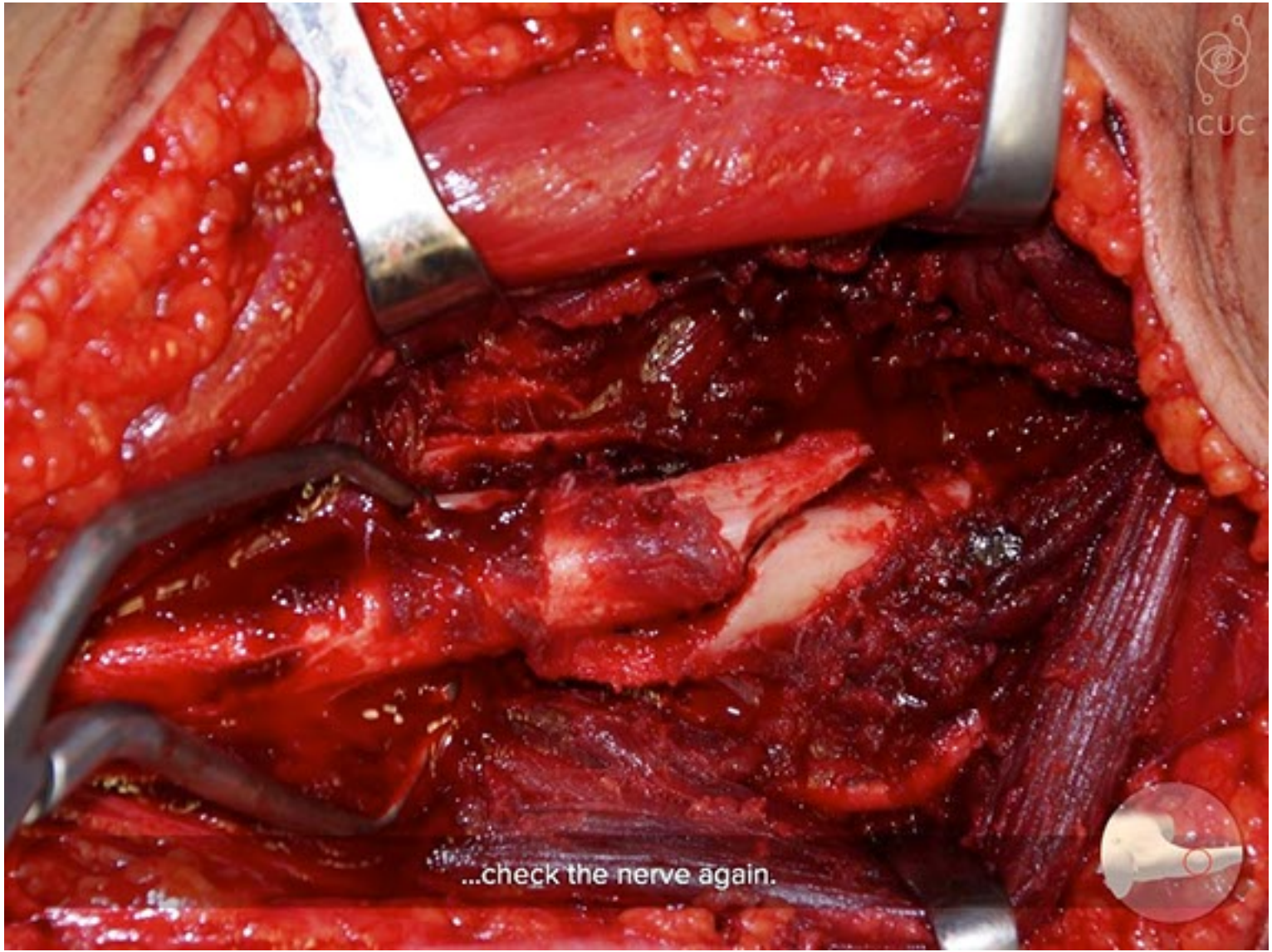...do something to the fracture,...



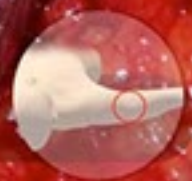

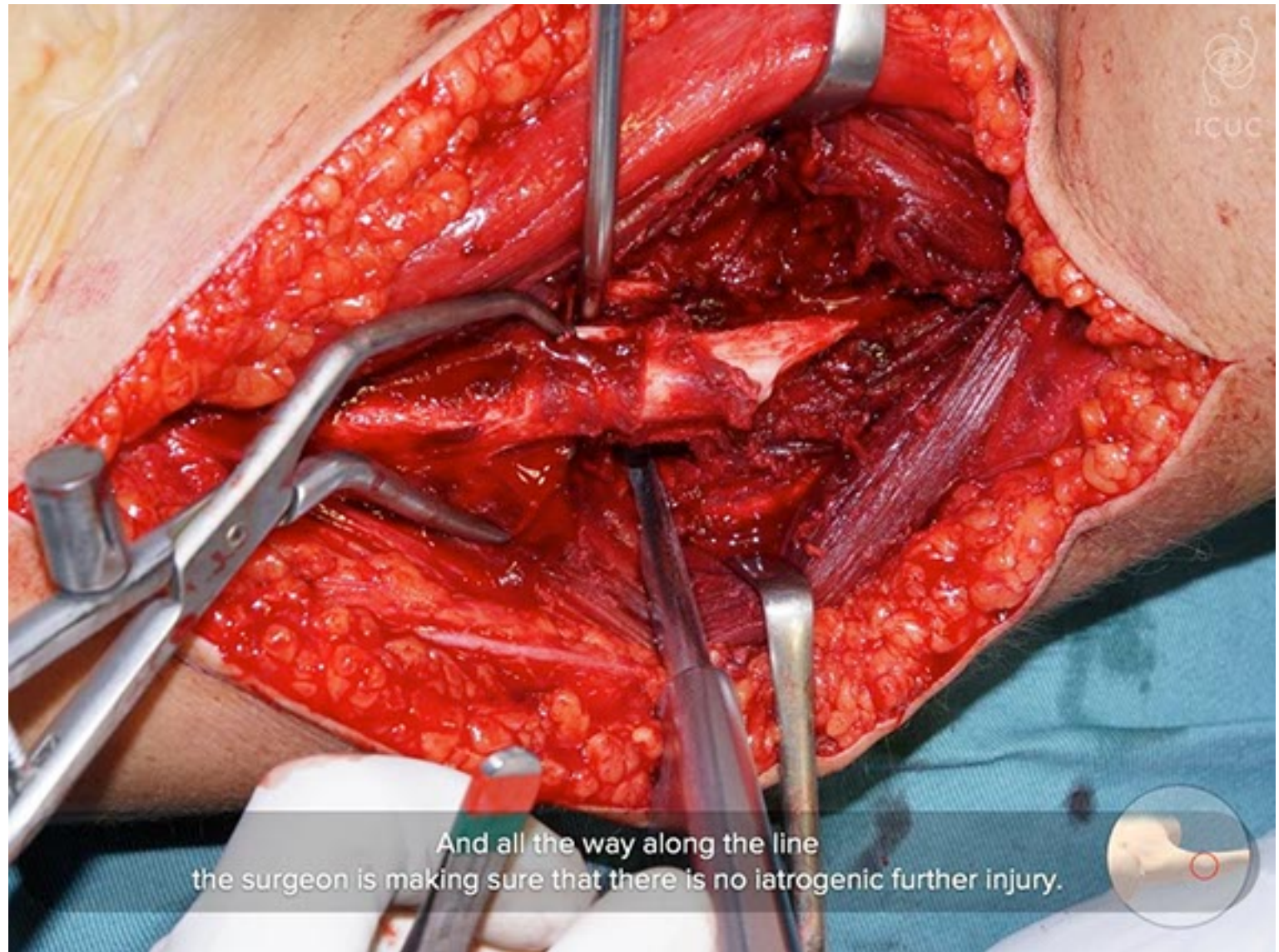
ICUC



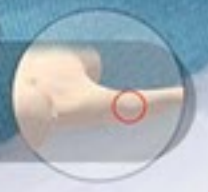

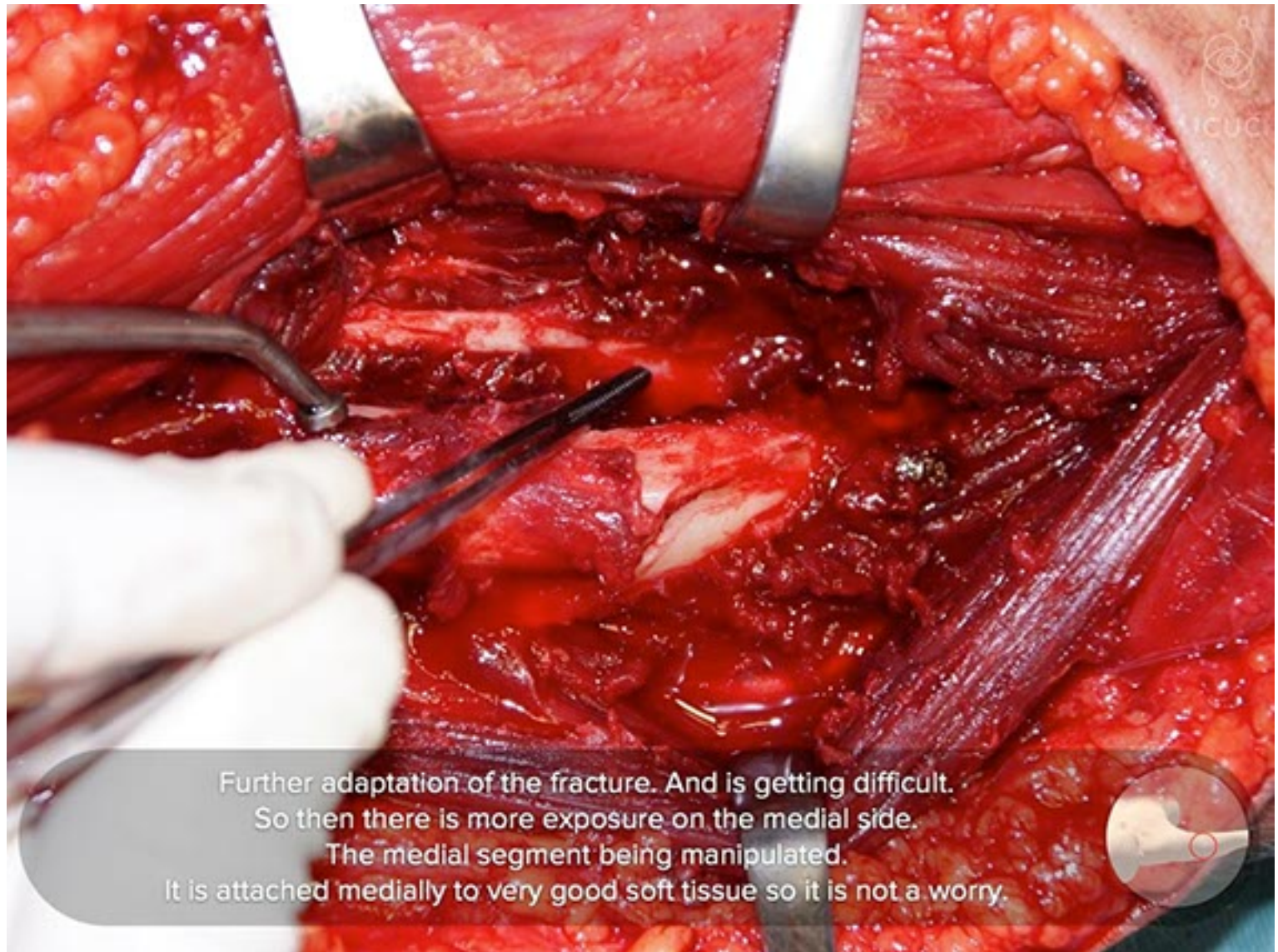...check the nerve again.



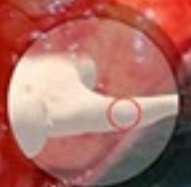

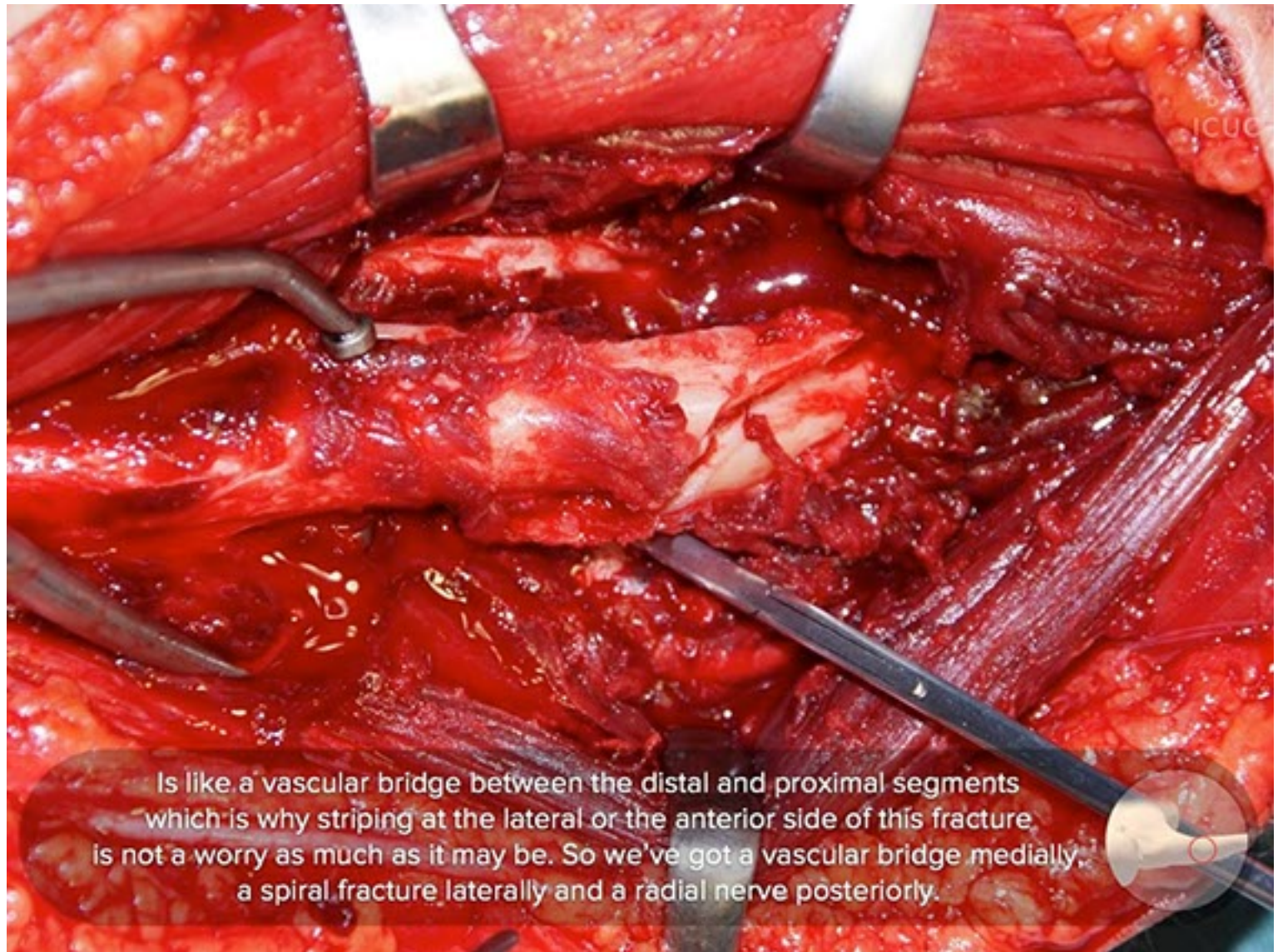
And all the way along the line the surgeon is making sure that there is no iatrogenic further injury.



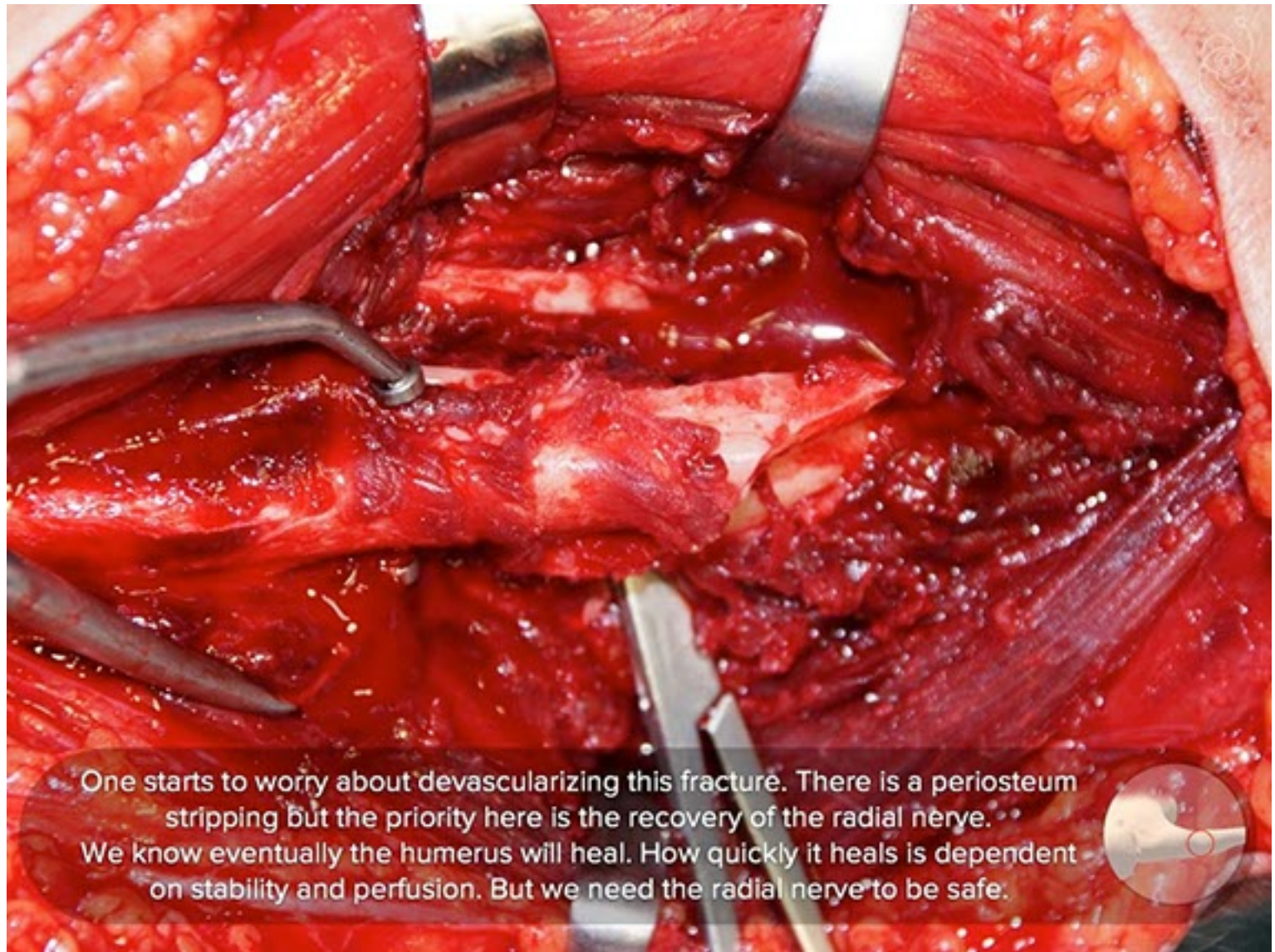


Further adaptation of the fracture. And is getting difficult.
So then there is more exposure on the medial side.
The medial segment being manipulated.
It is attached medially to very good soft tissue so it is not a worry.



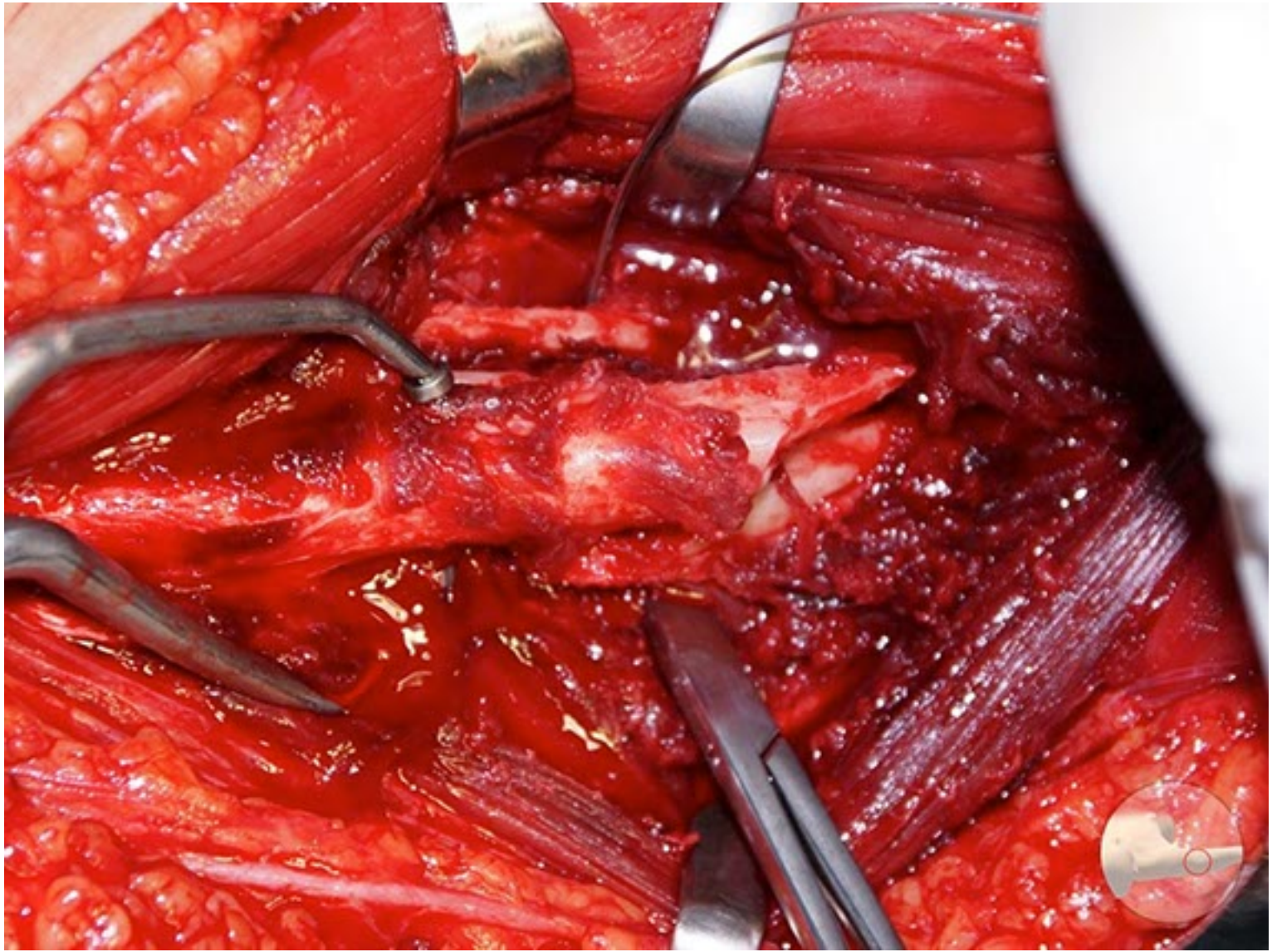

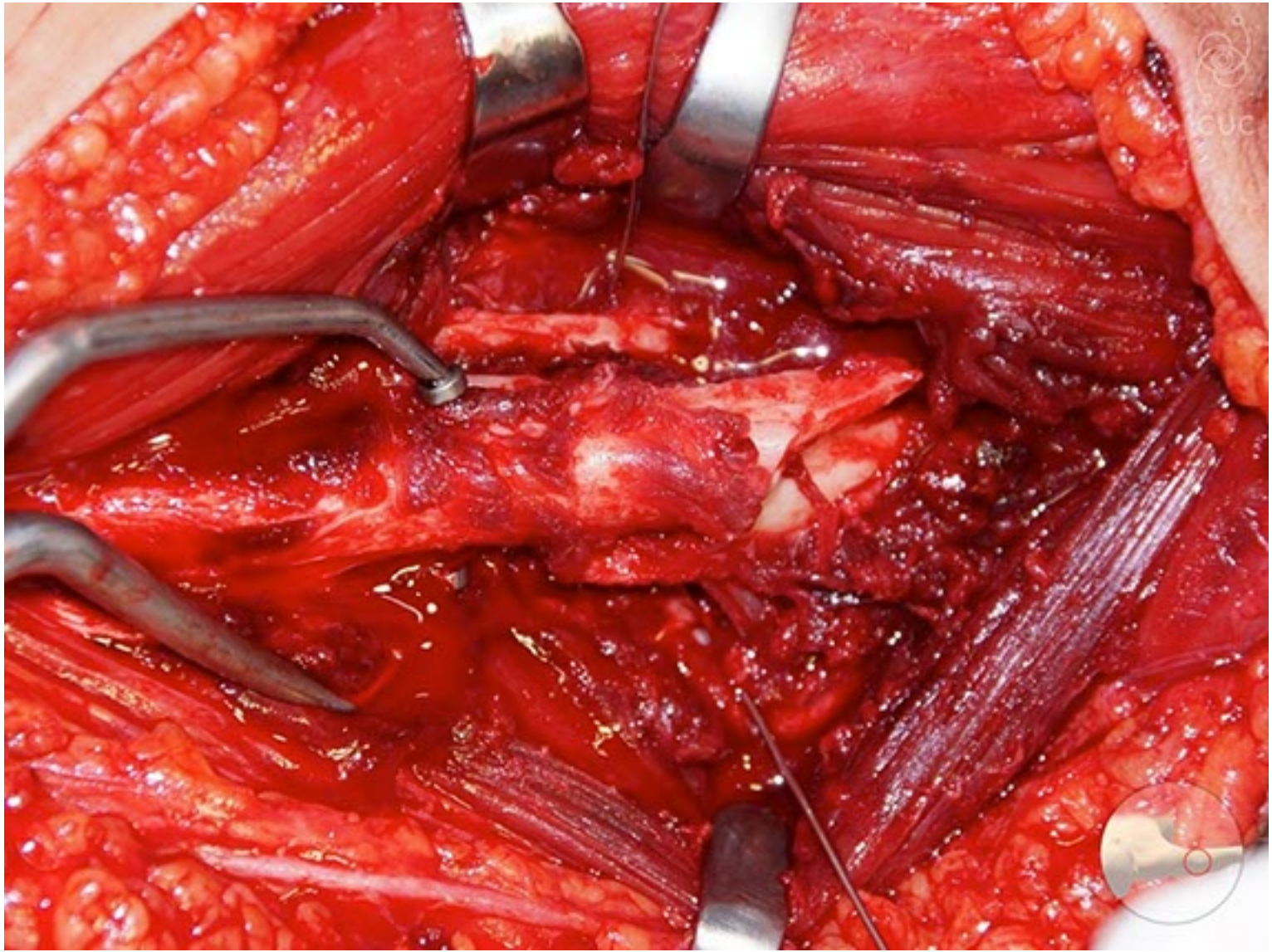
Is like a vascular bridge between the distal and proximal segments which is why stripping at the lateral or the anterior side of this fracture is not a worry as much as it may be. So we've got a vascular bridge medially, a spiral fracture laterally and a radial nerve posteriorly.

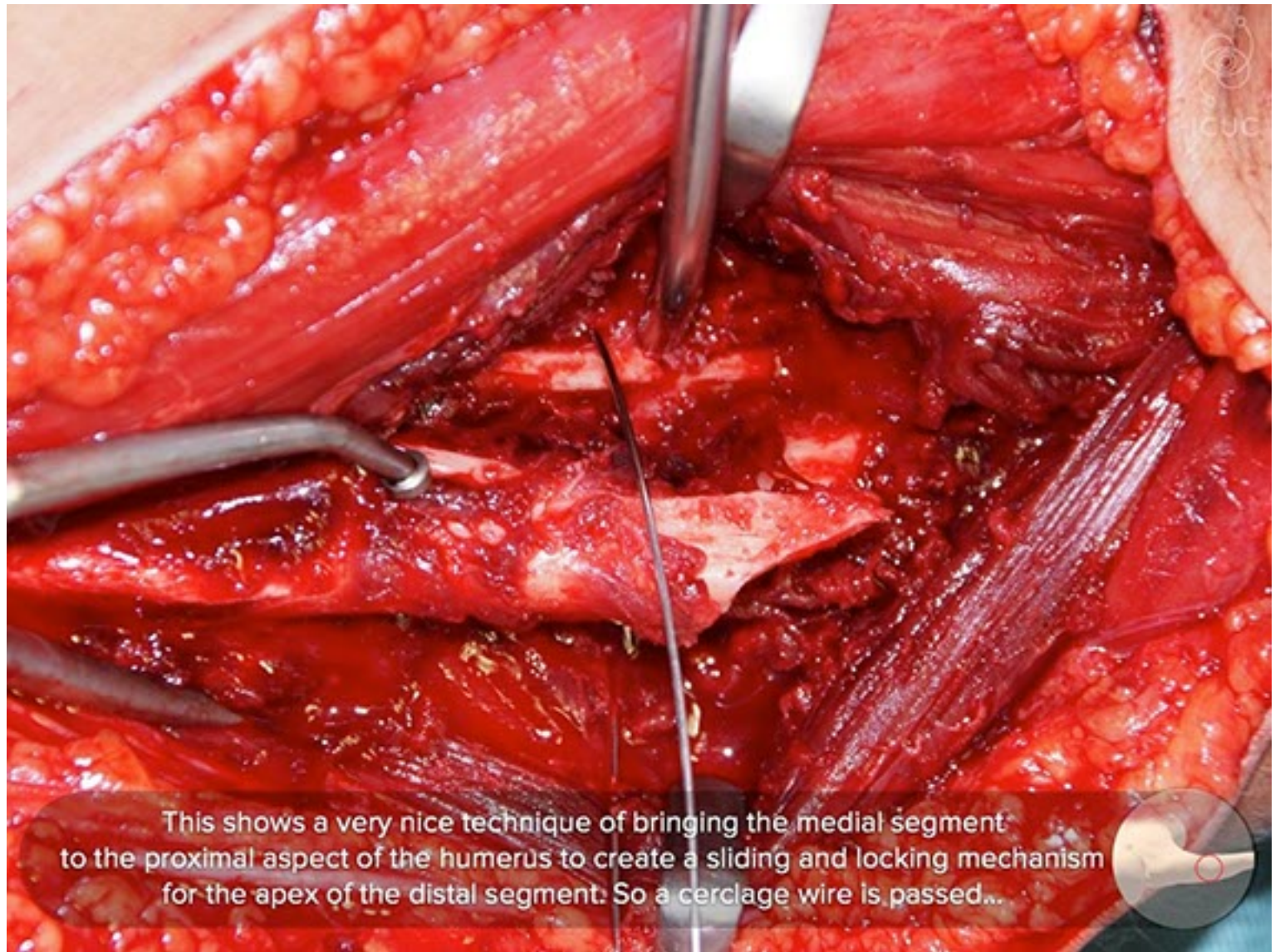

One starts to worry about devascularizing this fracture. There is a periosteum stripping but the priority here is the recovery of the radial nerve. We know eventually the humerus will heal. How quickly it heals is dependent on stability and perfusion. But we need the radial nerve to be safe.

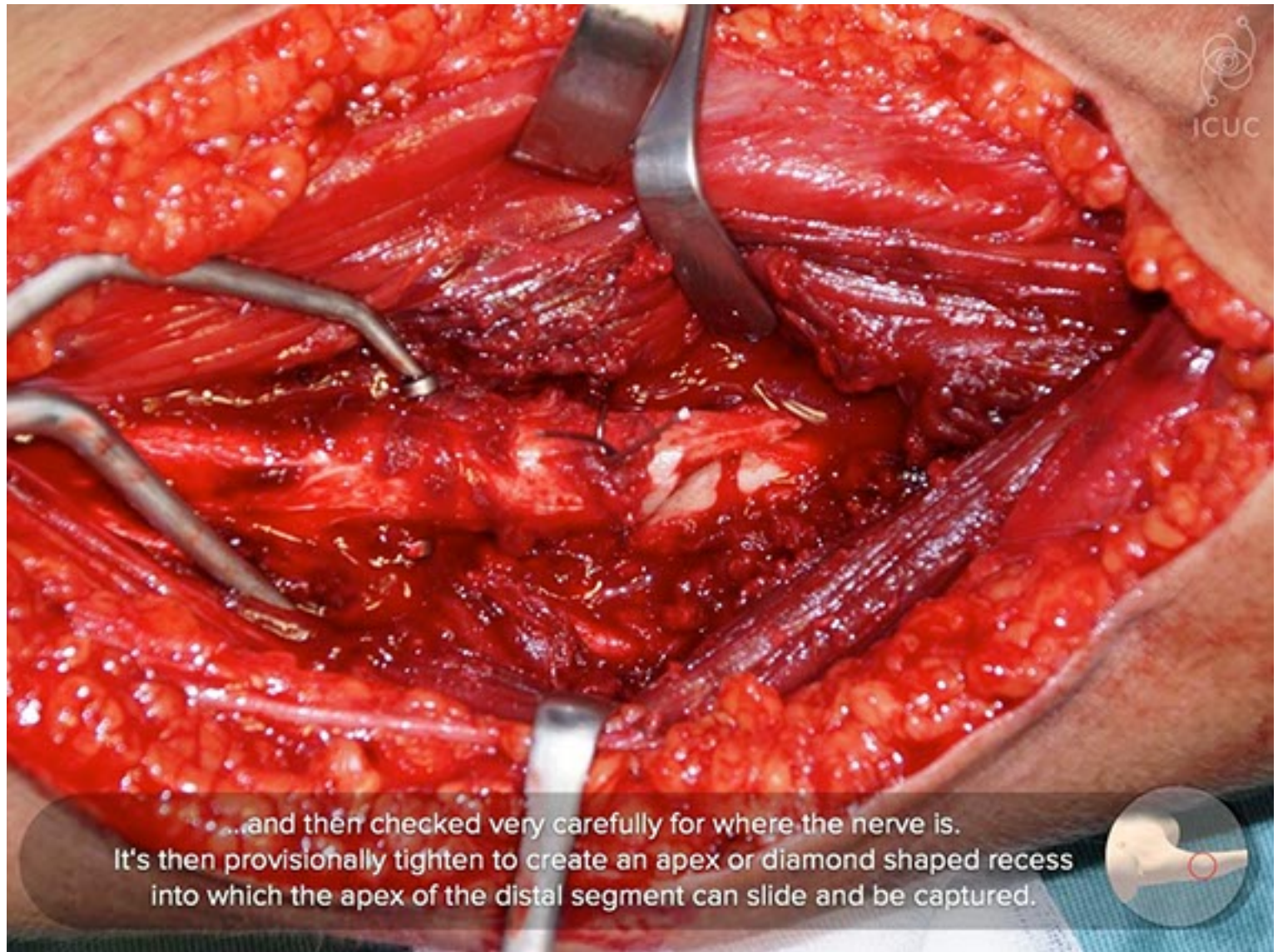




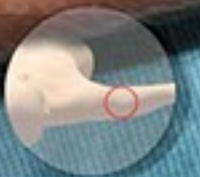


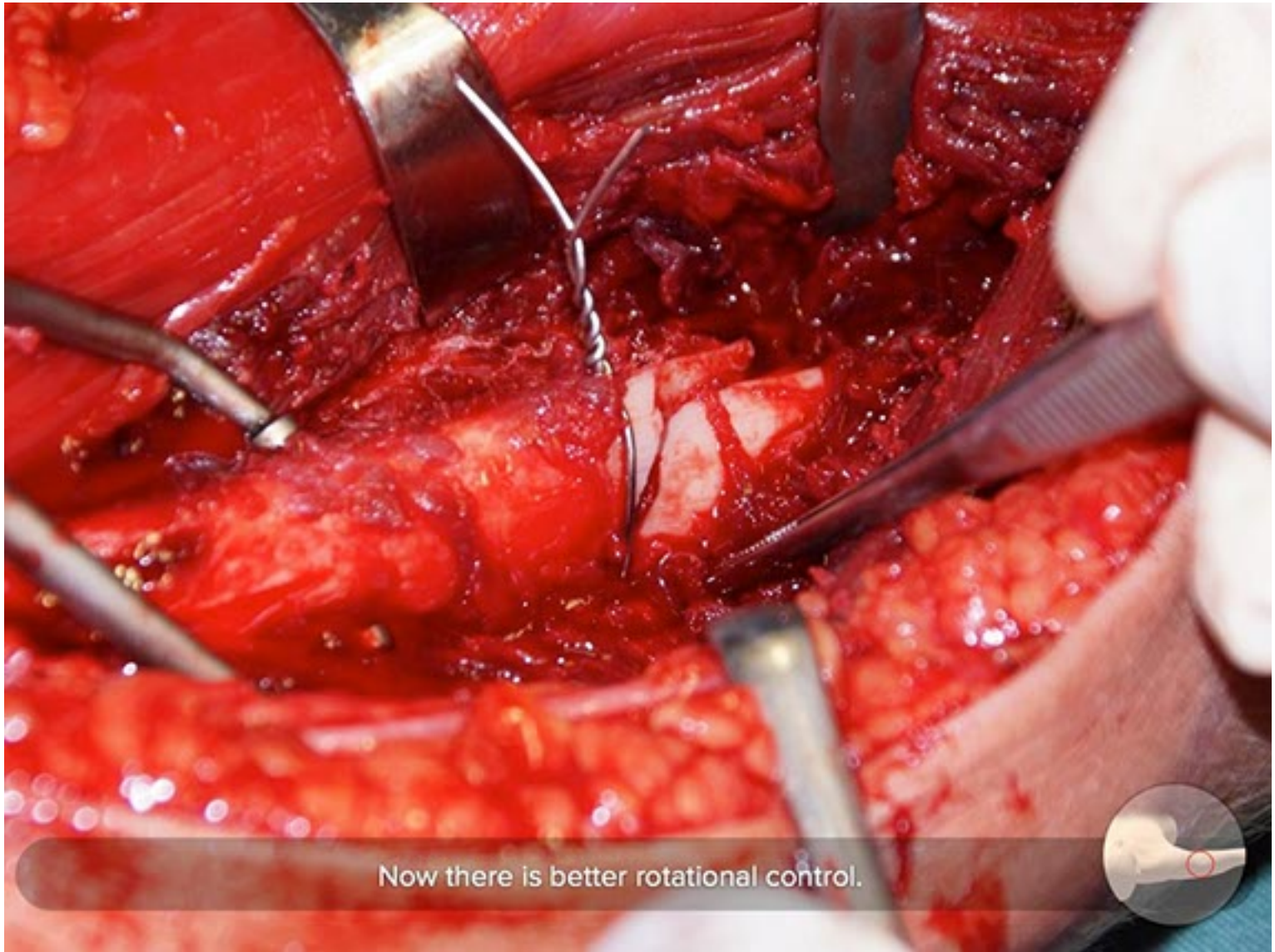This shows a very nice technique of bringing the medial segment to the proximal aspect of the humerus to create a sliding and locking mechanism for the apex of the distal segment. So a cerclage wire is passed..



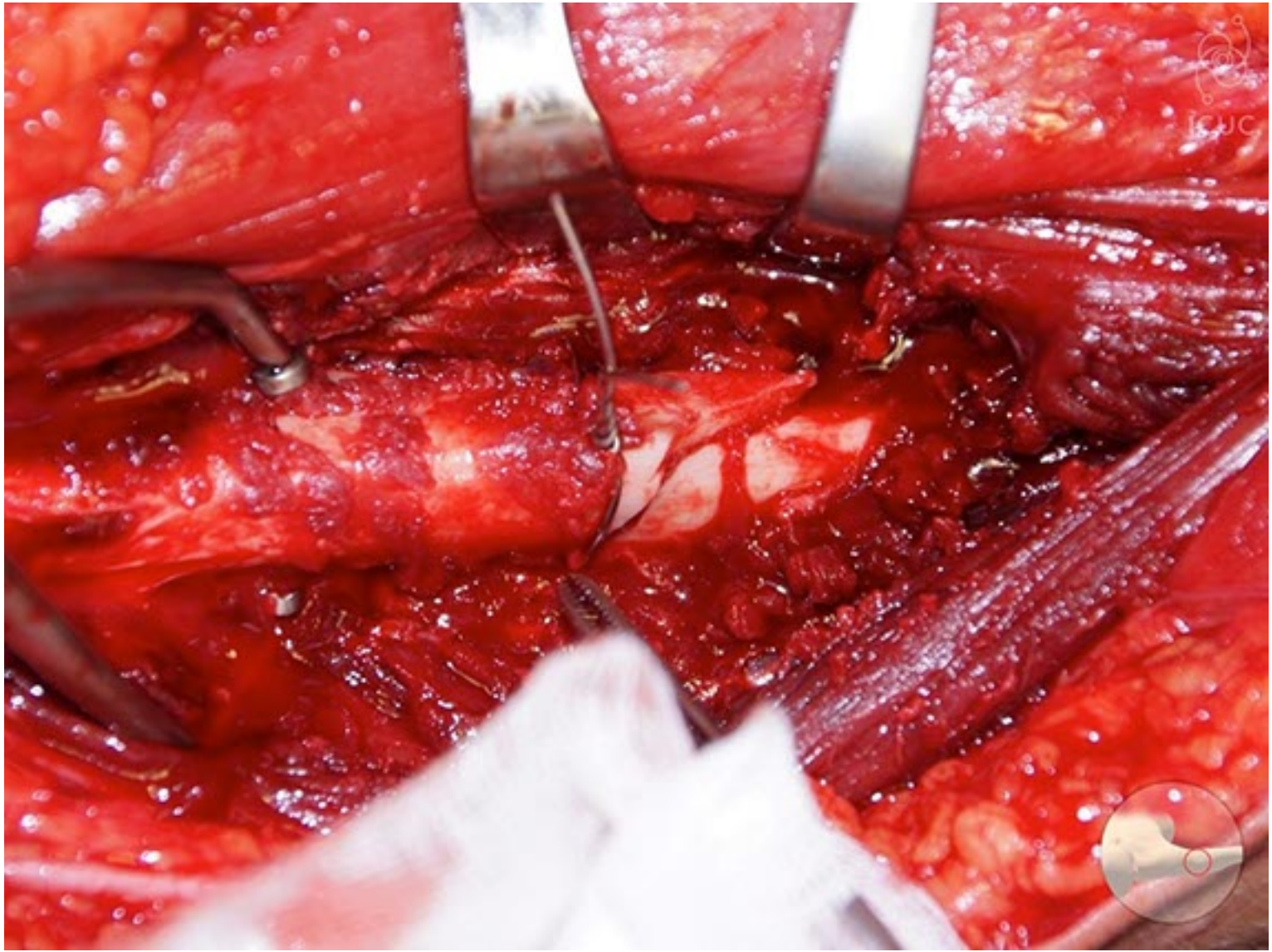
...and then checked very carefully for where the nerve is.
It's then provisionally tighten to create an apex or diamond shaped recess
into which the apex of the distal segment can slide and be captured.

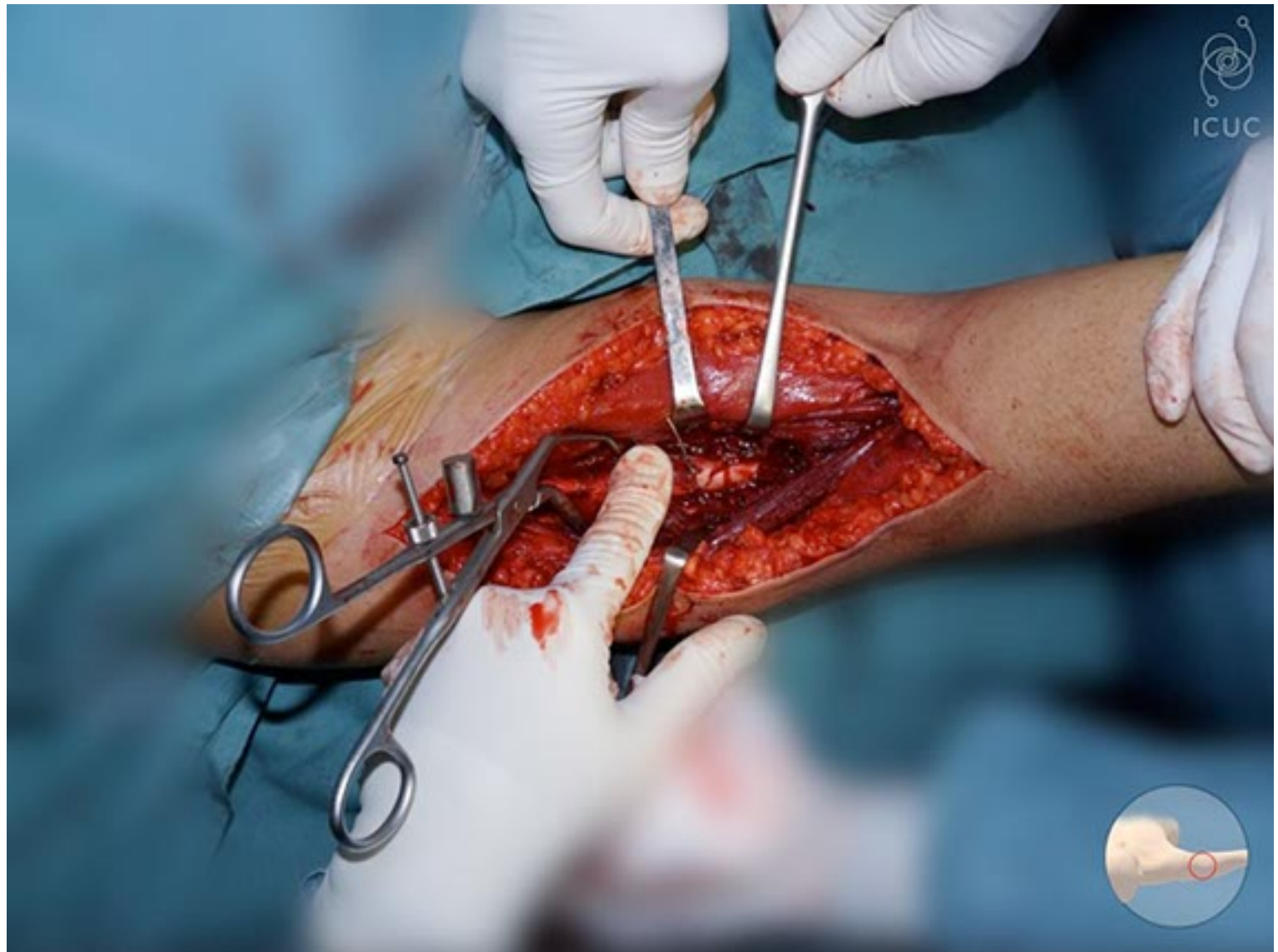

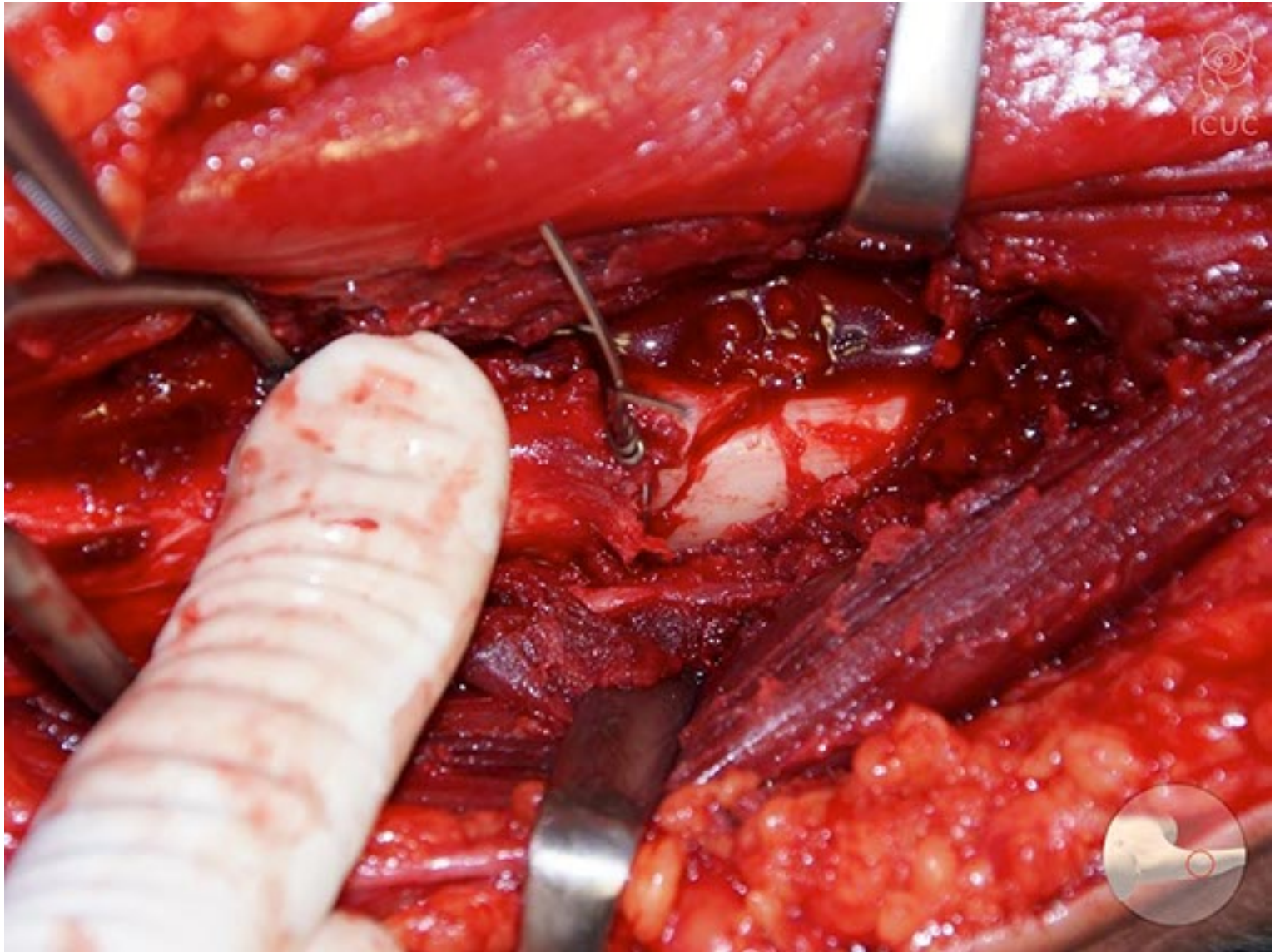


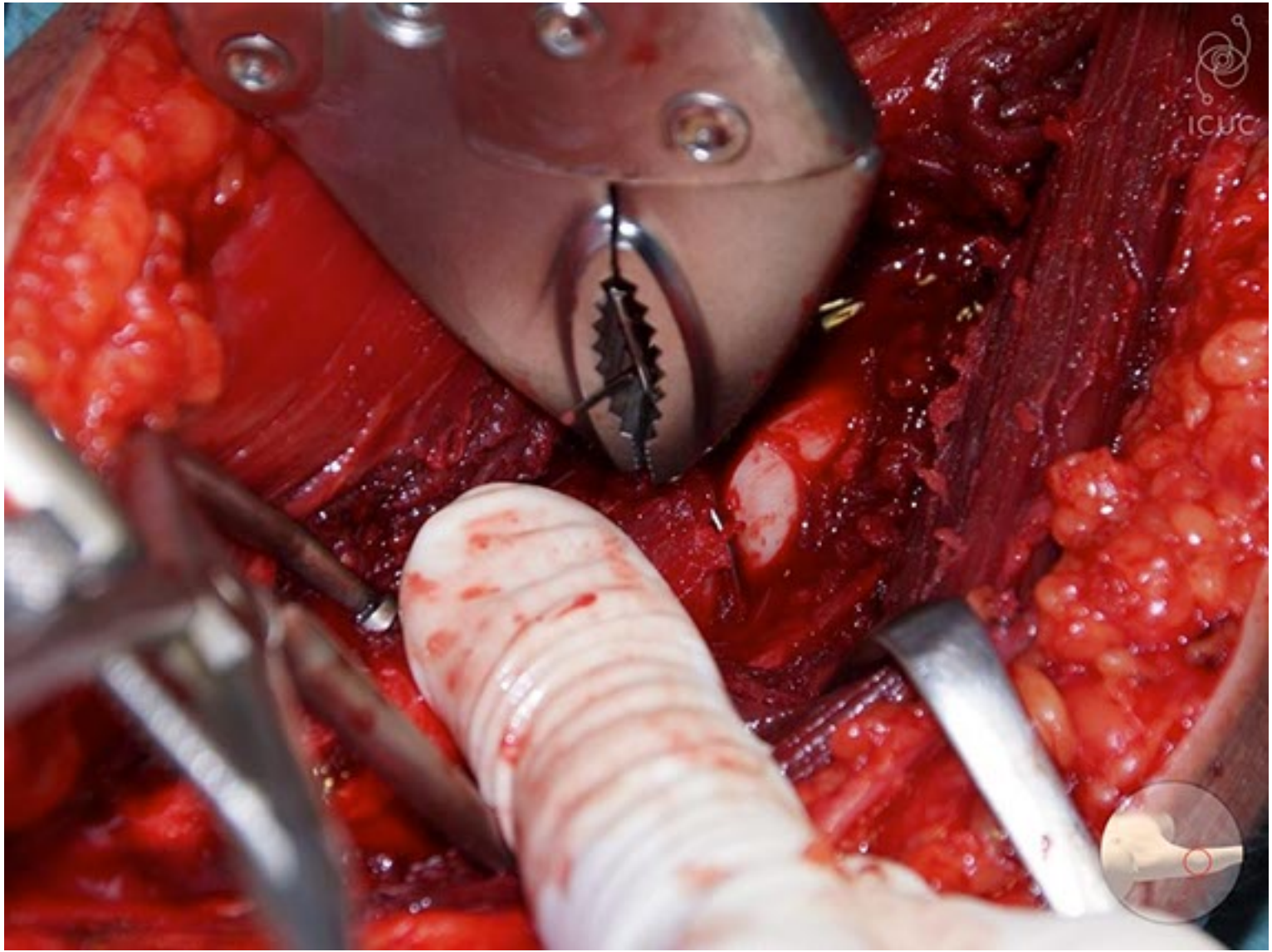
Now there is better rotational control.

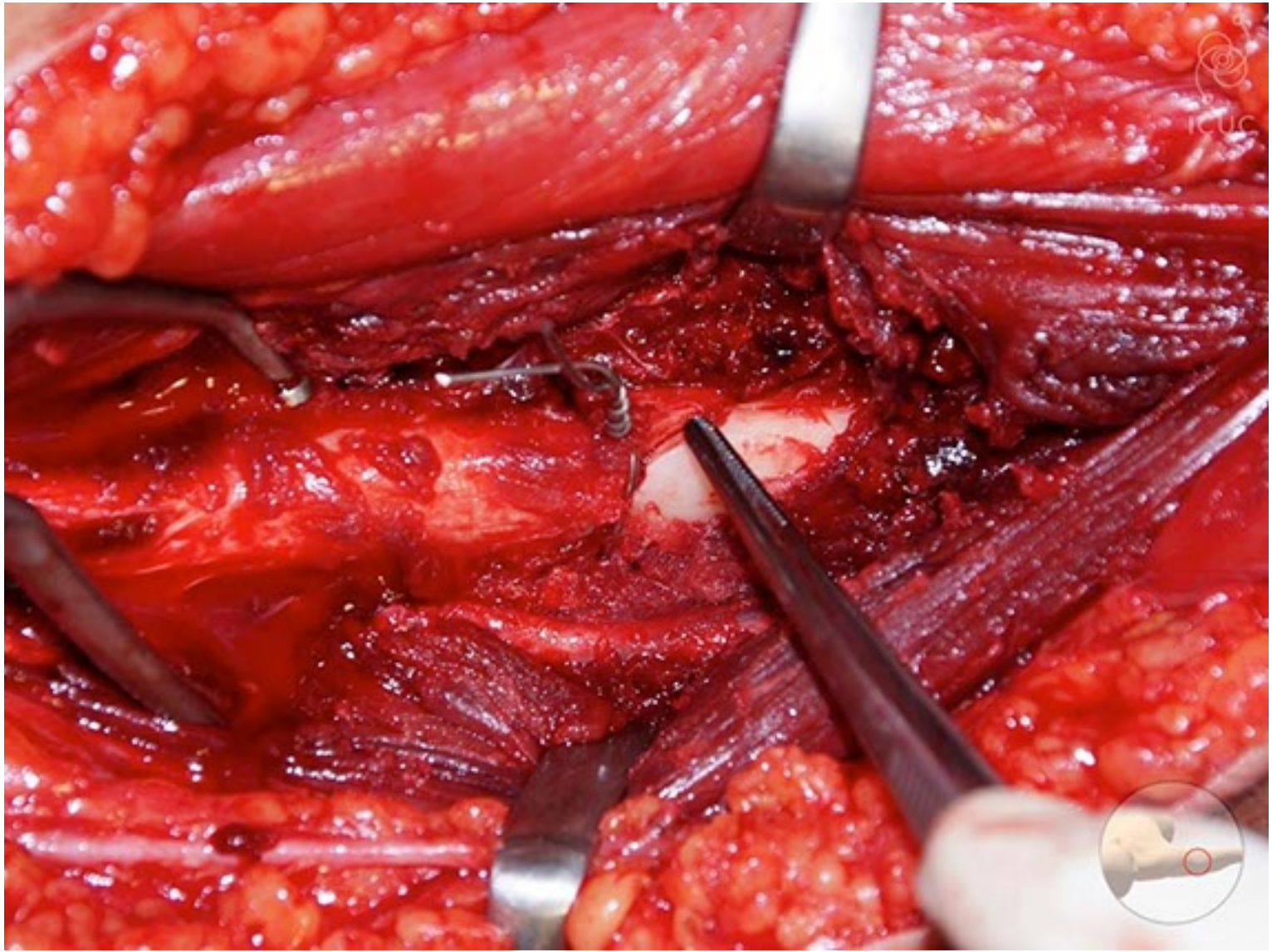


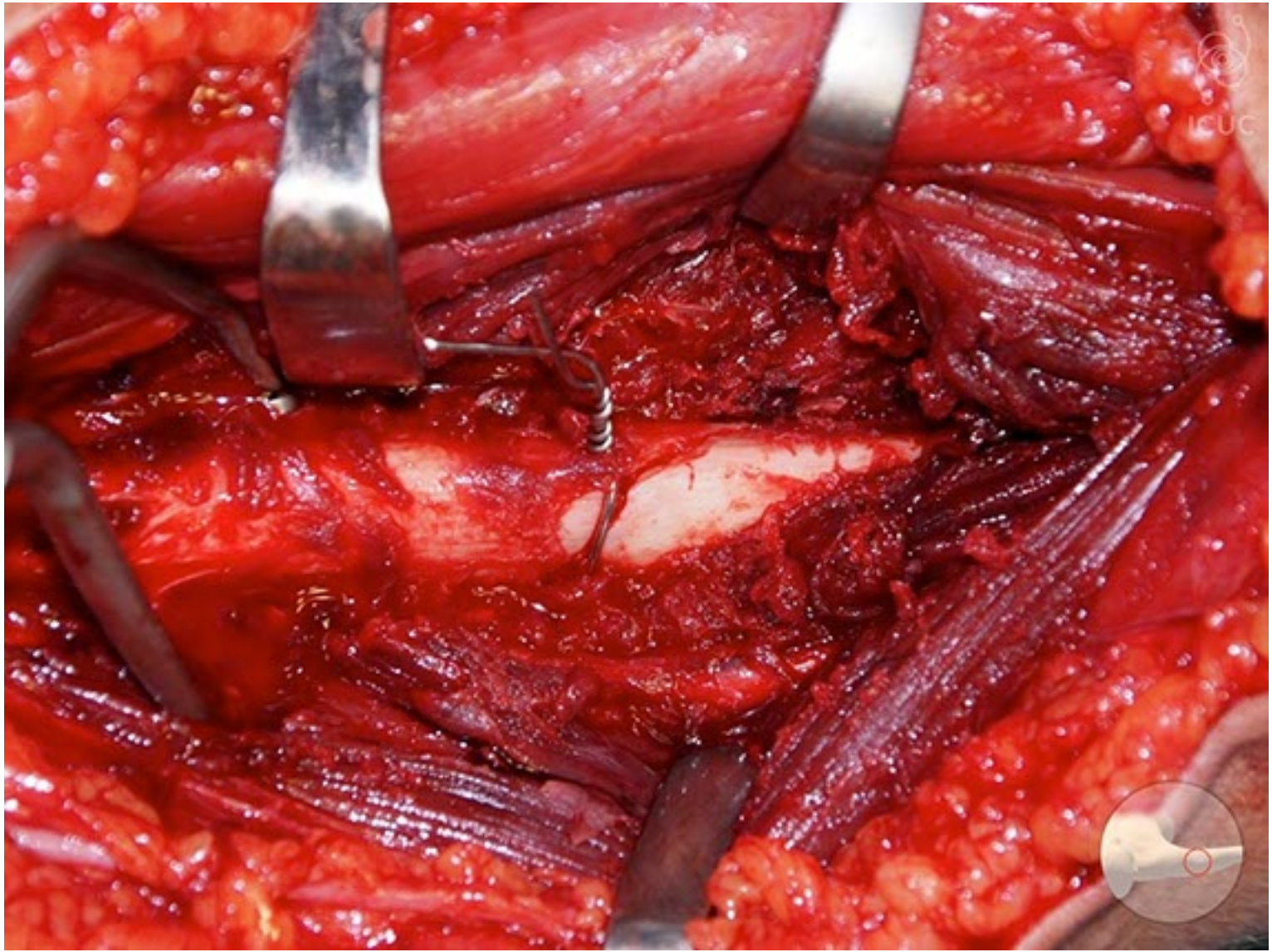
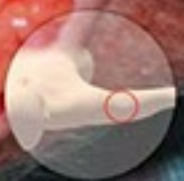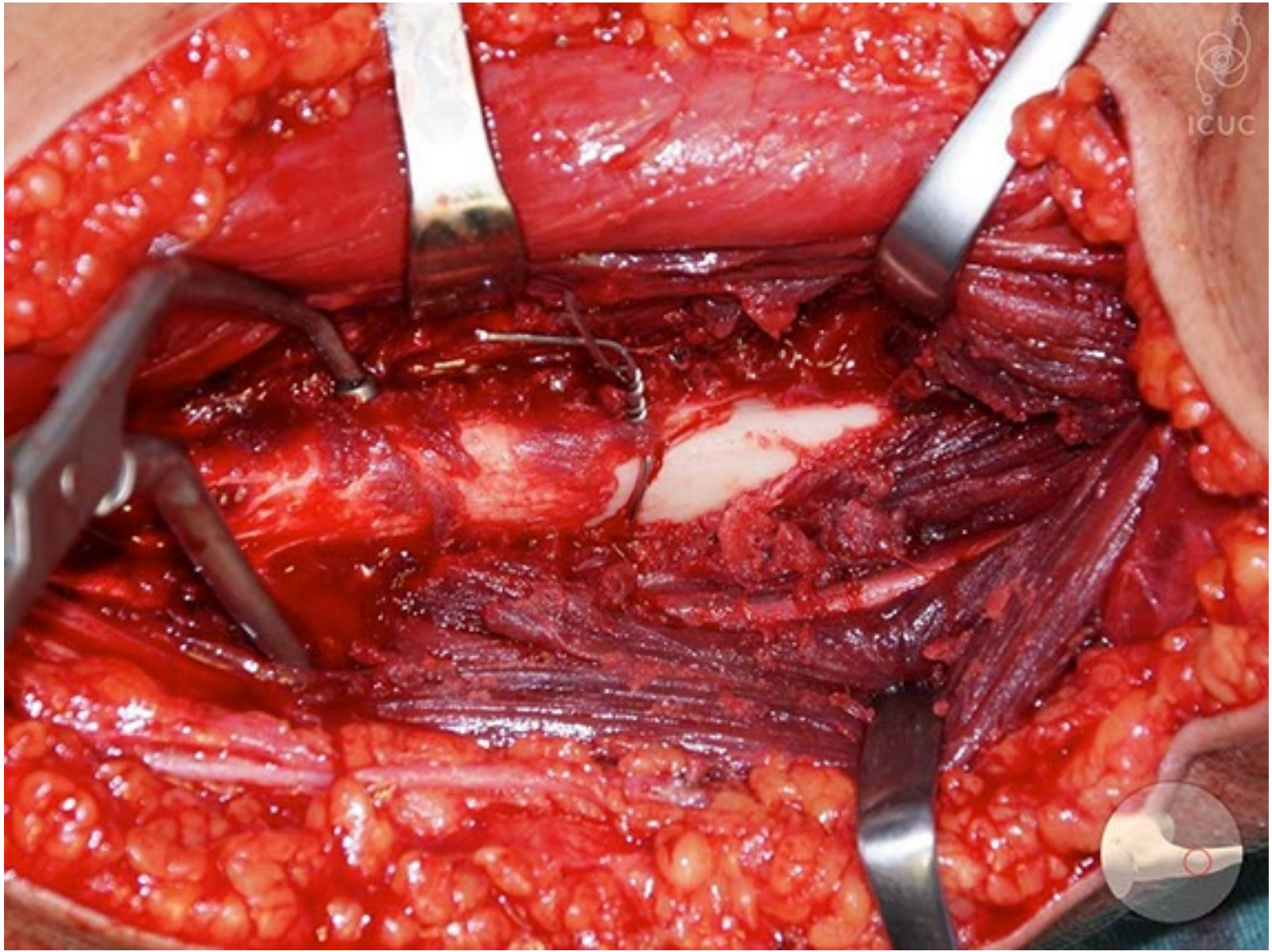





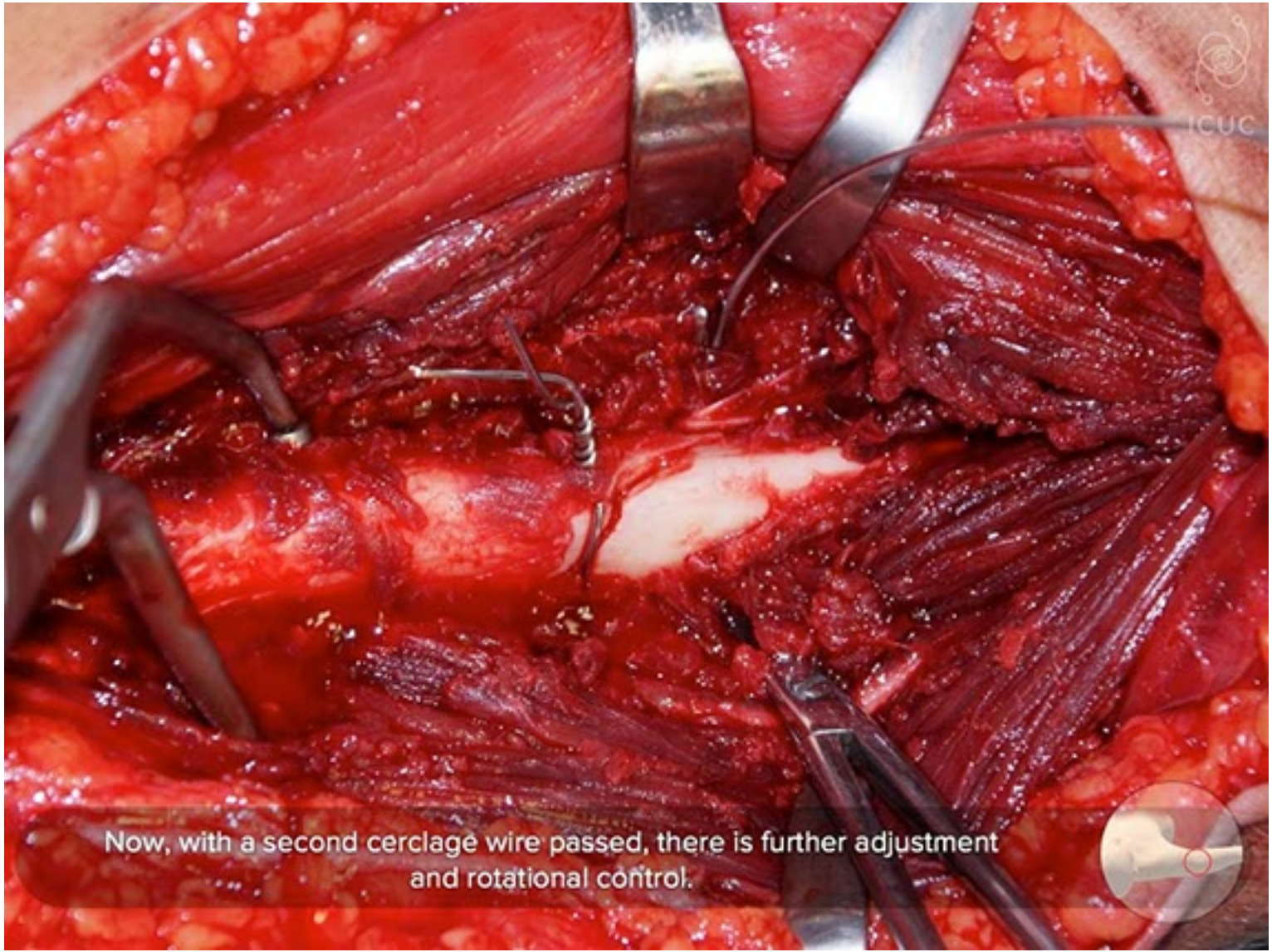


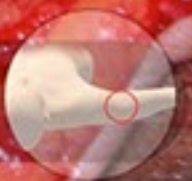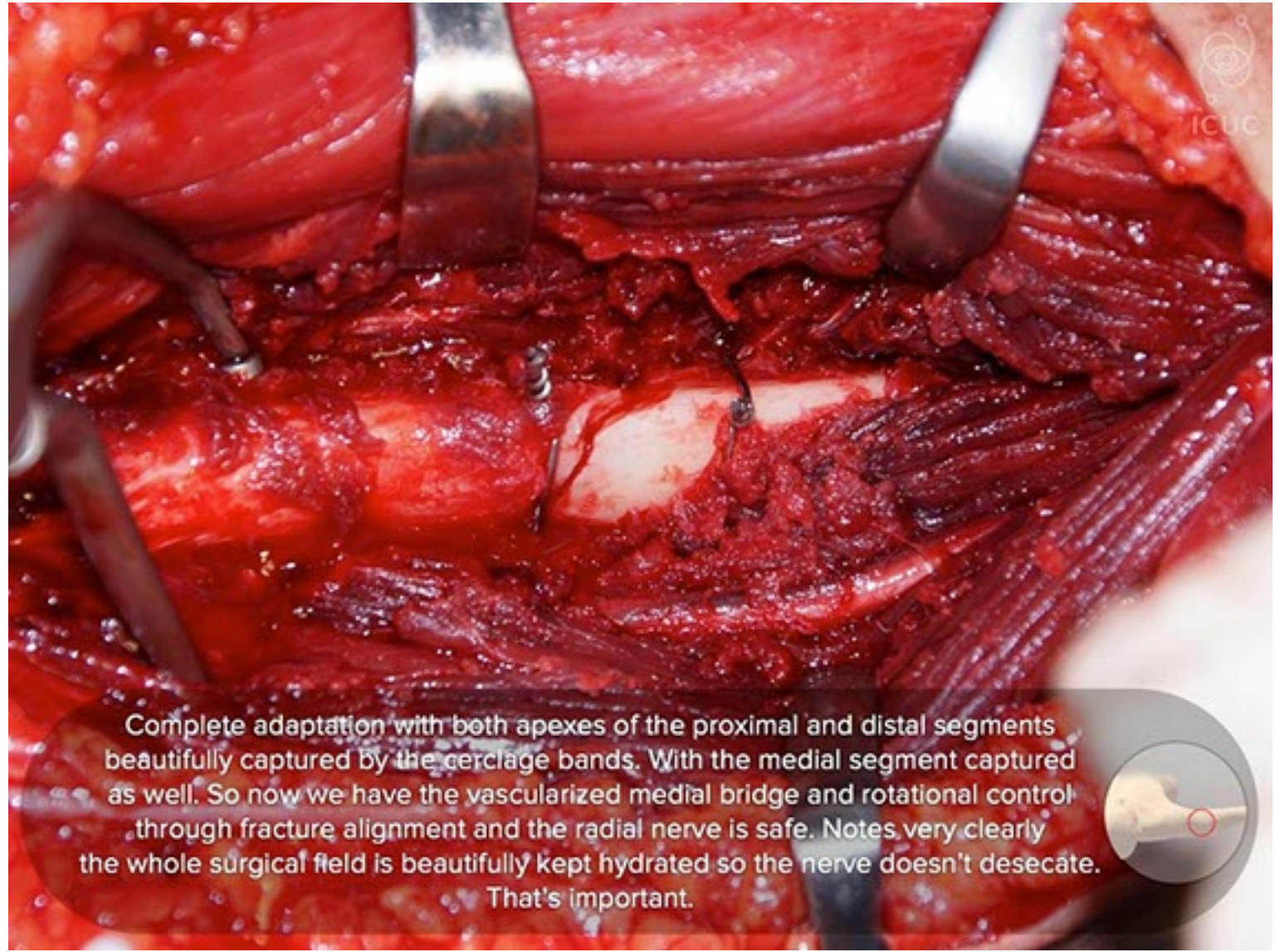






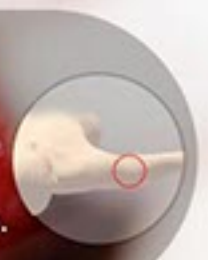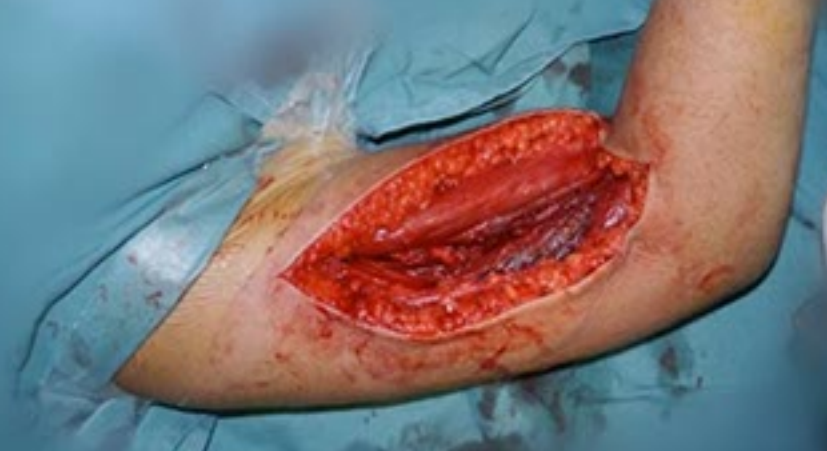Now, with a second cerclage wire passed, there is further adjustment and rotational control.



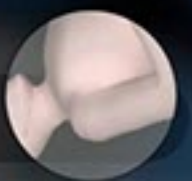

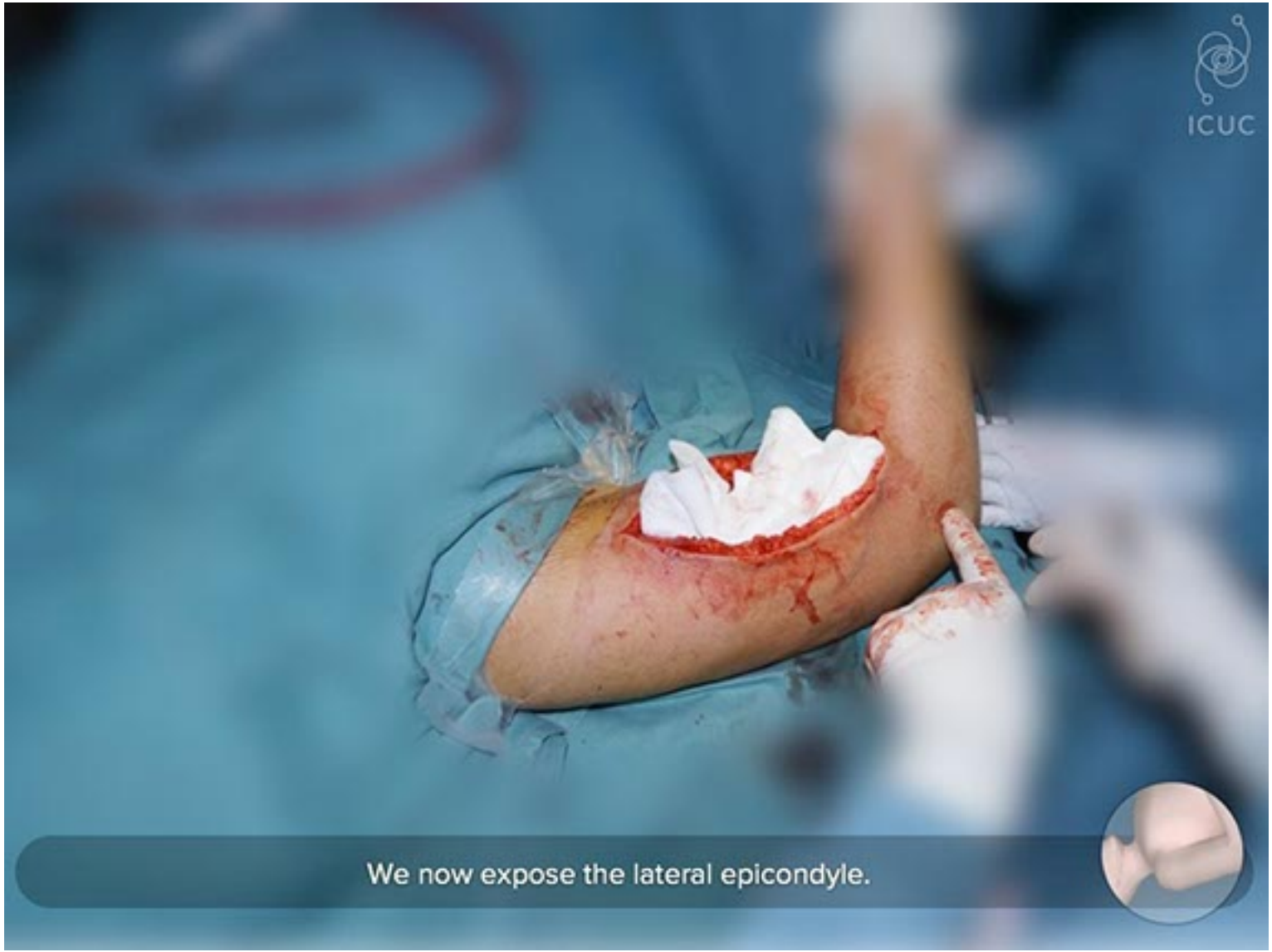Complete adaptation with both apexes of the proximal and distal segments beautifully captured by the cerclage bands. With the medial segment captured as well. So now we have the vascularized medial bridge and rotational control through fracture alignment and the radial nerve is safe. Notes very clearly the whole surgical field is beautifully kept hydrated so the nerve doesn't desecate. That's important.



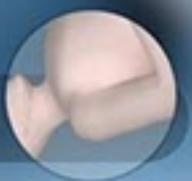

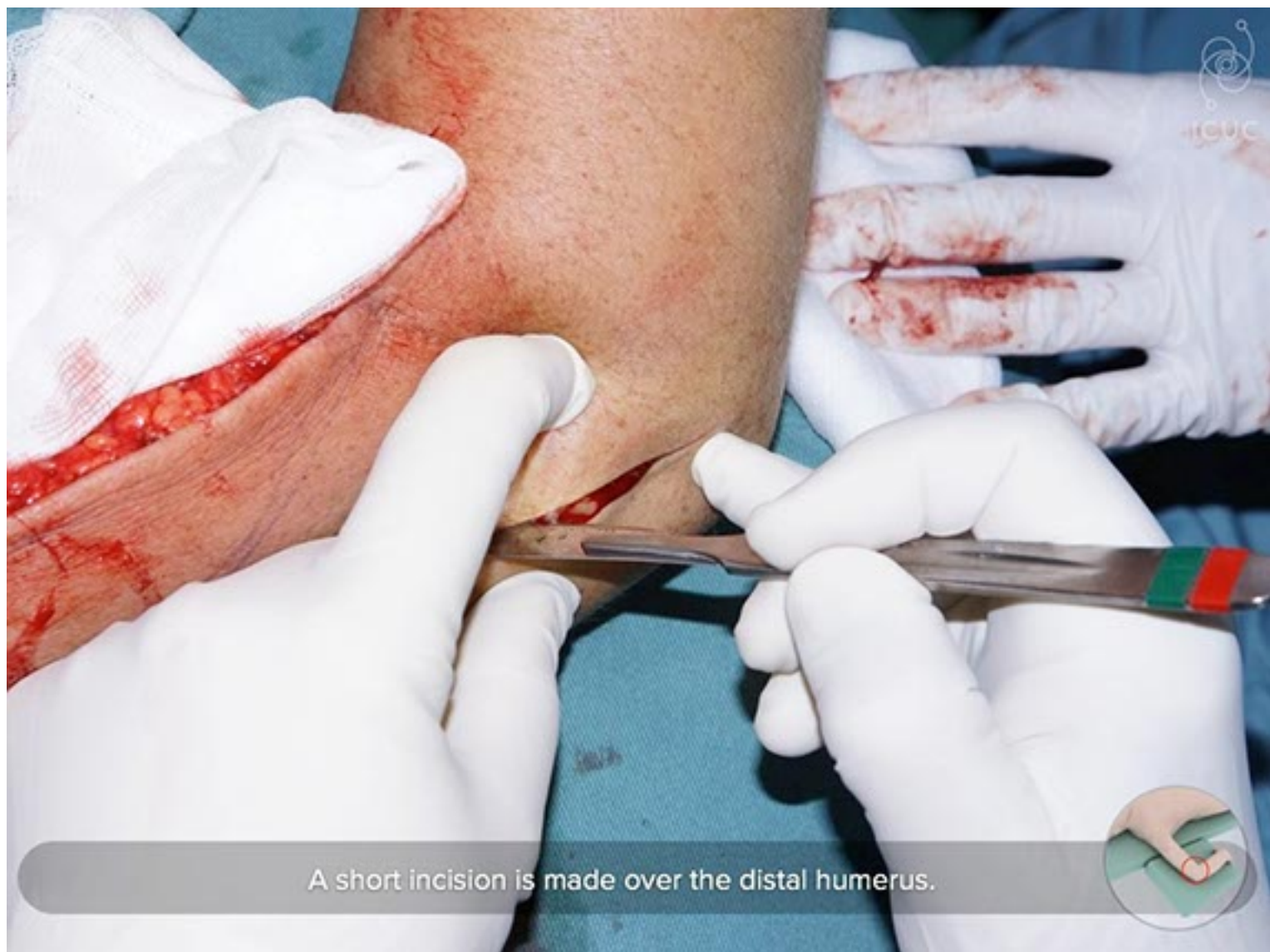Flexion of the elbow.

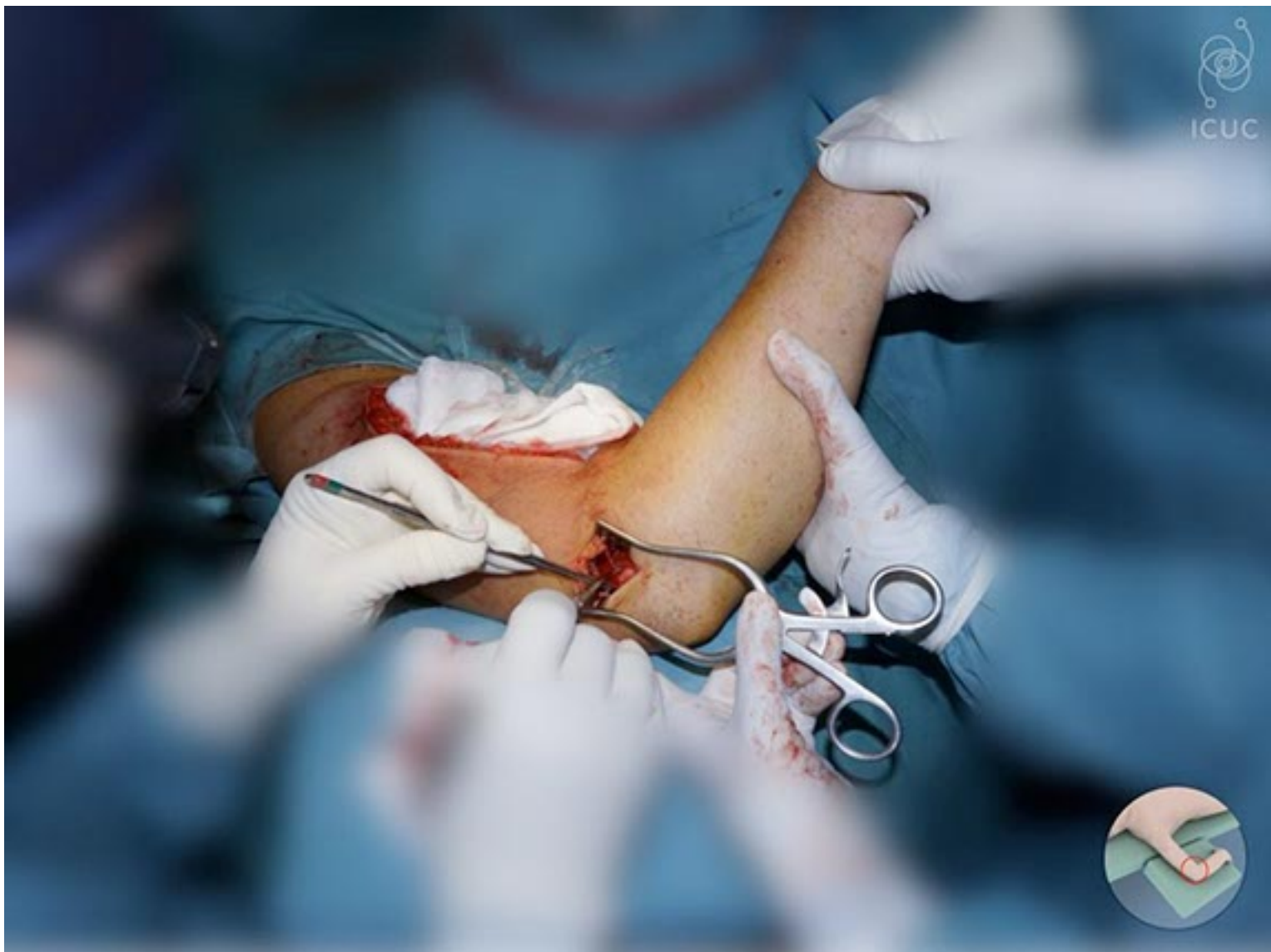

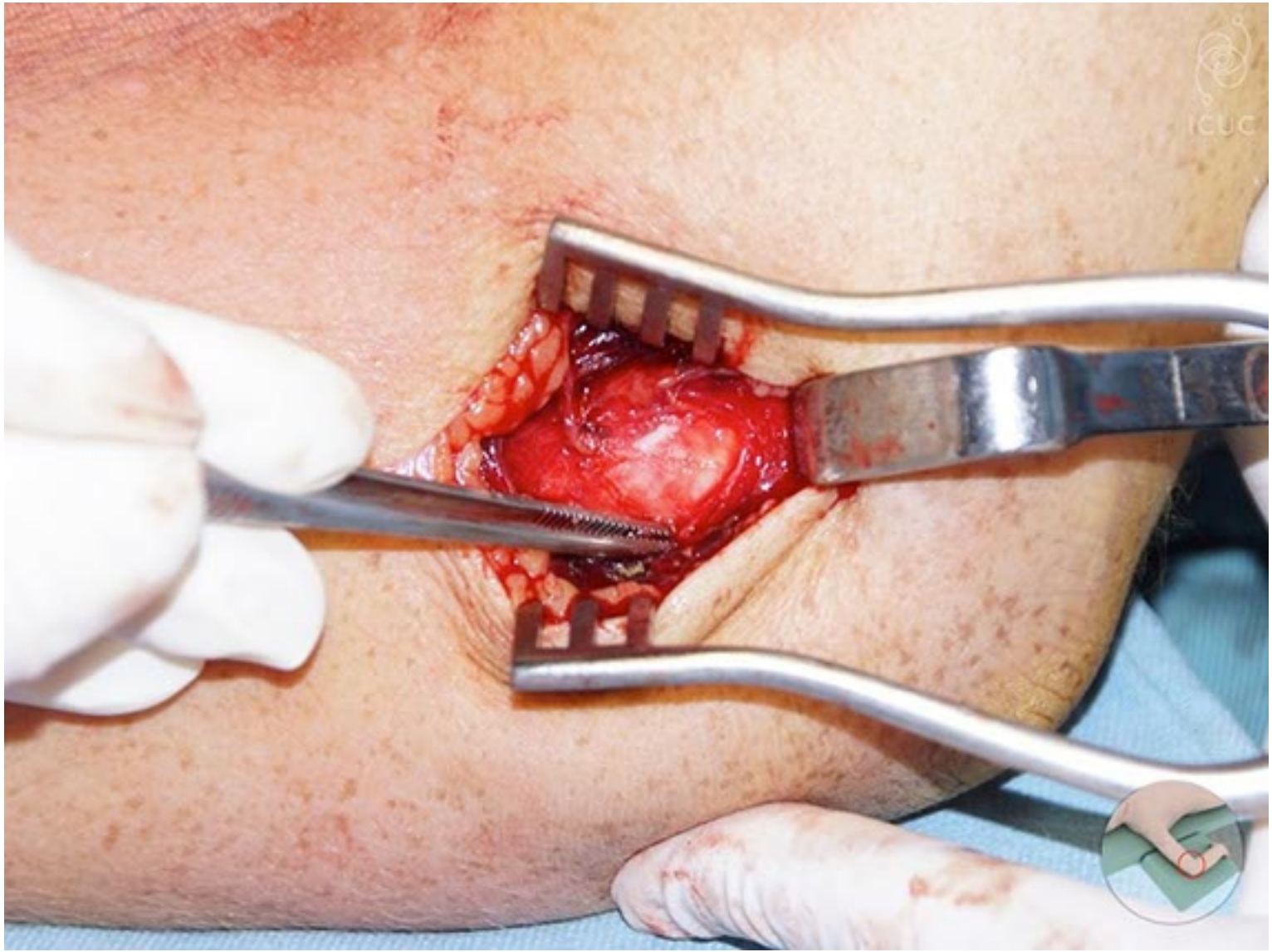


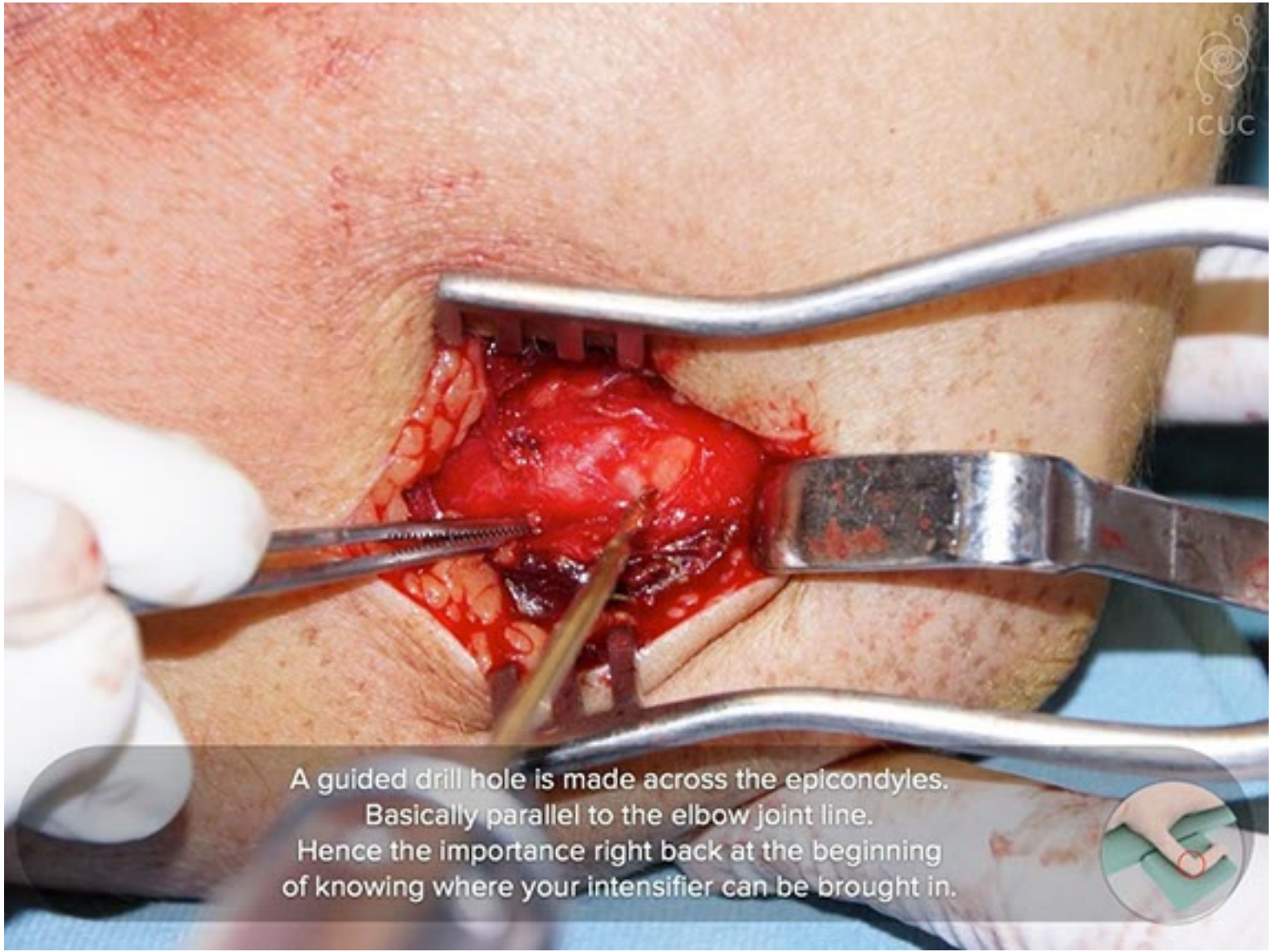We now expose the lateral epicondyle.








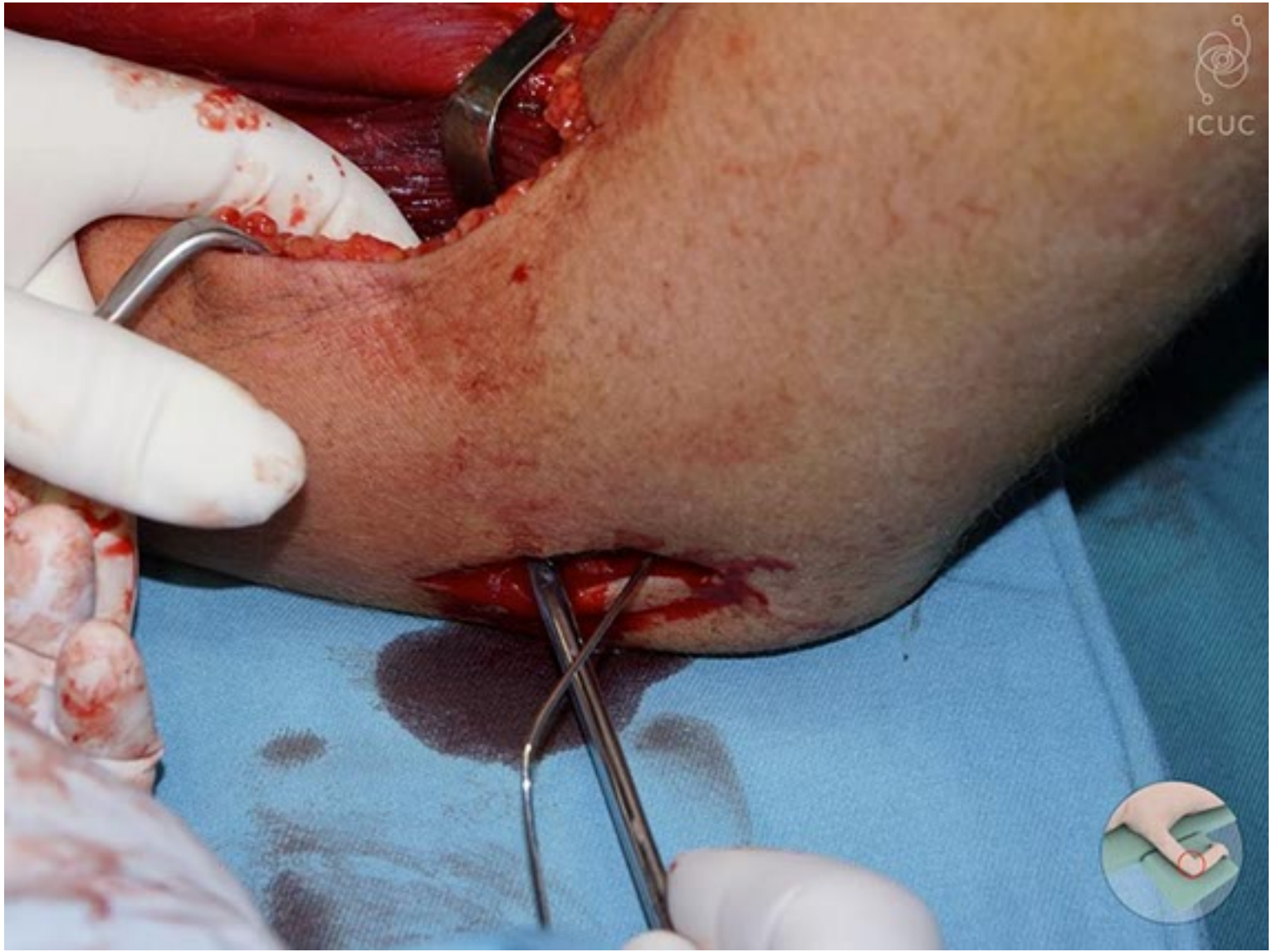


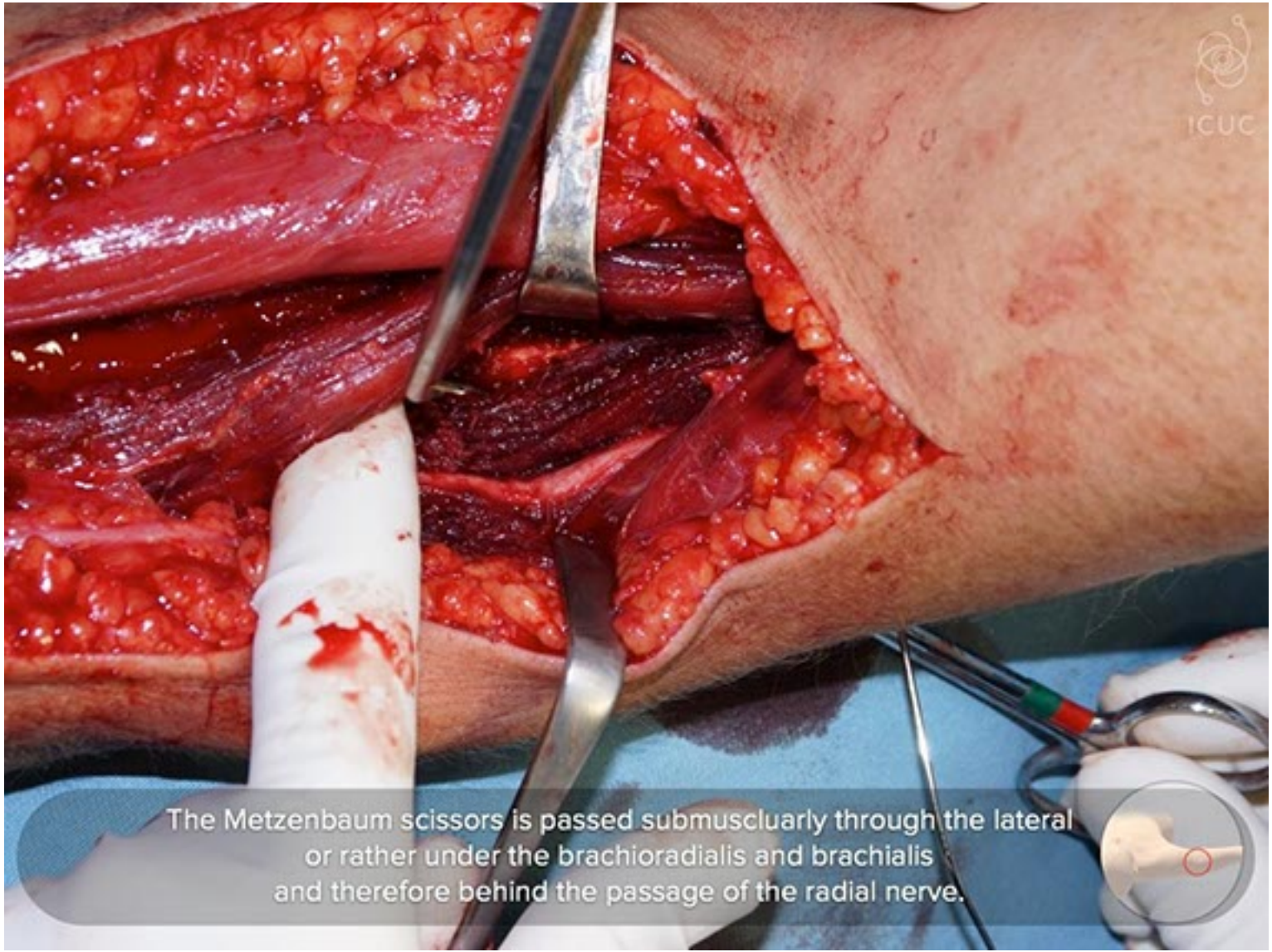

A guided drill hole is made across the epicondyles.
Basically parallel to the elbow joint line.
Hence the importance right back at the beginning
of knowing where your intensifier can be brought in.

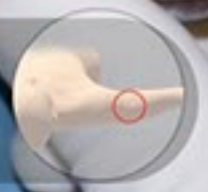

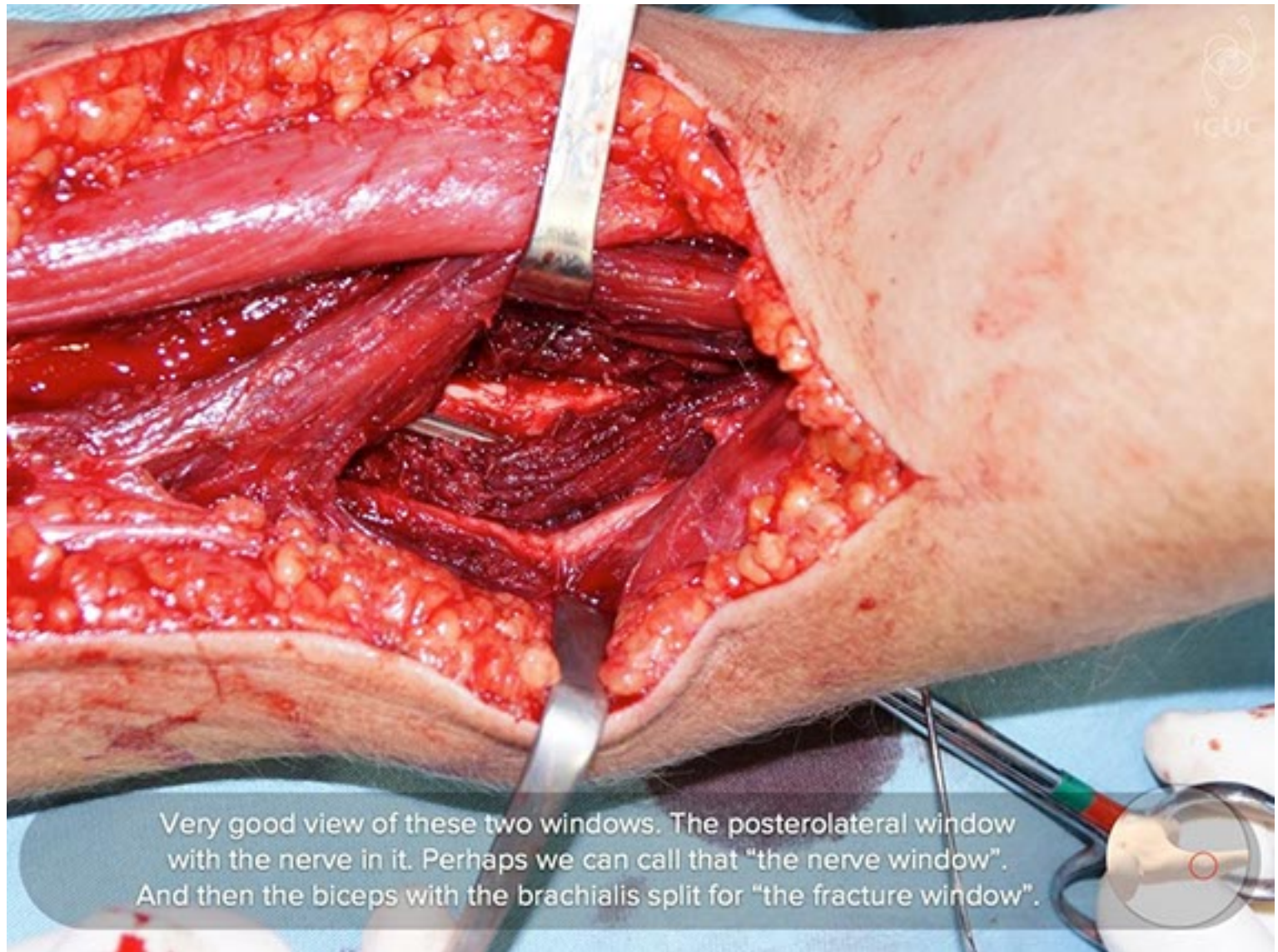That is a very challenging thing to do.
I would normally undertake this with image intensification.



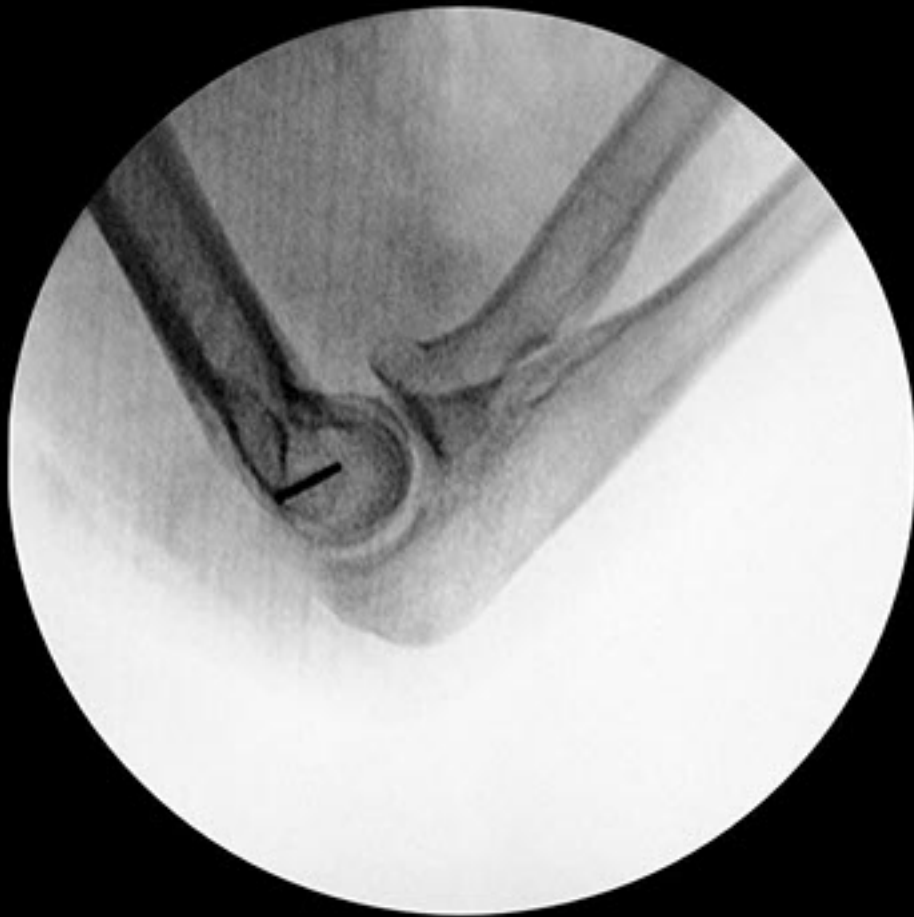

The Metzenbaum scissors is passed submuscularly through the lateral or rather under the brachioradialis and brachialis and therefore behind the passage of the radial nerve.

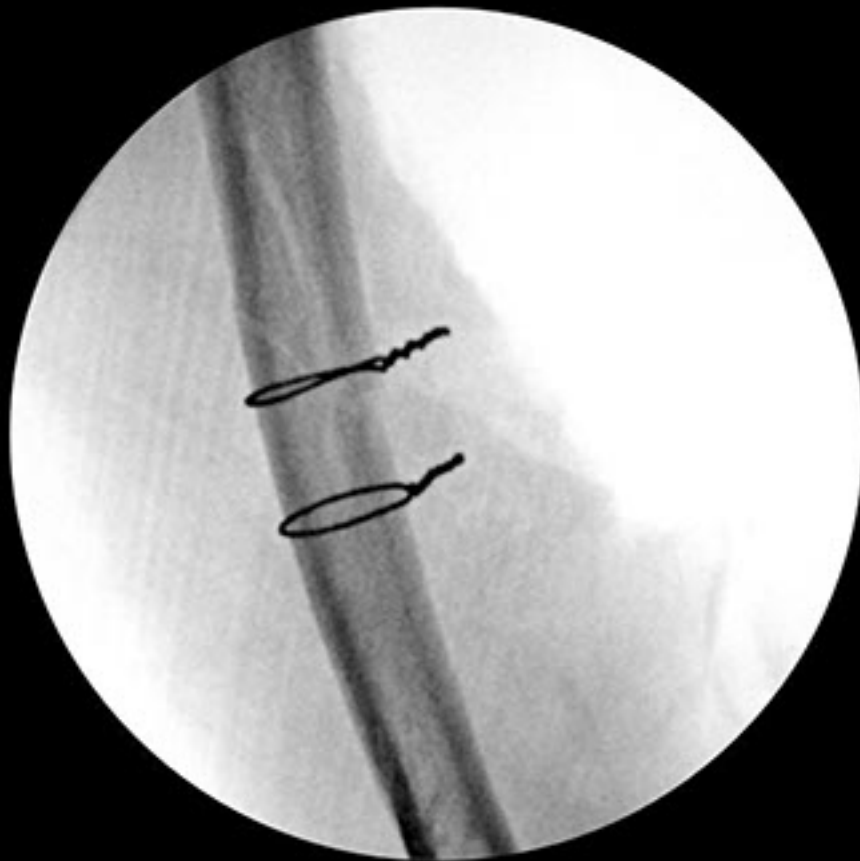



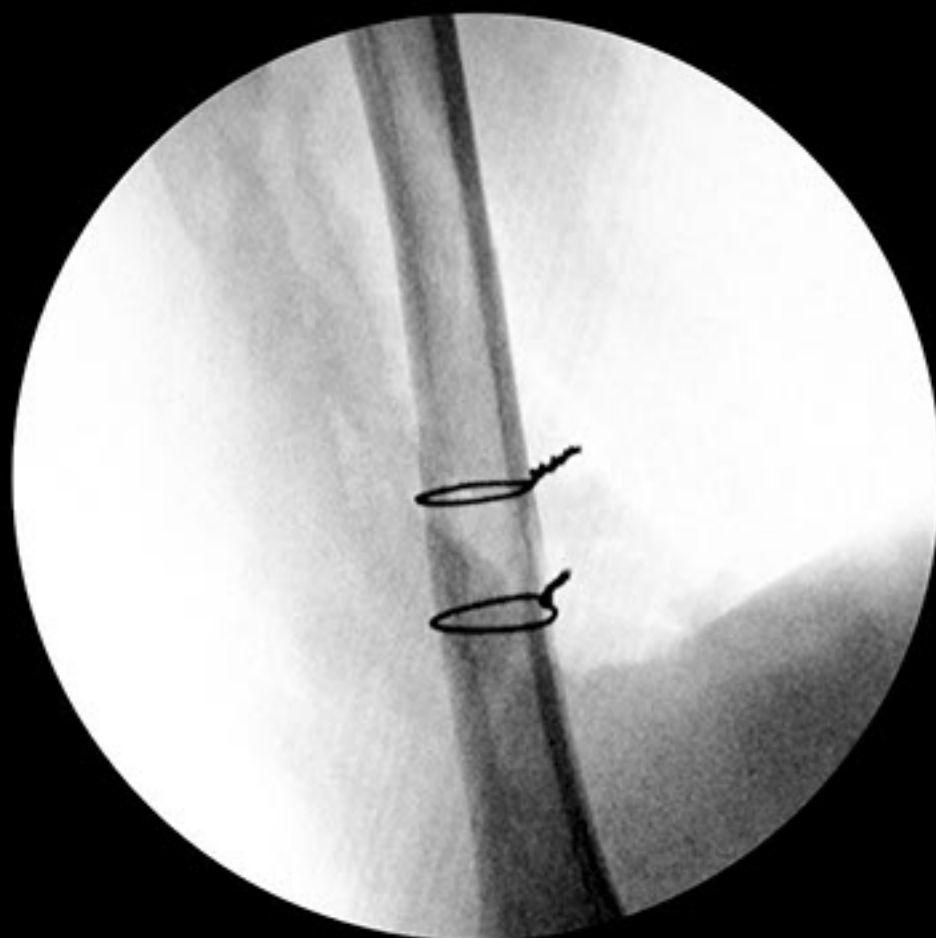Very good view of these two windows. The posterolateral window with the nerve in it. Perhaps we can call that "the nerve window". And then the biceps with the brachialis split for "the fracture window".



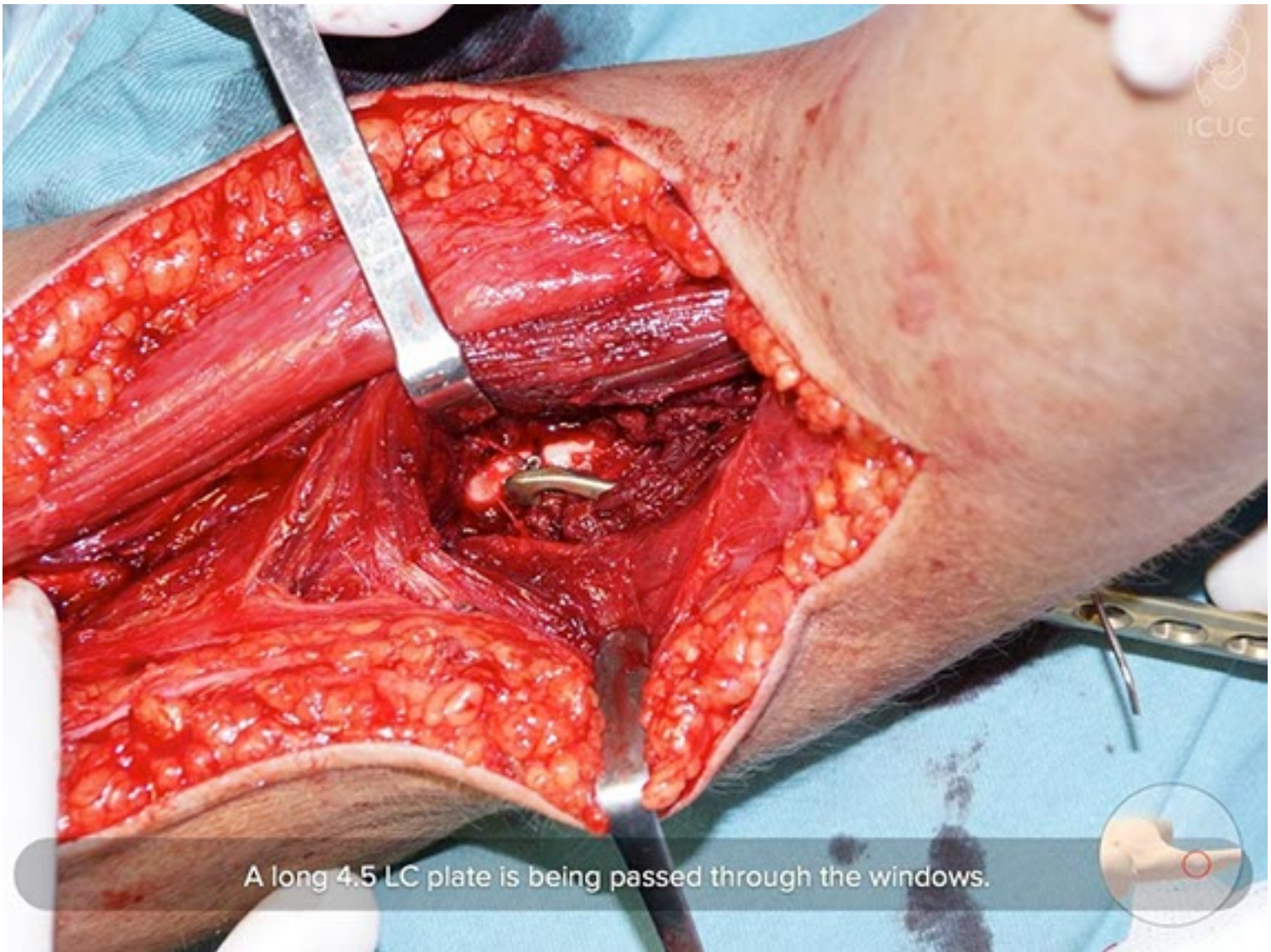
This image intensifier picture demonstrates the wire placed in the original drill hole right in the middle of the condyle of the humerus.



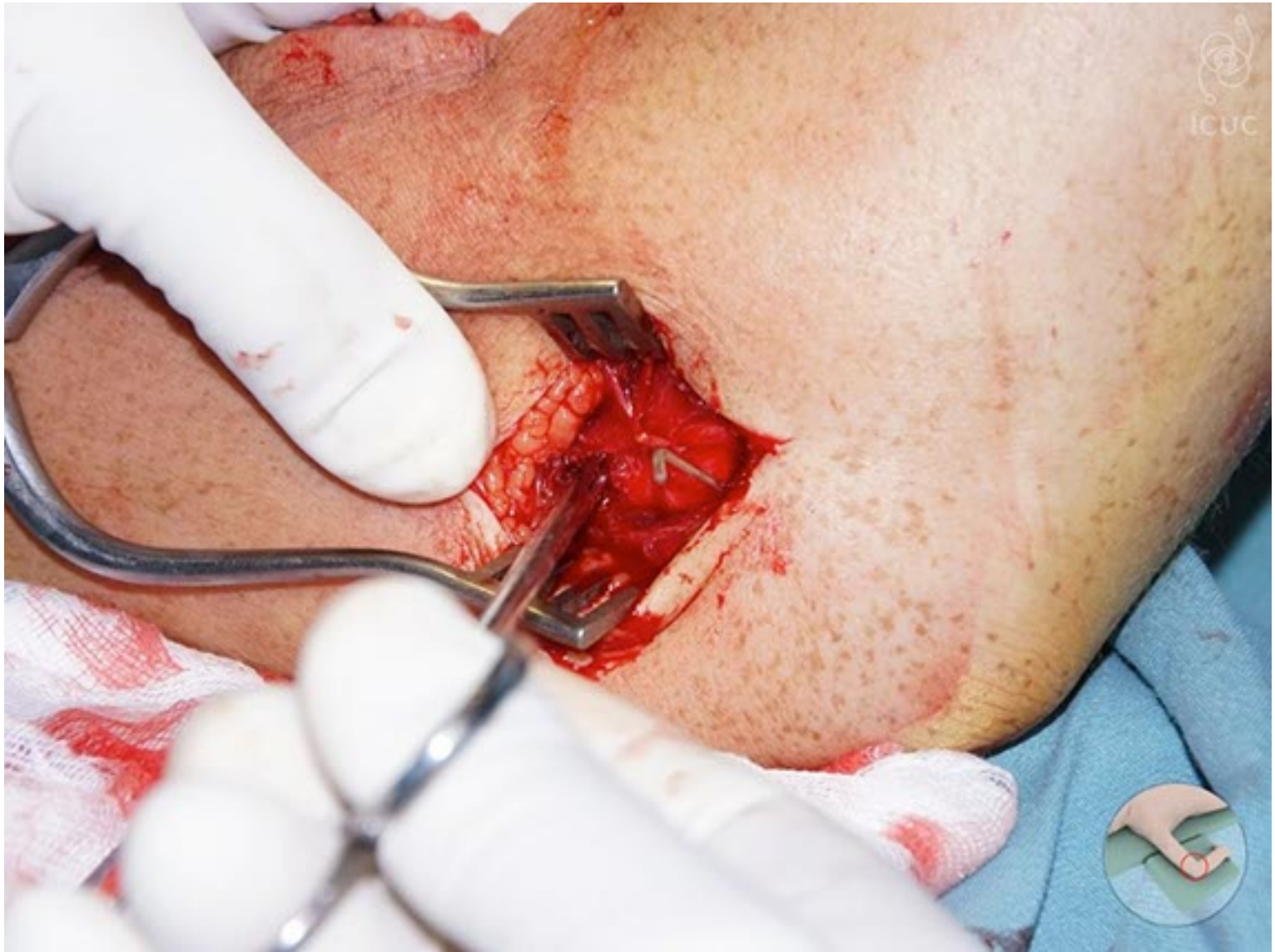This image intensifier picture shows the cerclage bands perfectly adapting the fracture. But we see proximally some gapping. So of course there is relative control not absolute stability. And now a plate is needed to neutralize this fracture.

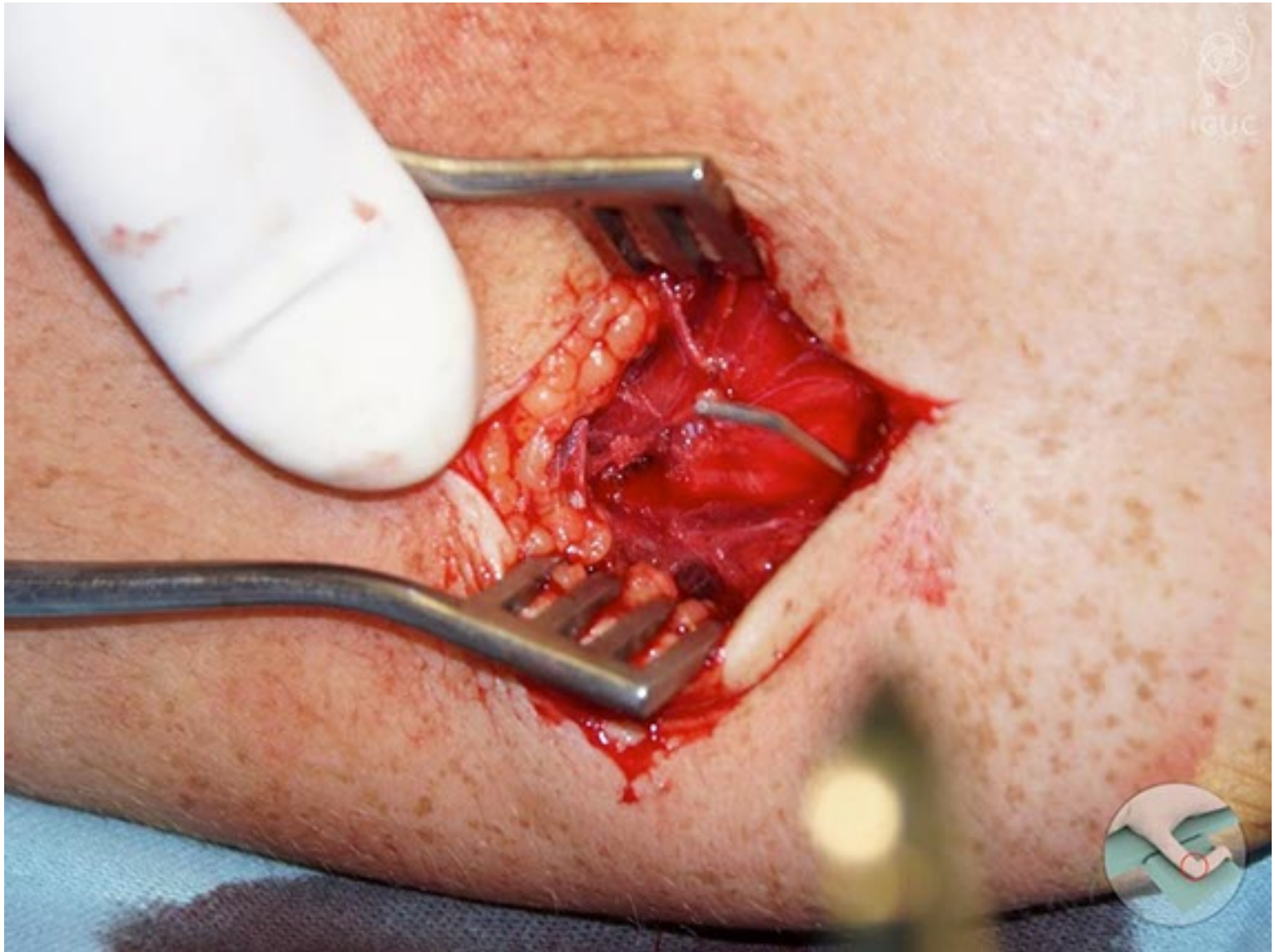


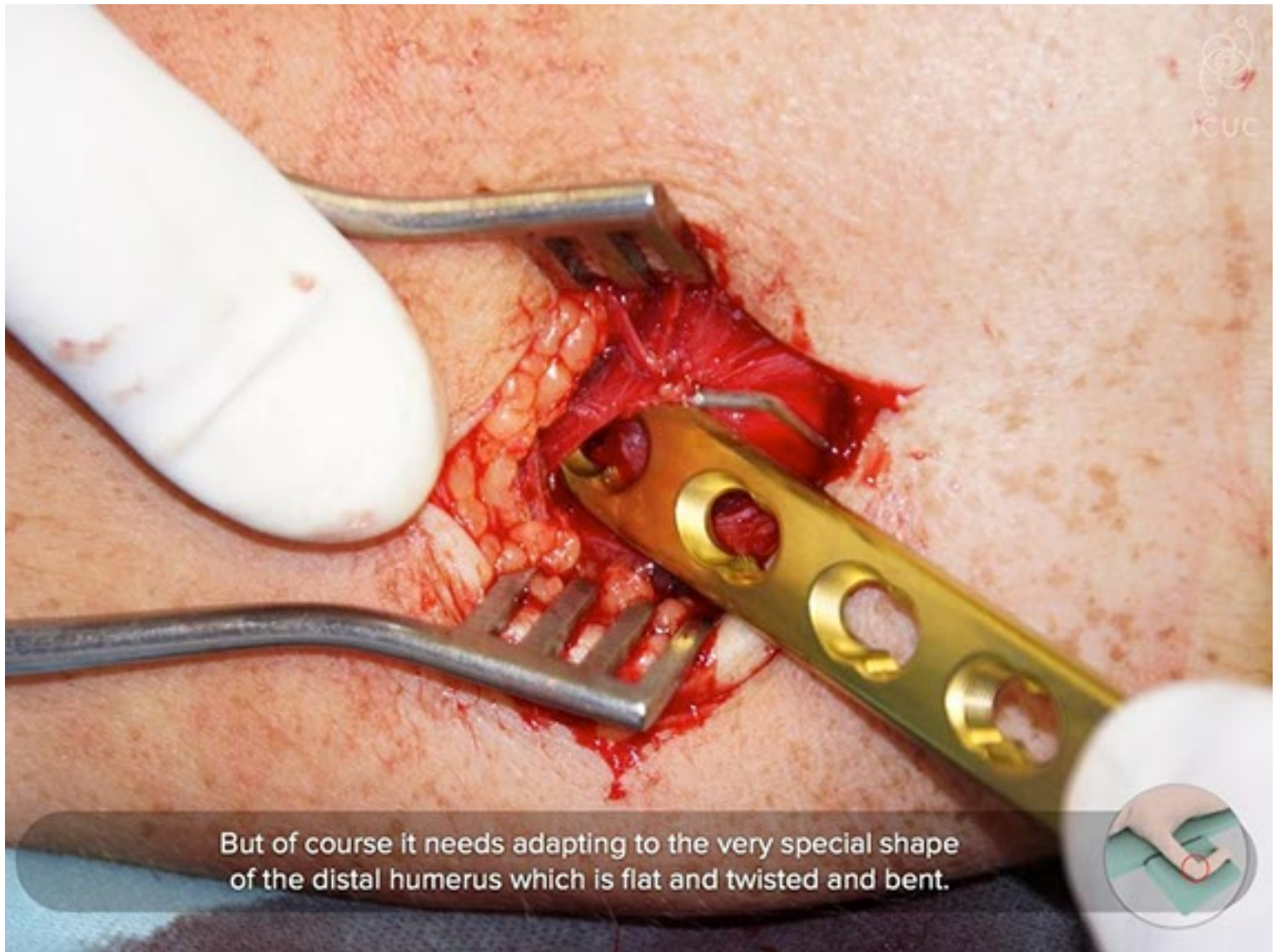
The control, though, that this cerclage bands give is fantastic.




A long 4.5 LC plate is being passed through the windows.

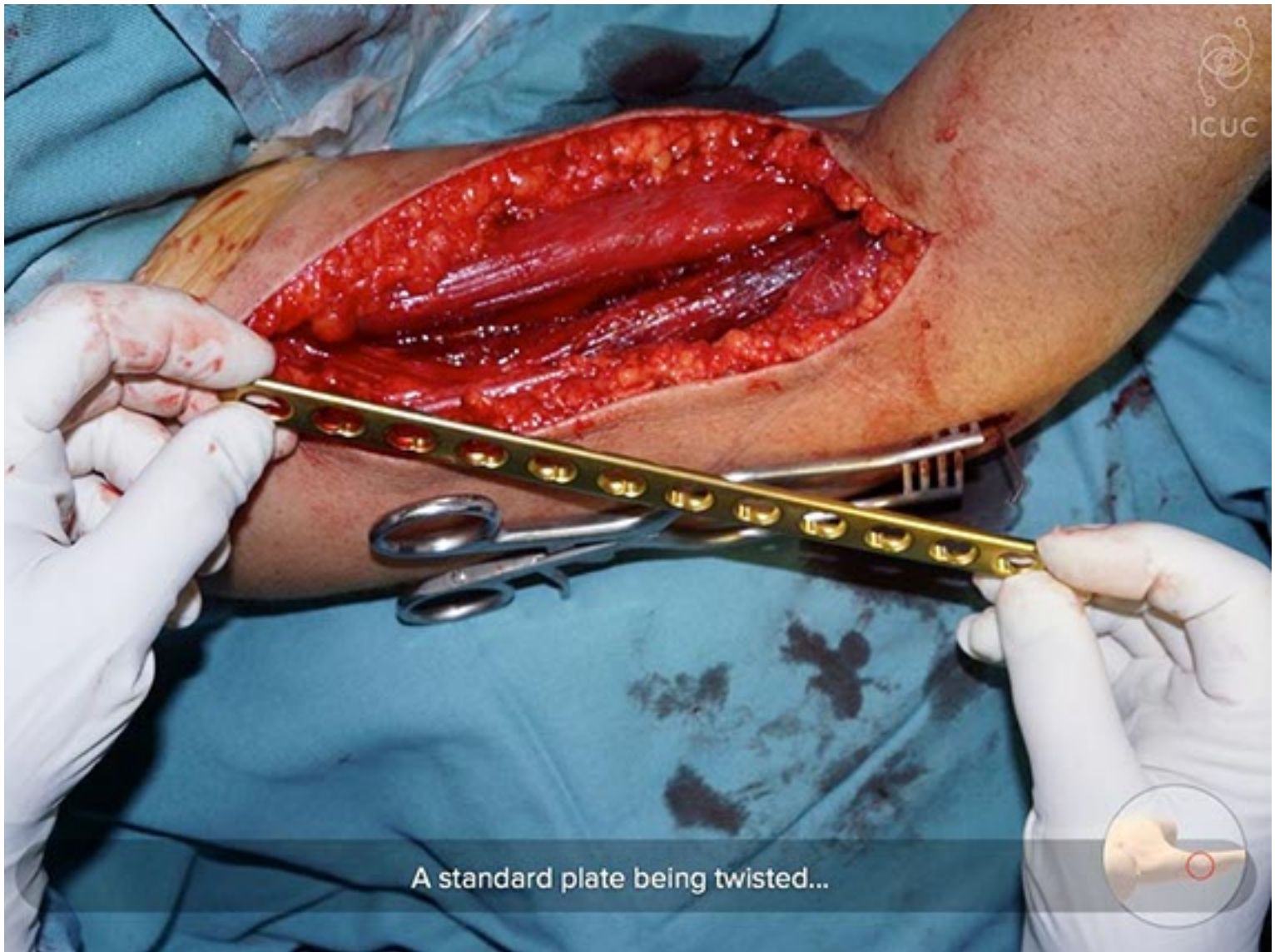




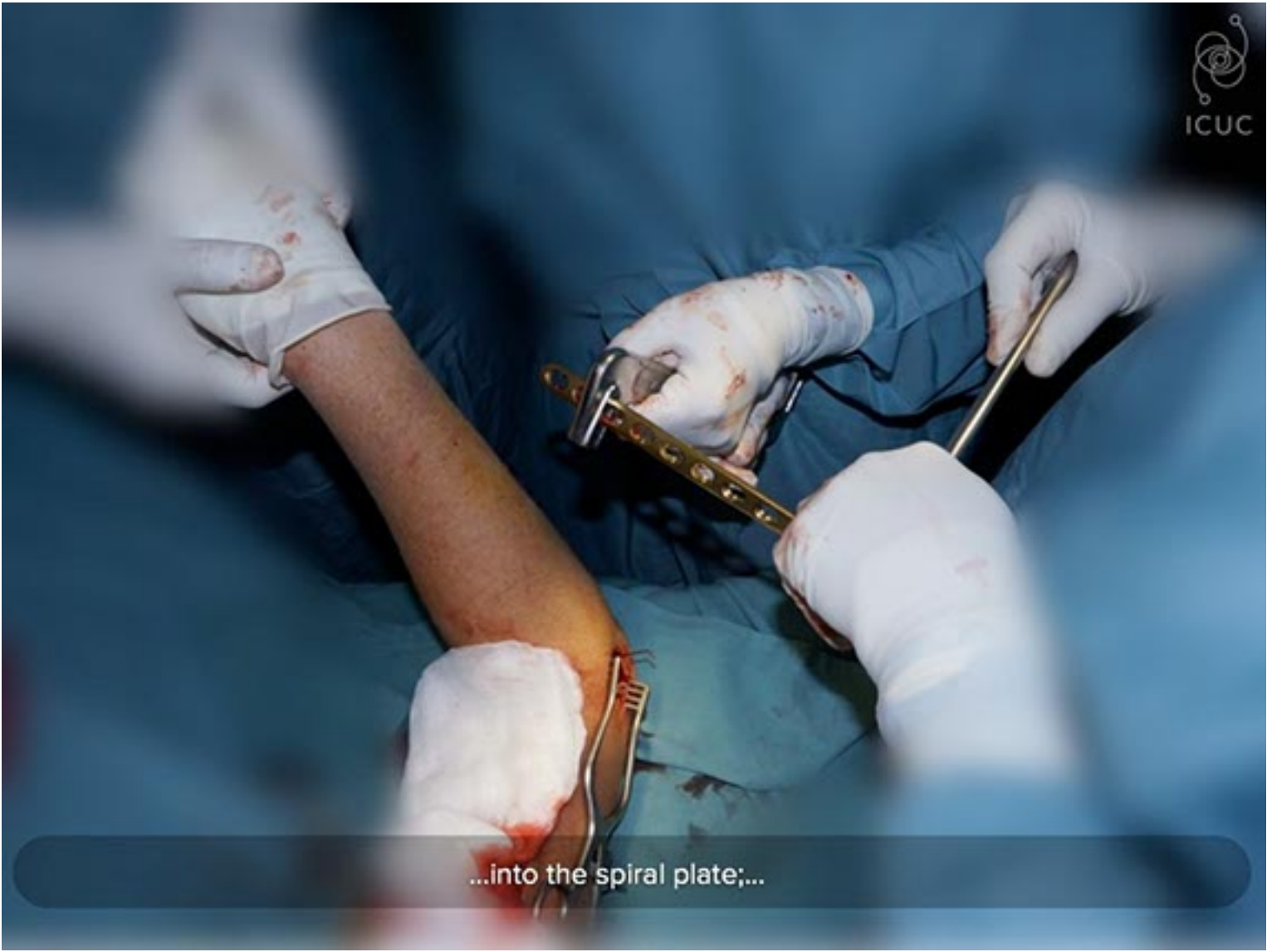


But of course it needs adapting to the very special shape of the distal humerus which is flat and twisted and bent.

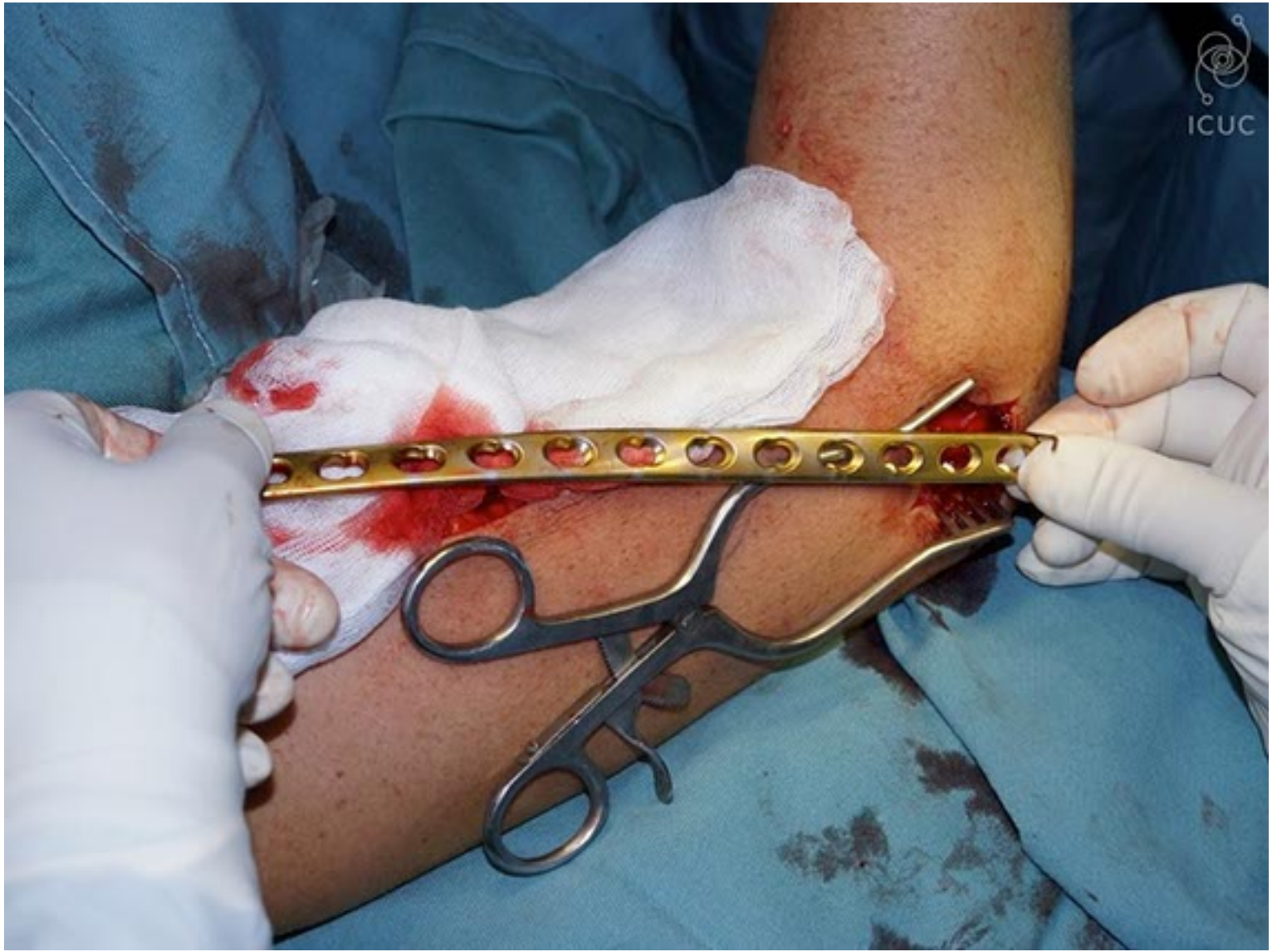

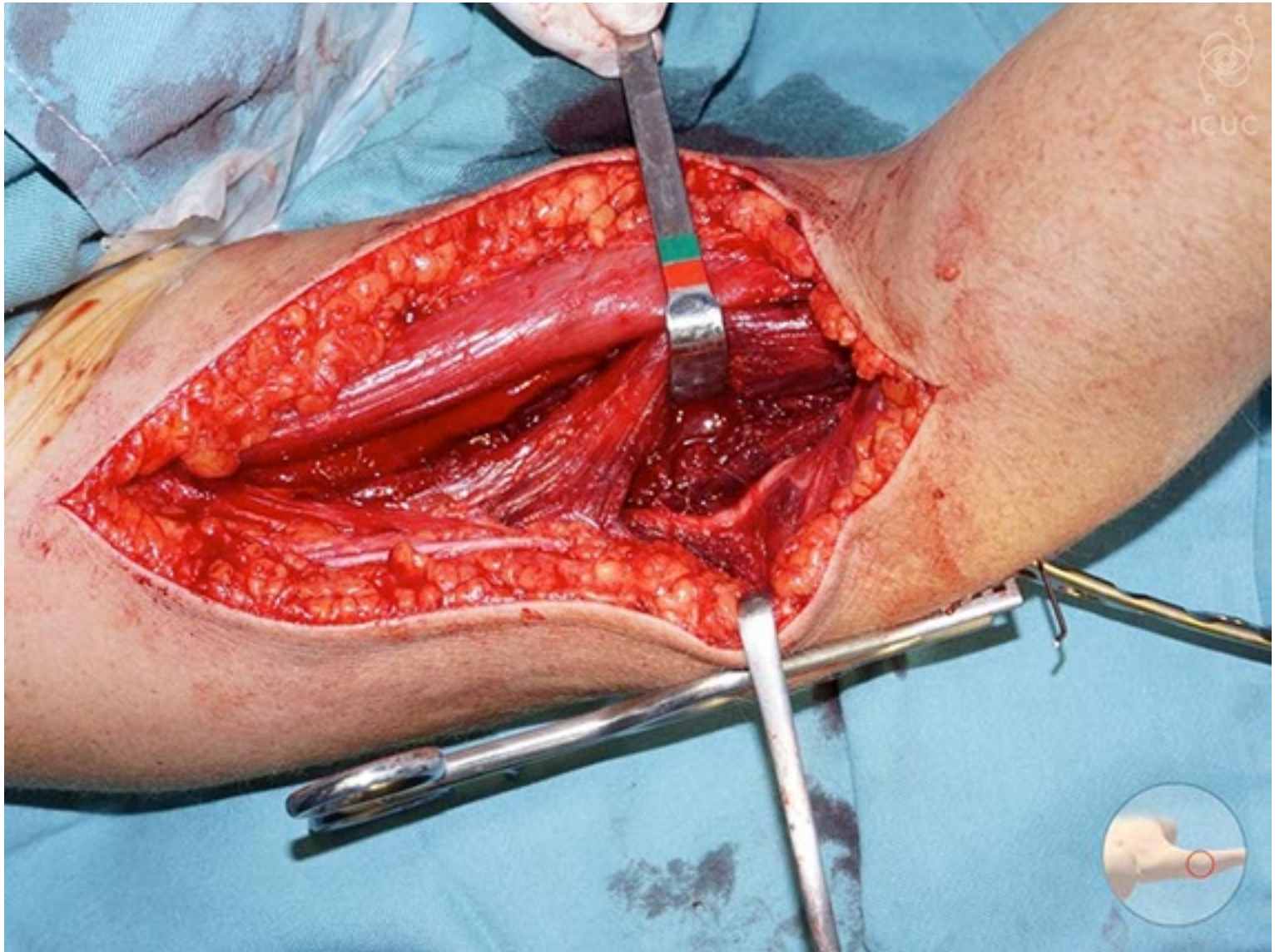


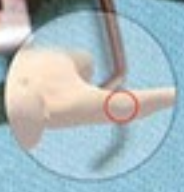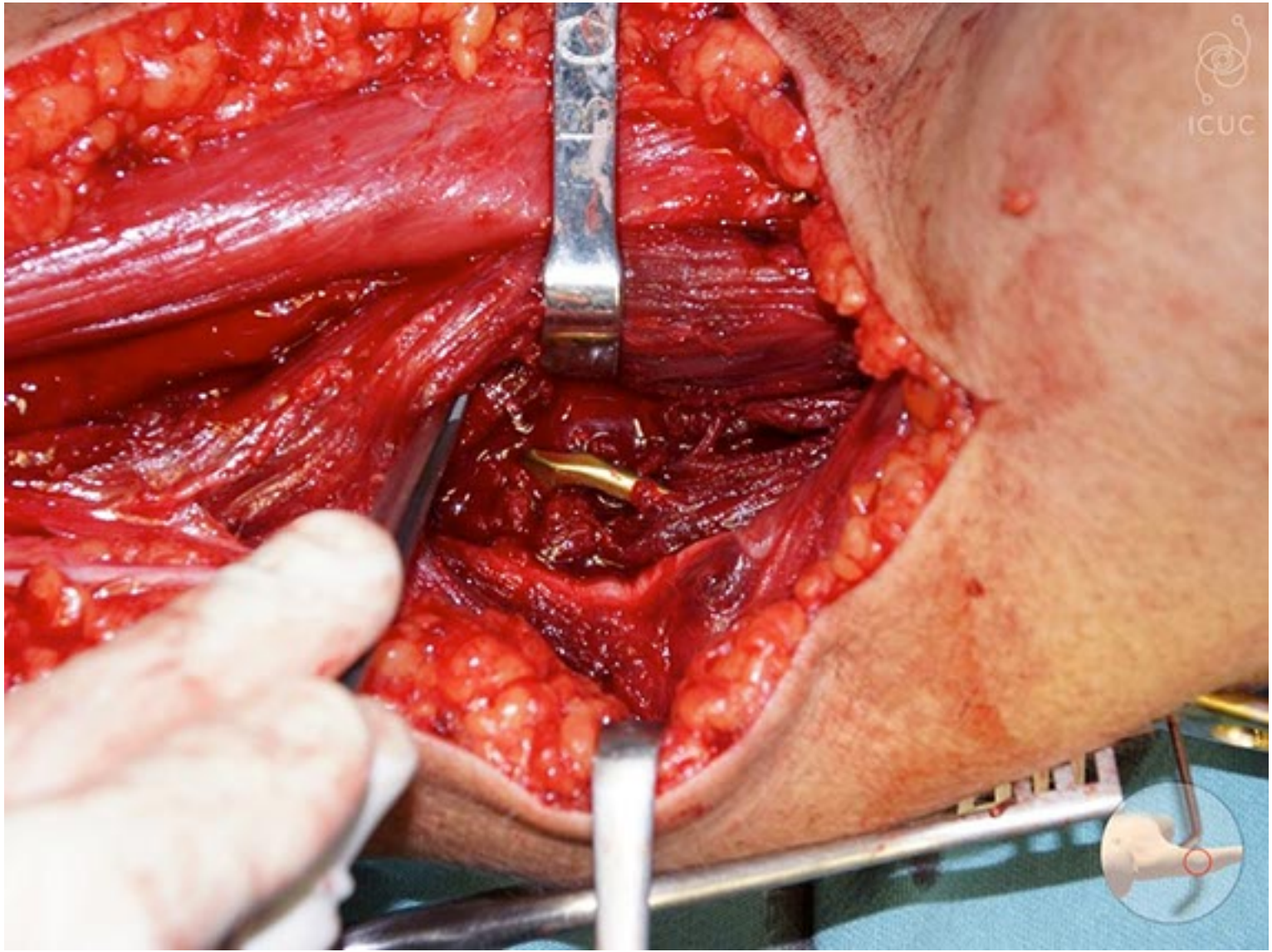
A standard plate being twisted...

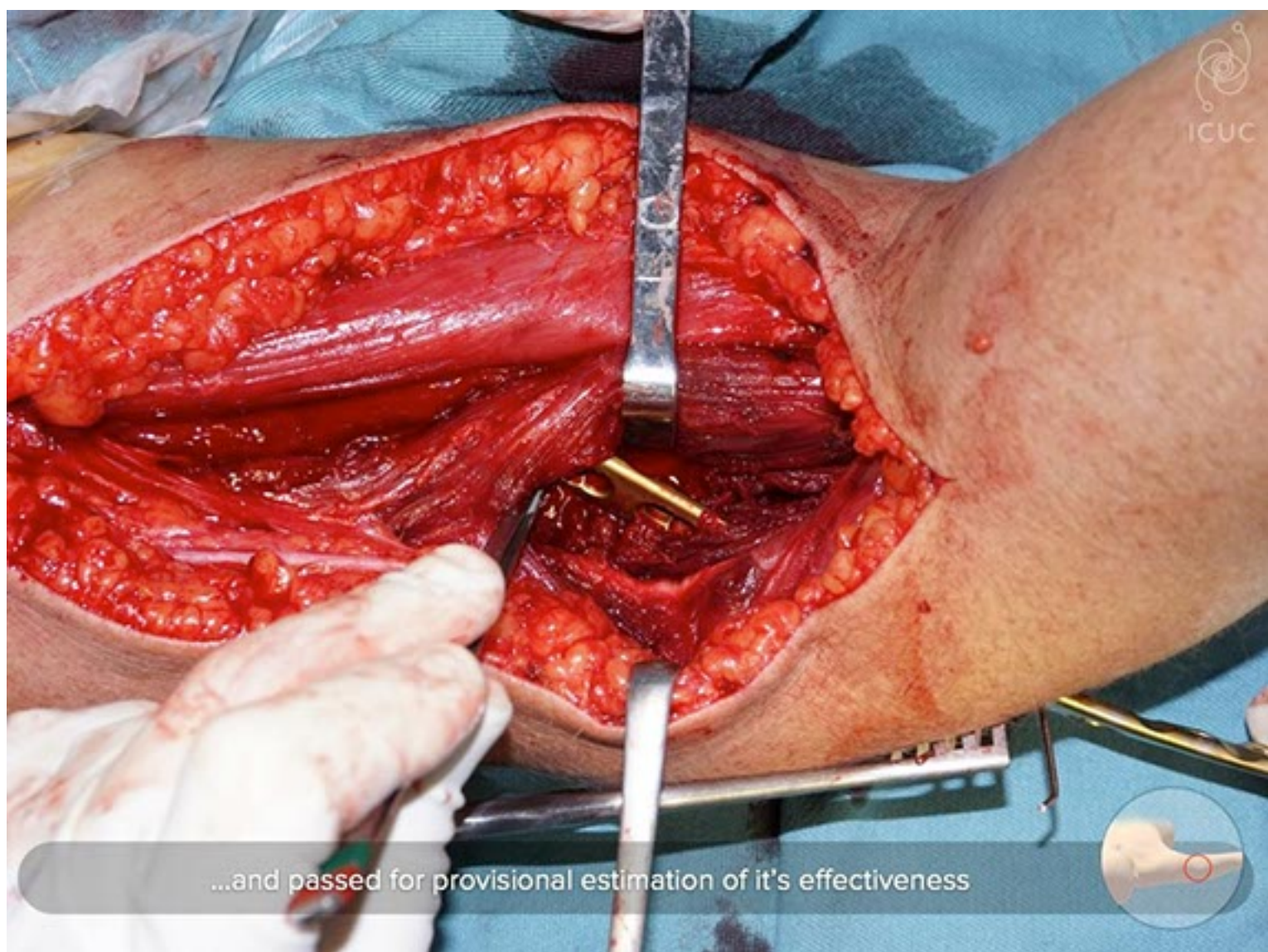


...into the spiral plate;...

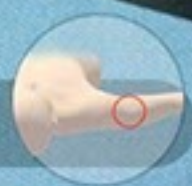

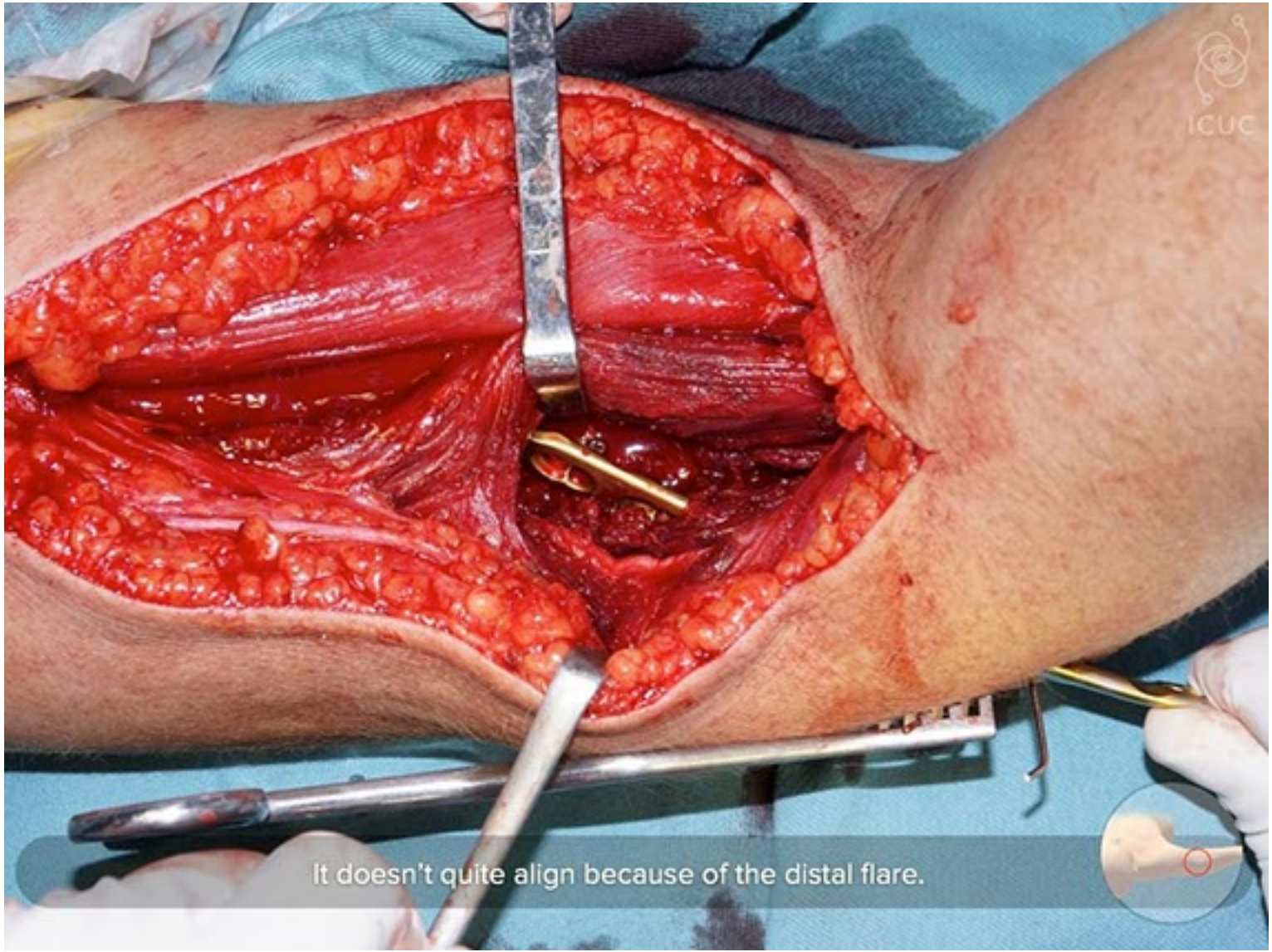





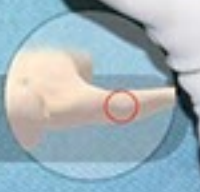
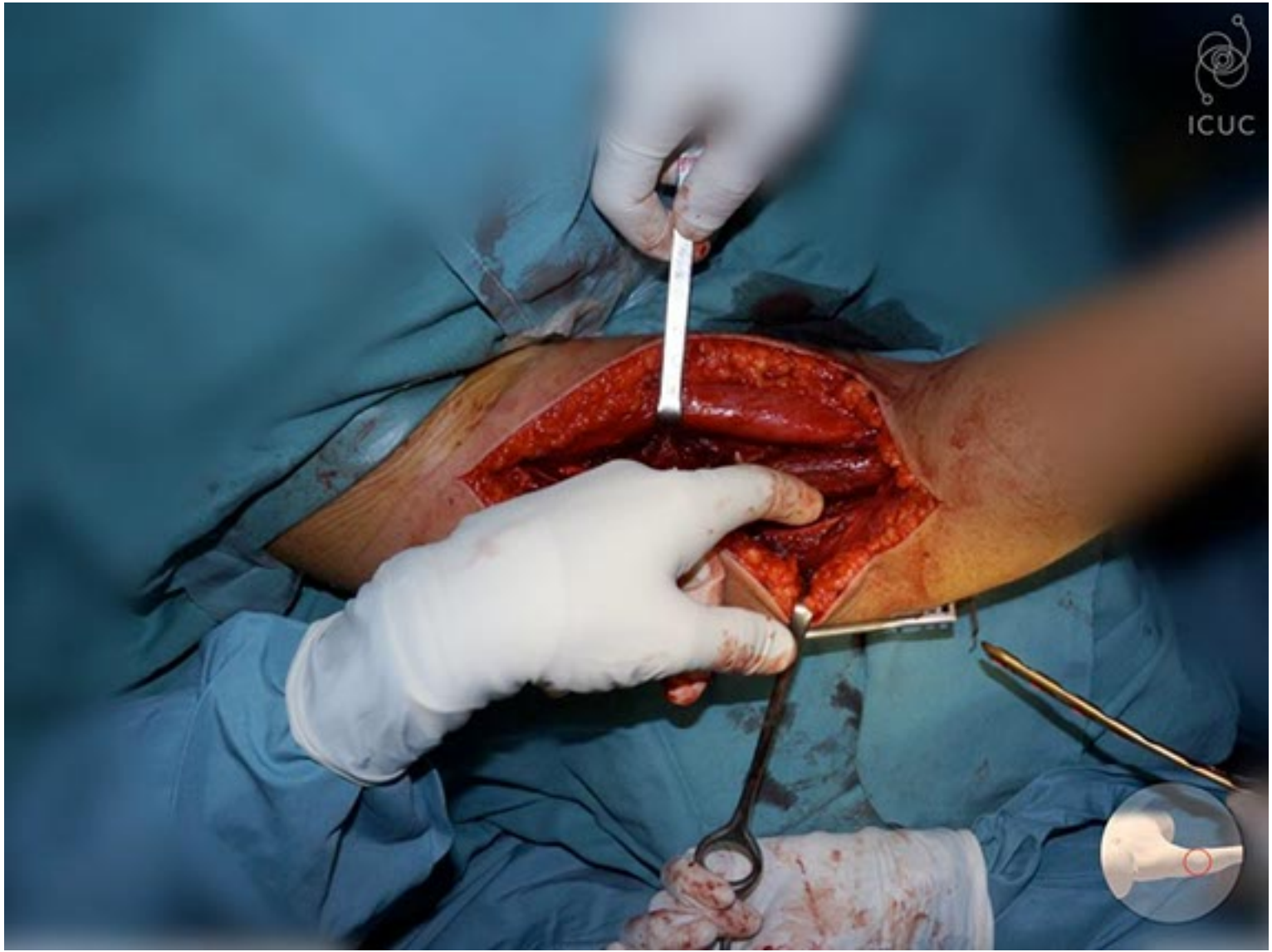...and passed for provisional estimation of it's effectiveness

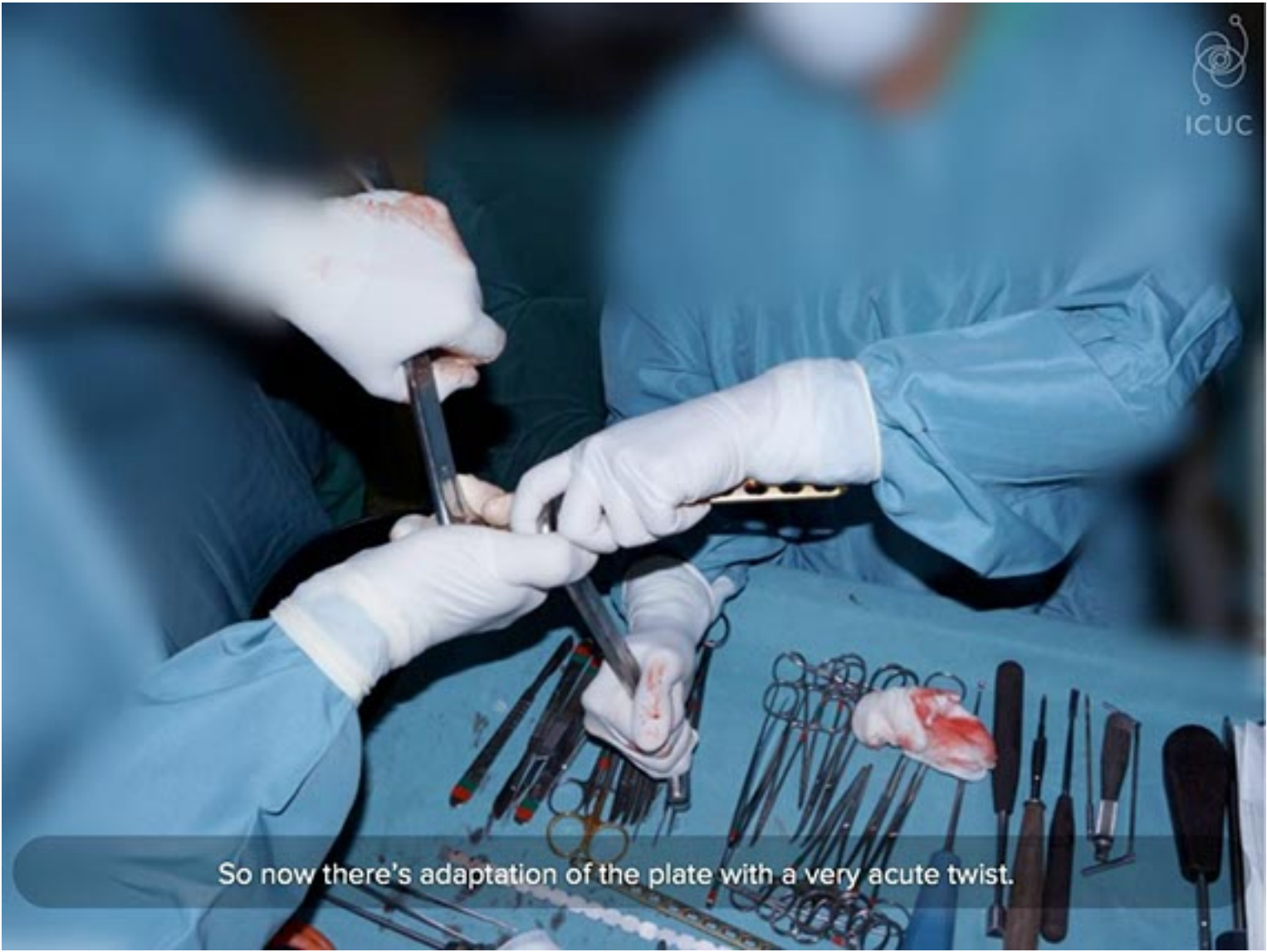




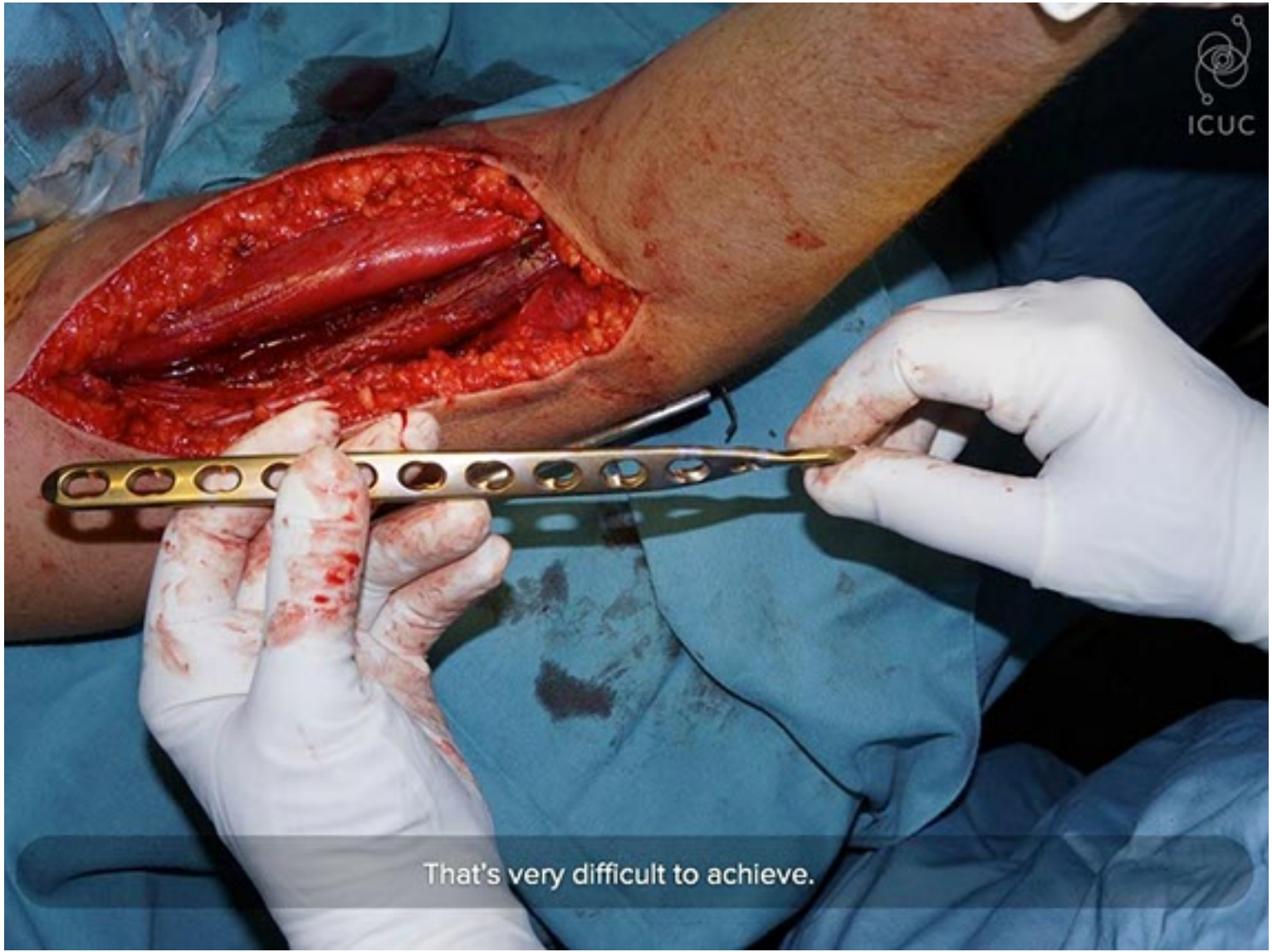
It doesn't quite align because of the distal flare.



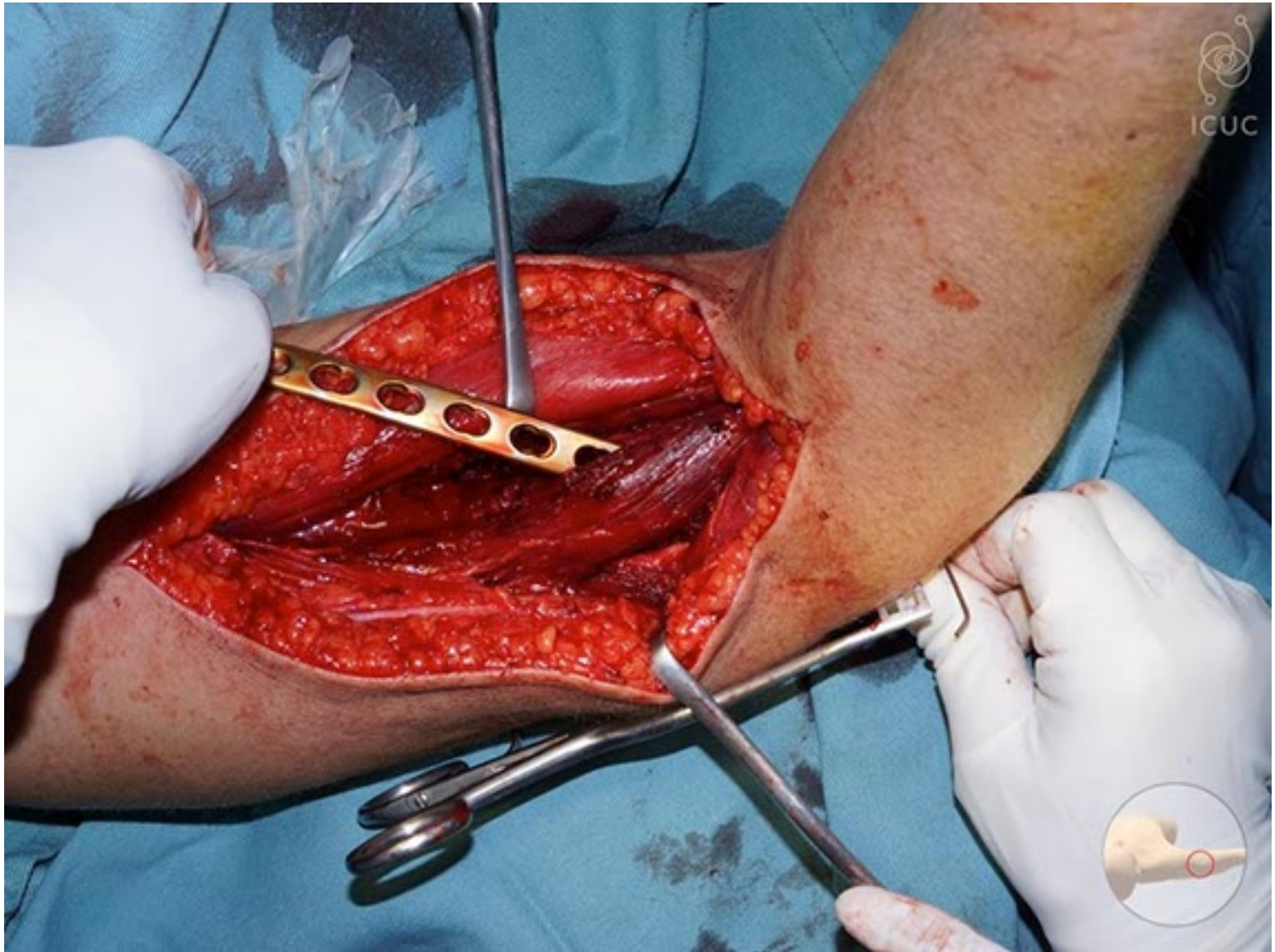


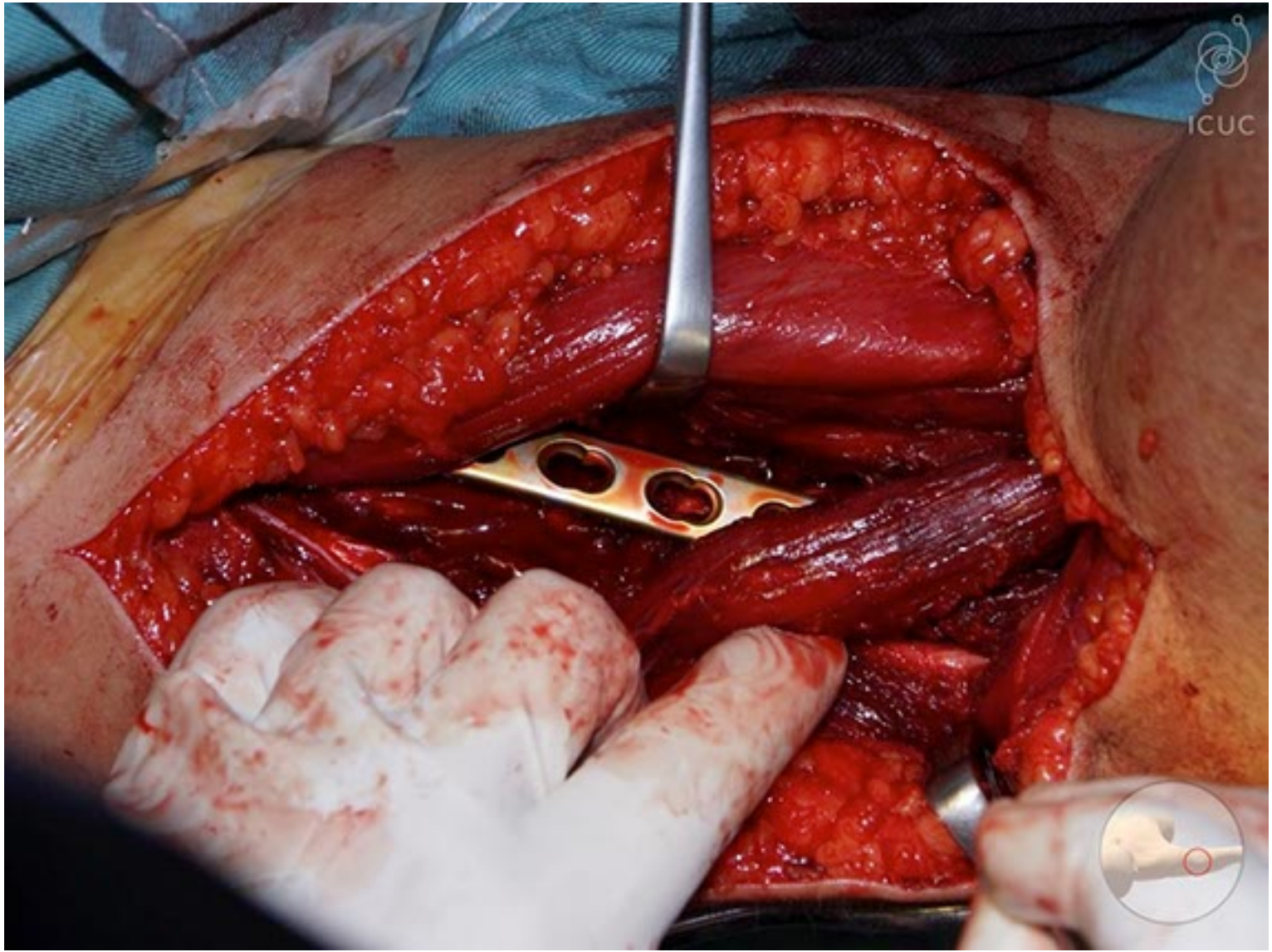


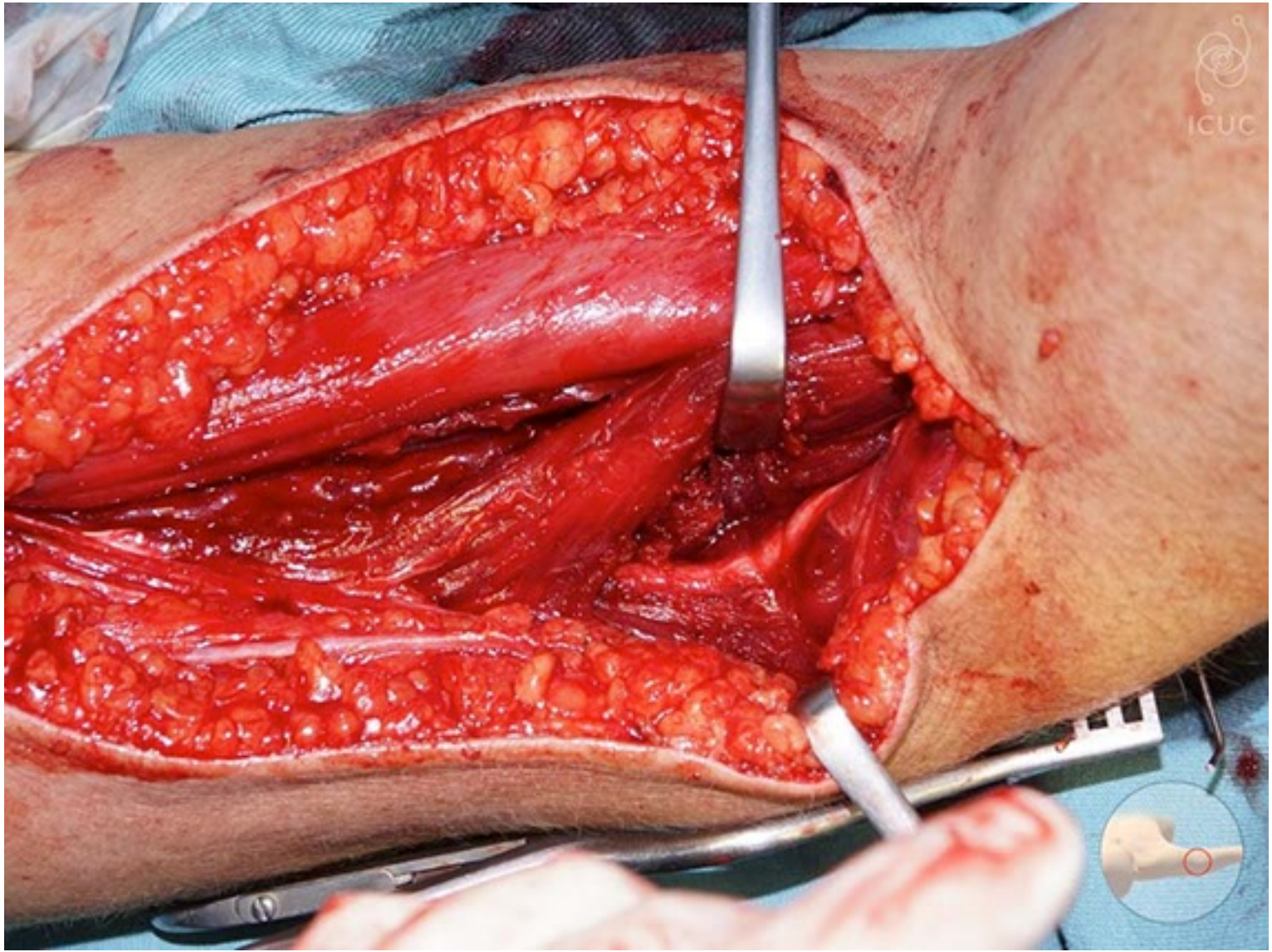
So now there's adaptation of the plate with a very acute twist.

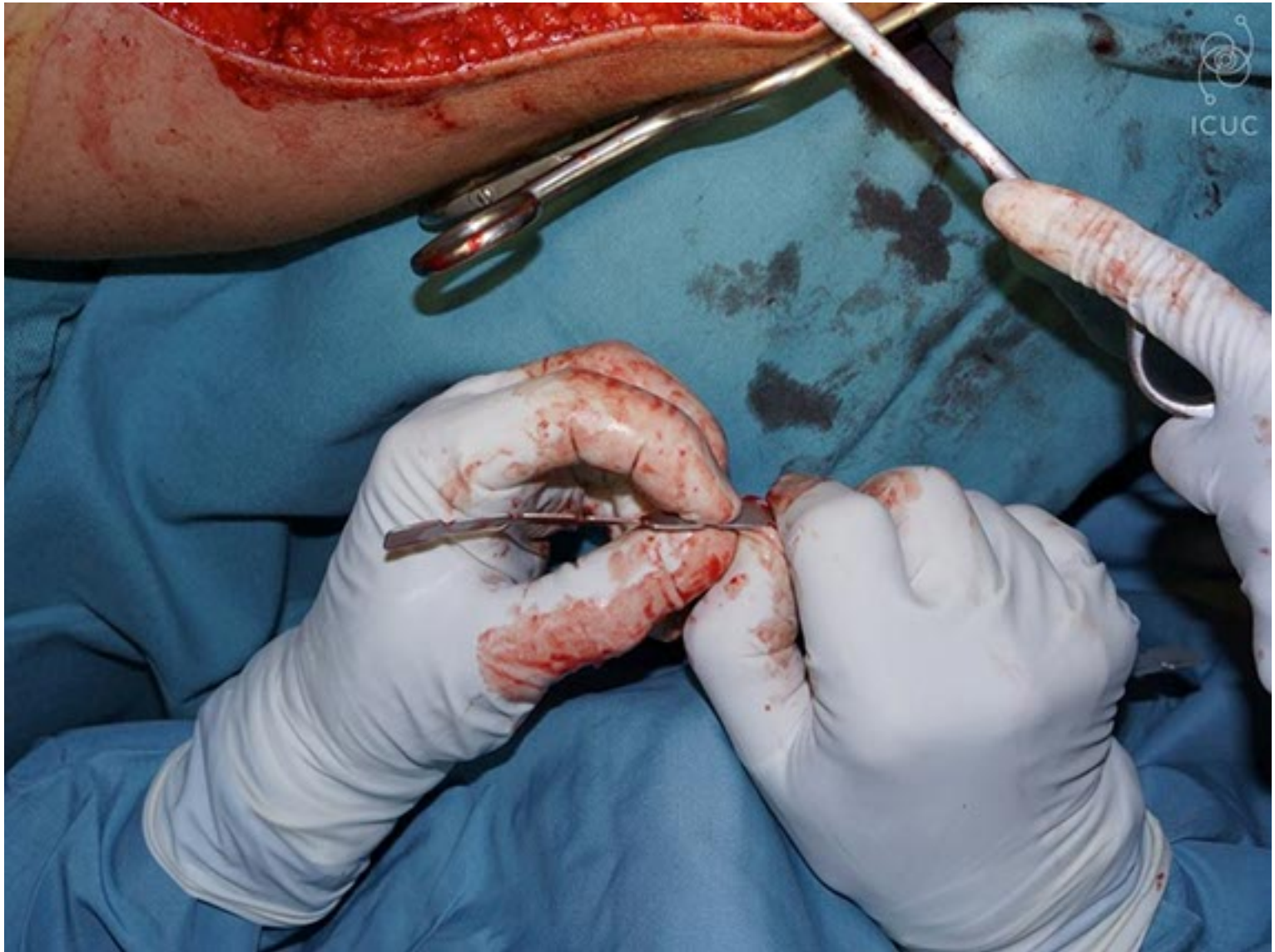

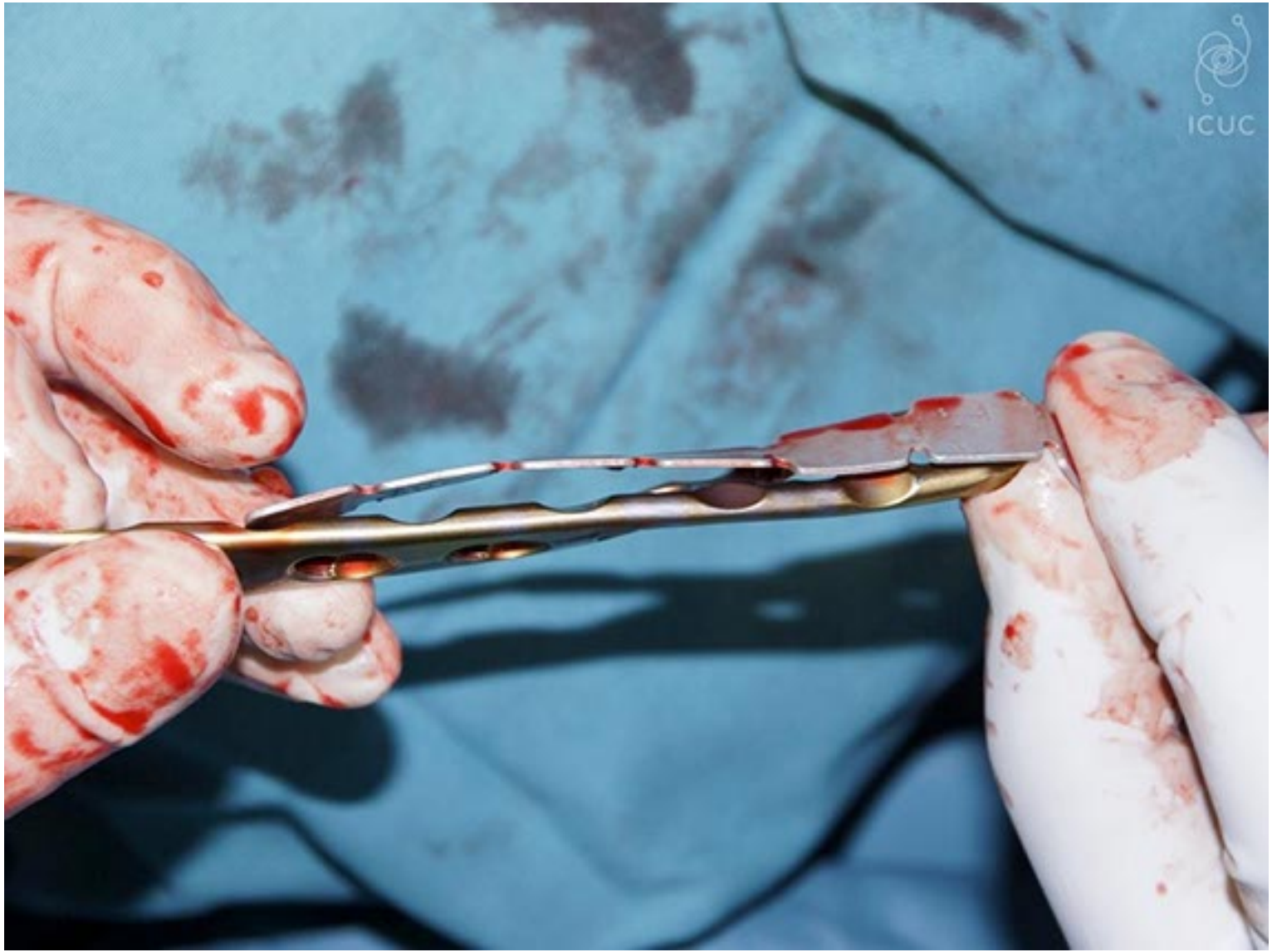That's very difficult to achieve.



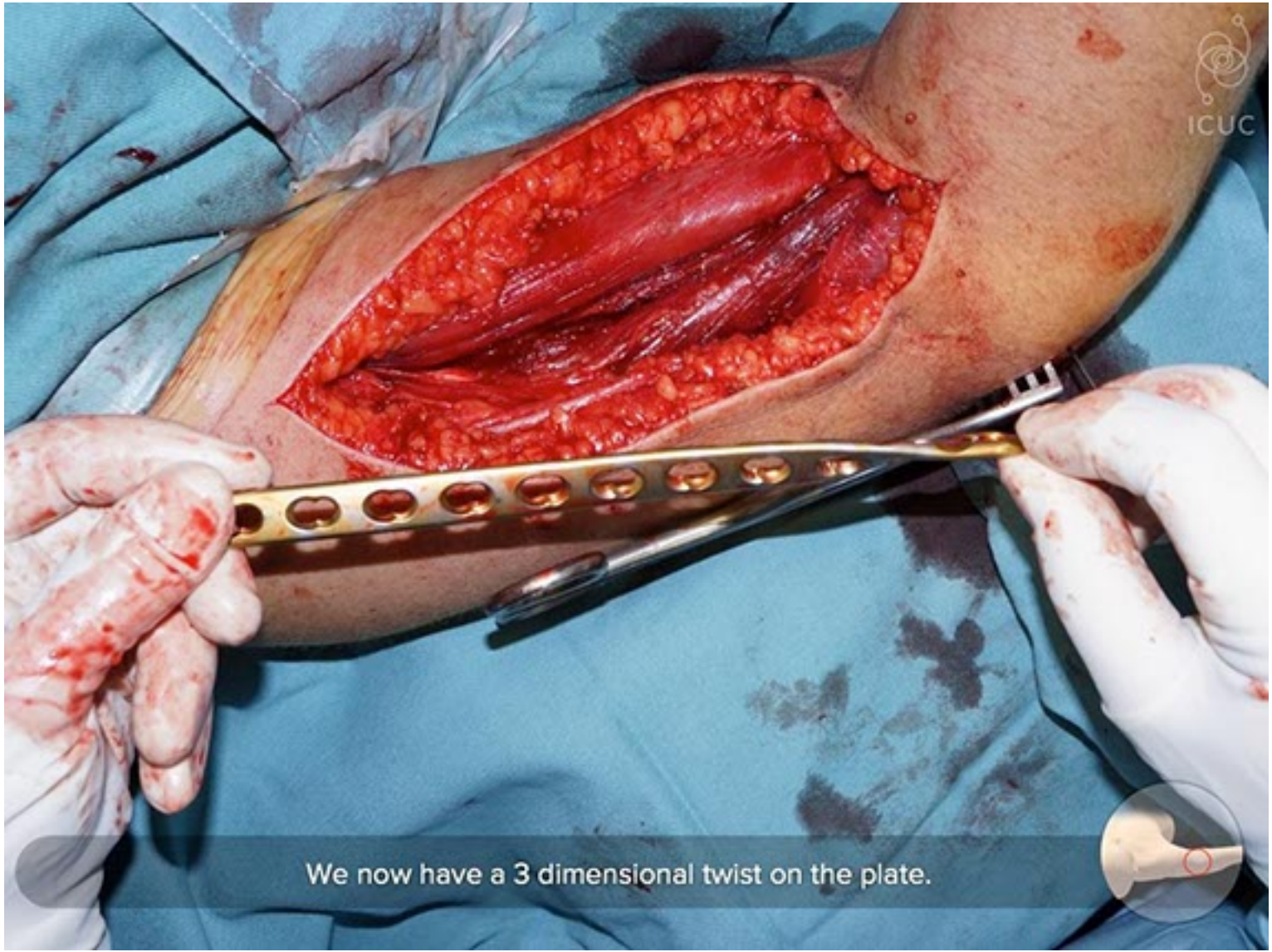




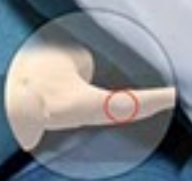

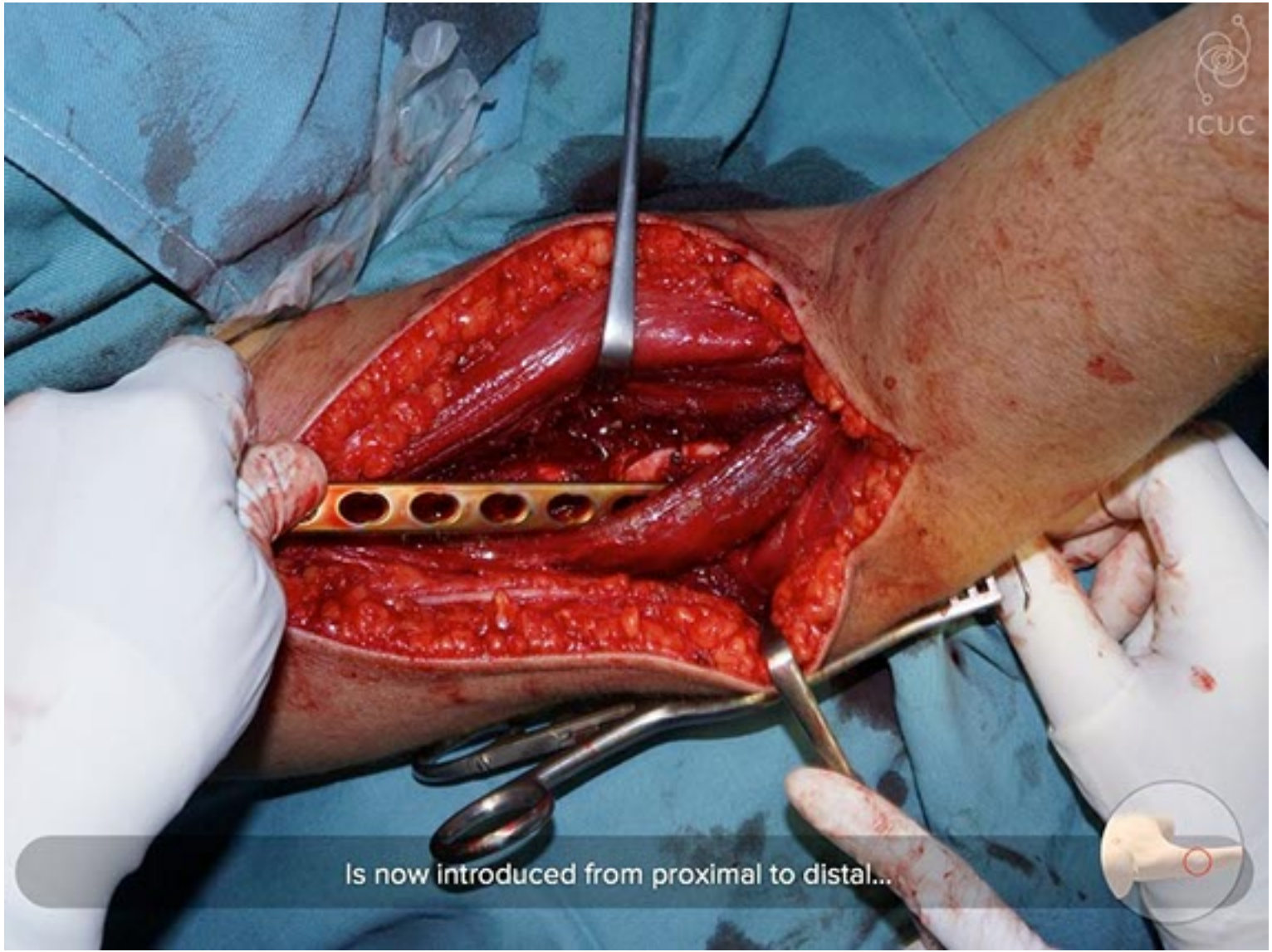





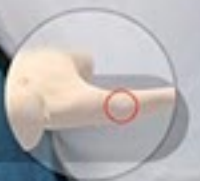
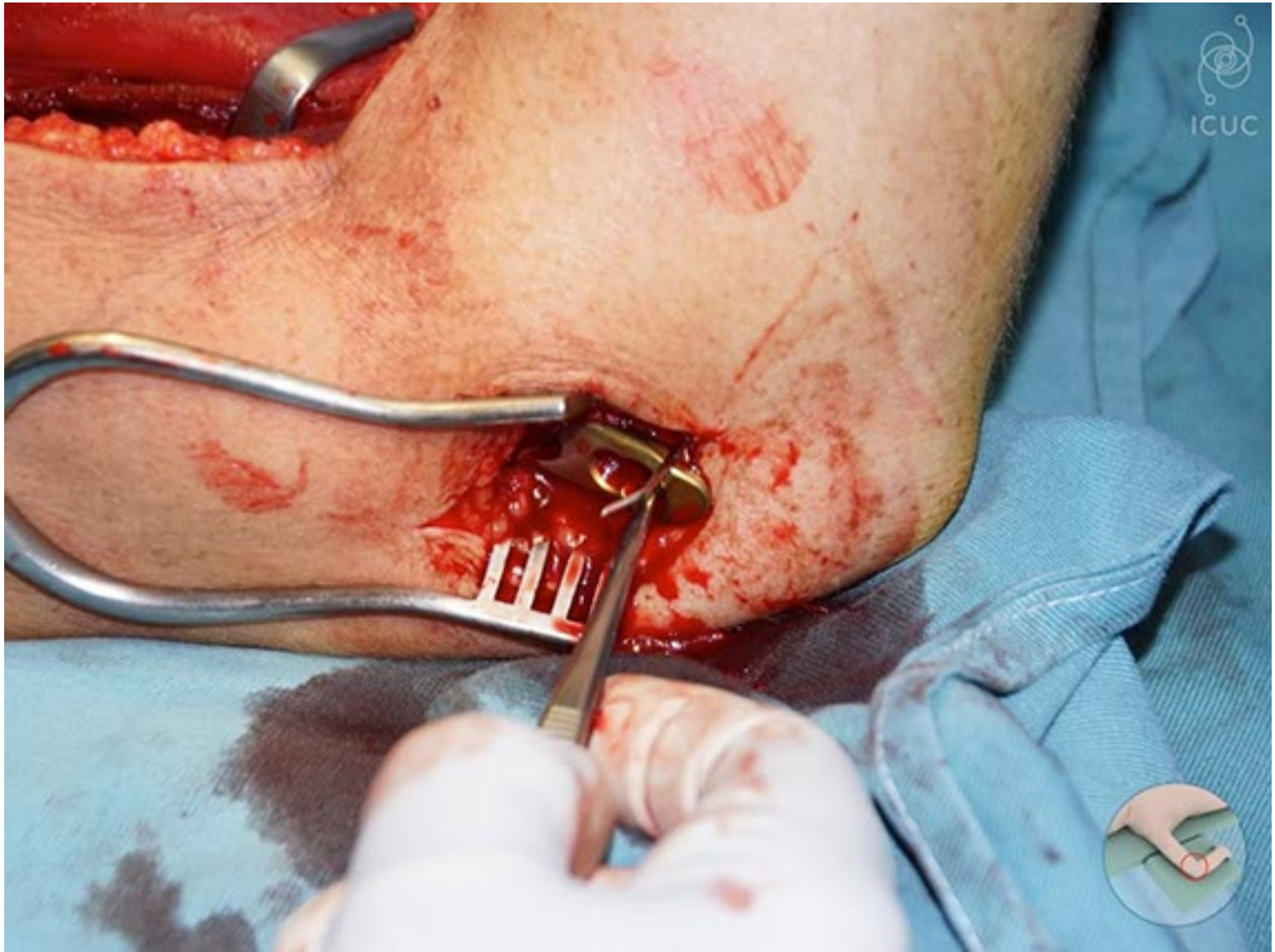We now have a 3 dimensional twist on the plate.

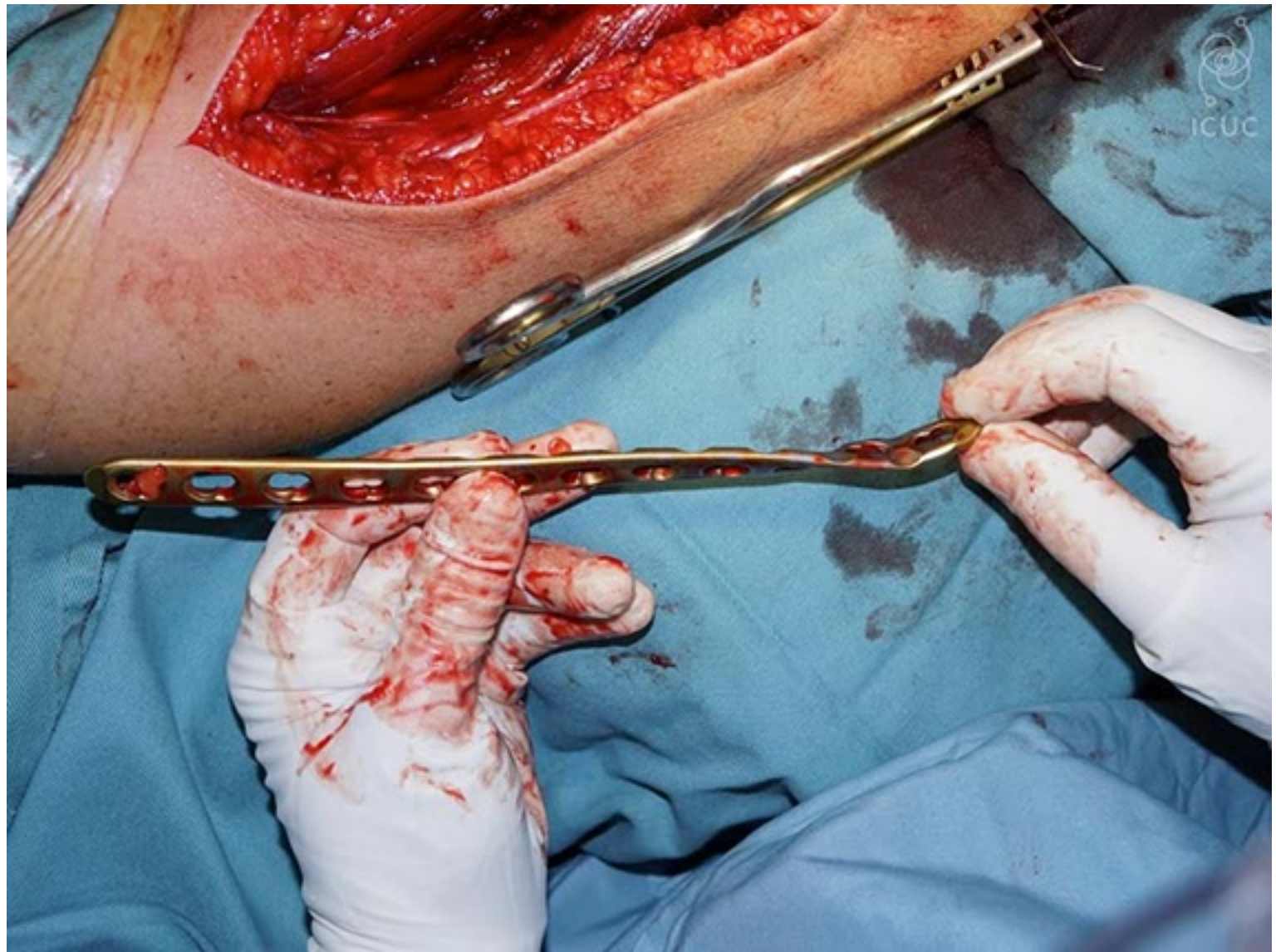


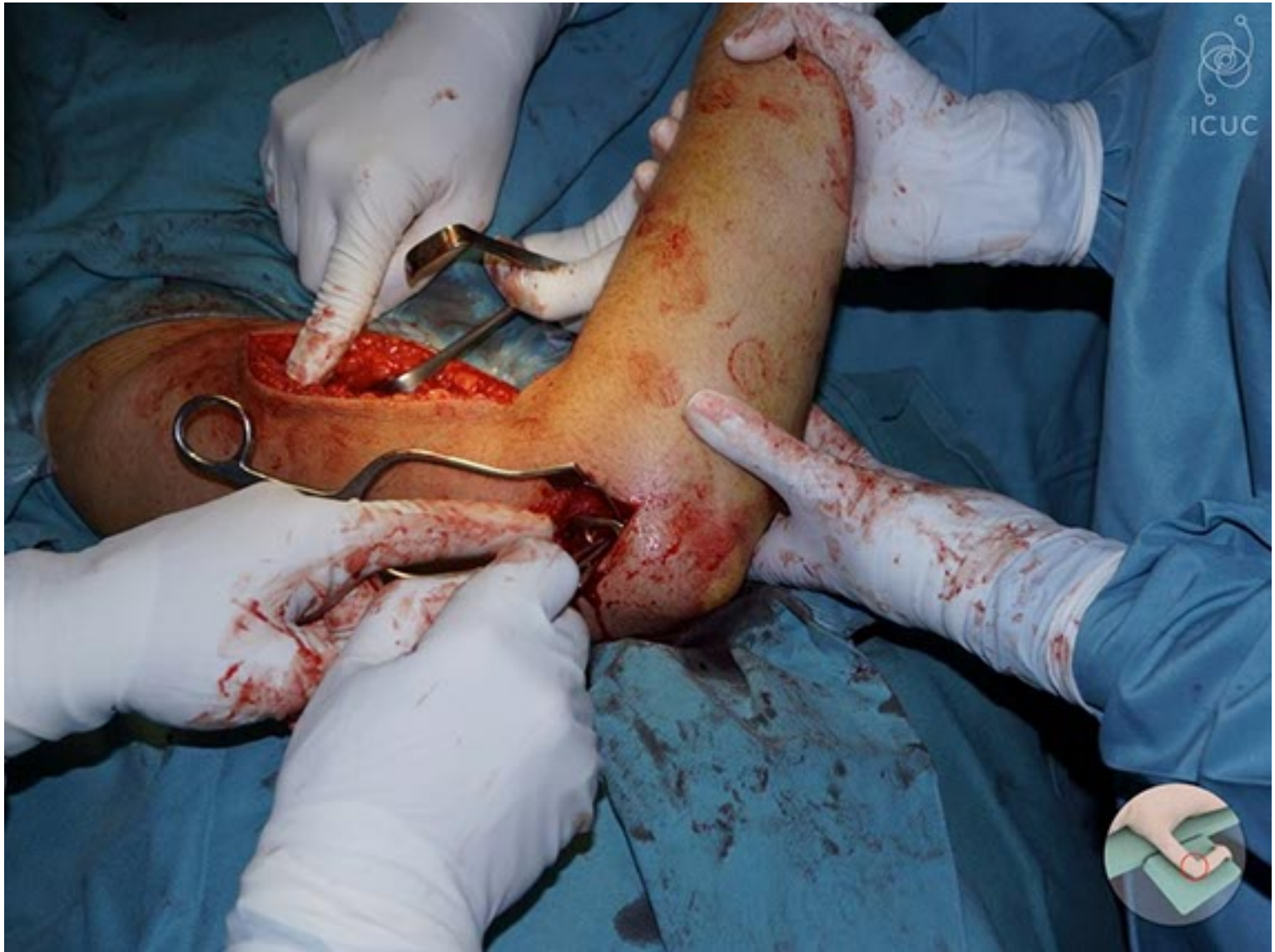

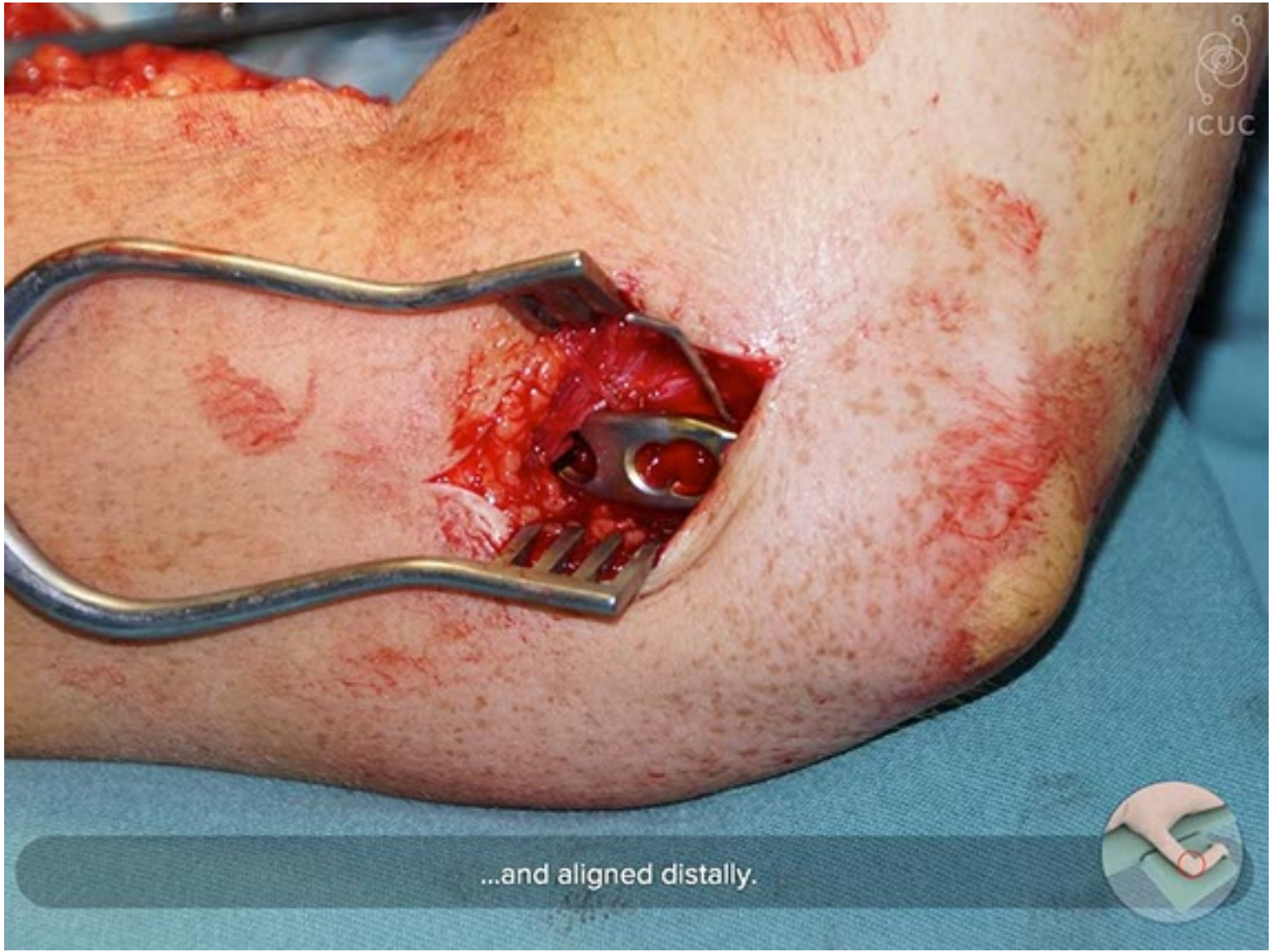
Is now introduced from proximal to distal...



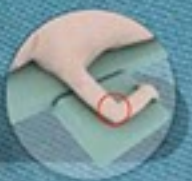

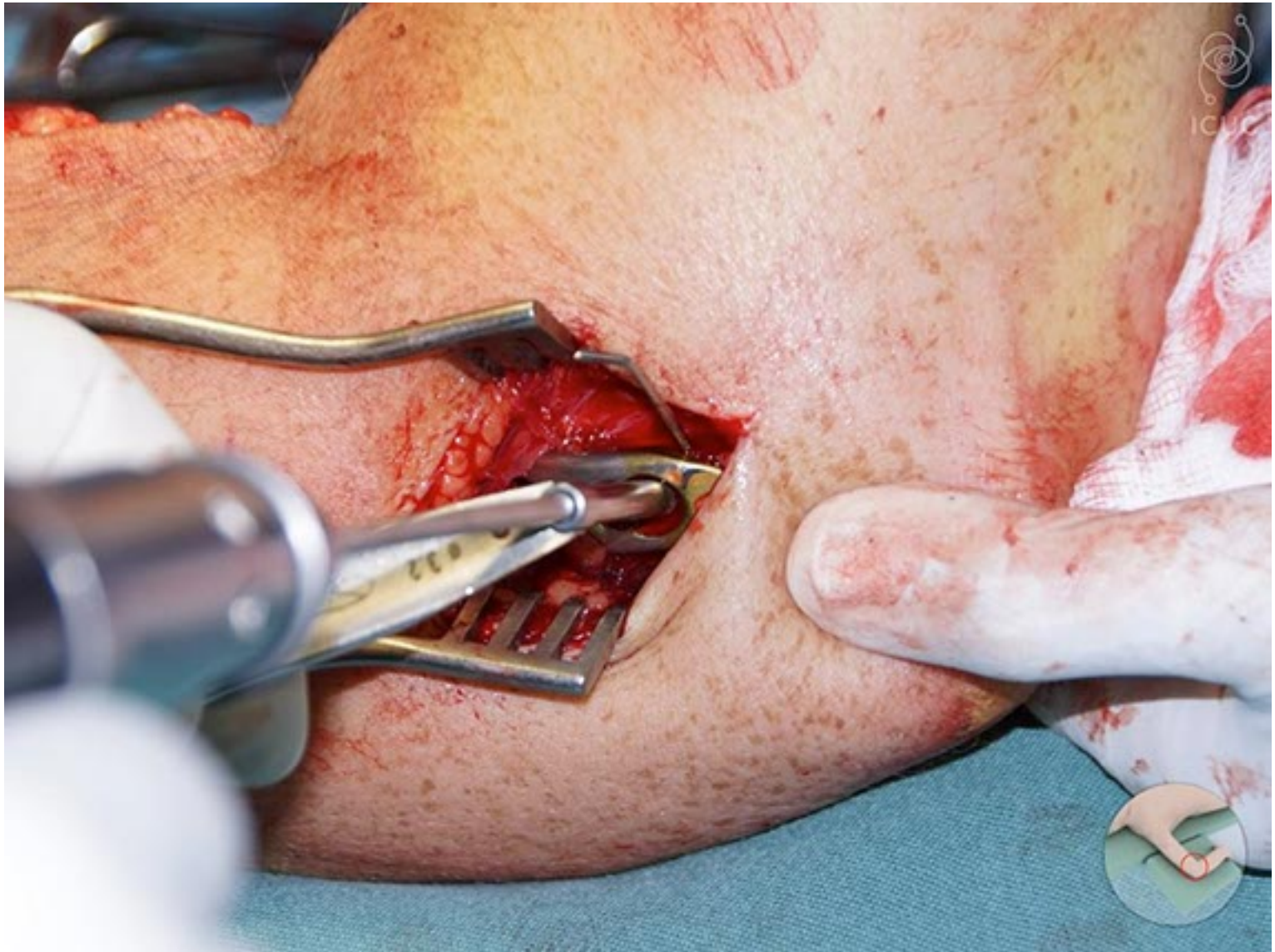


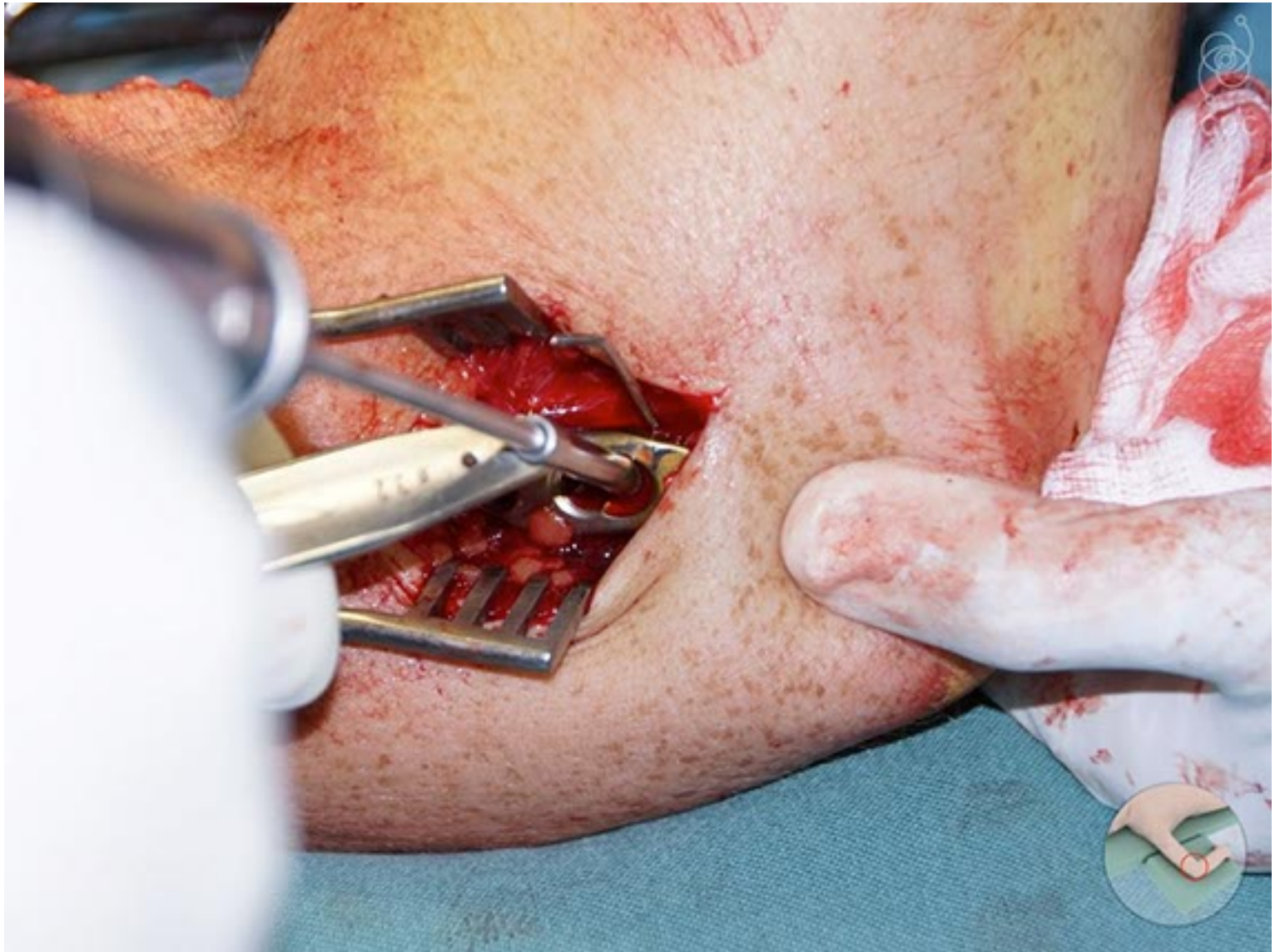


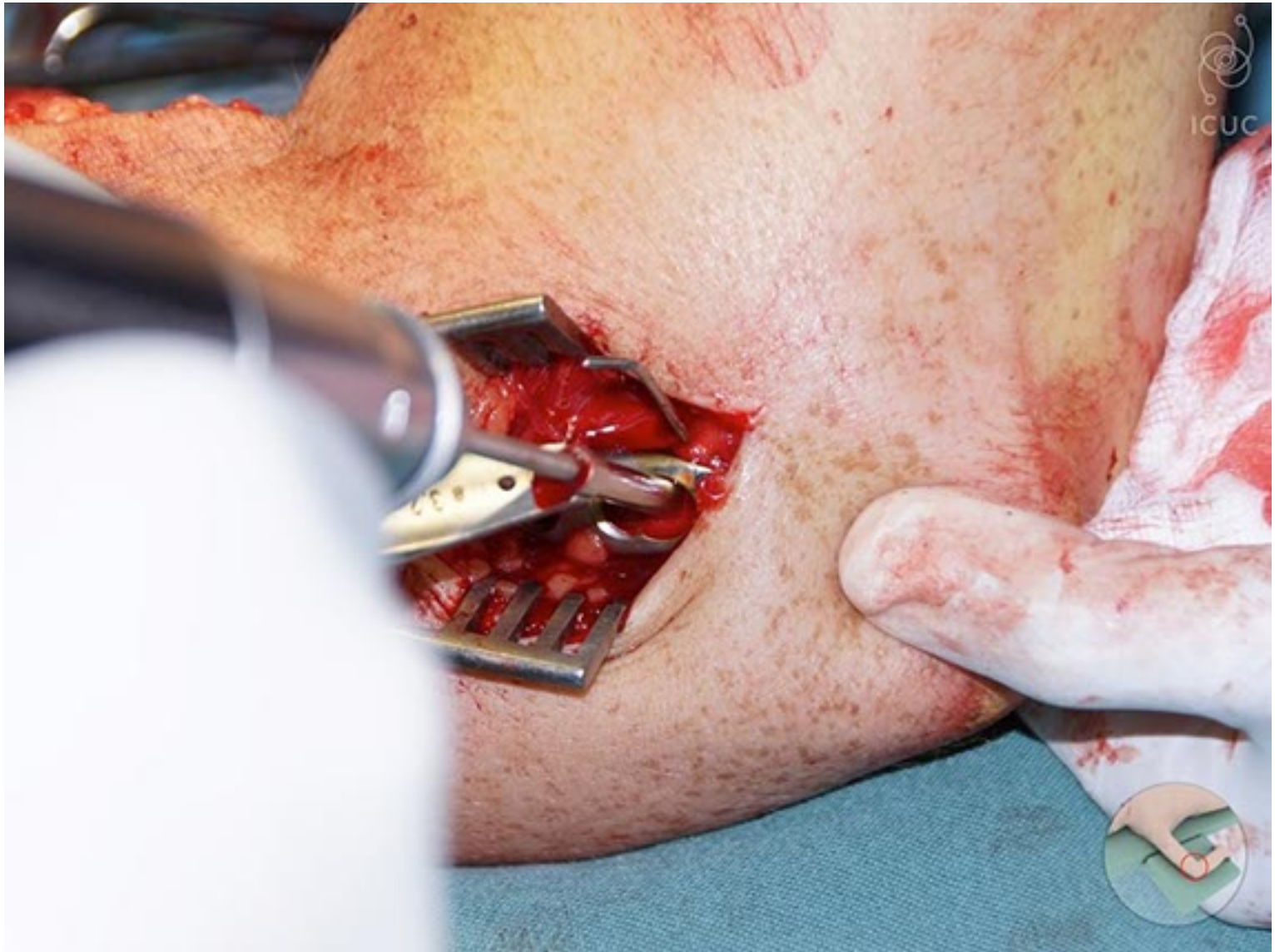


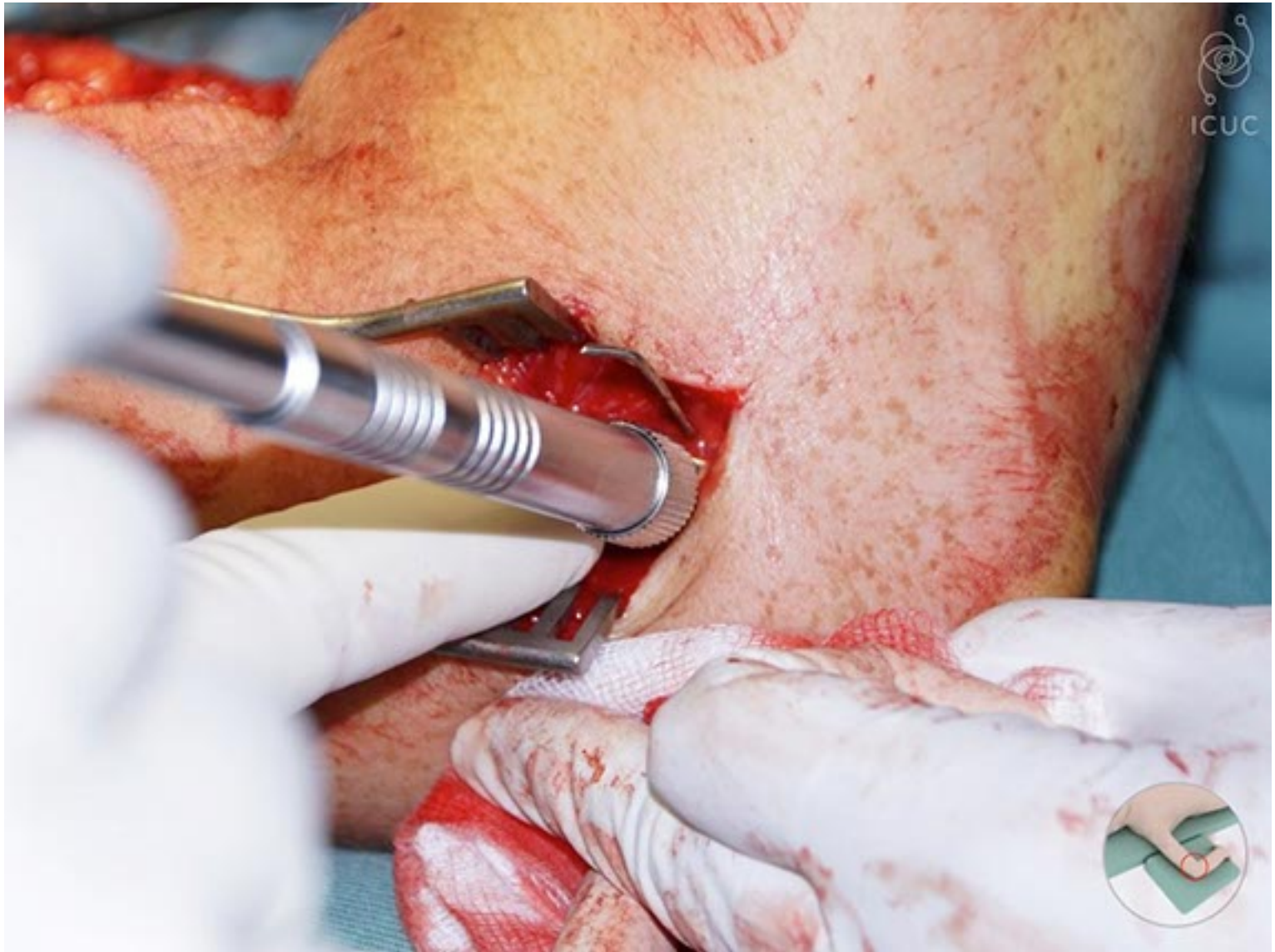...and aligned distally.

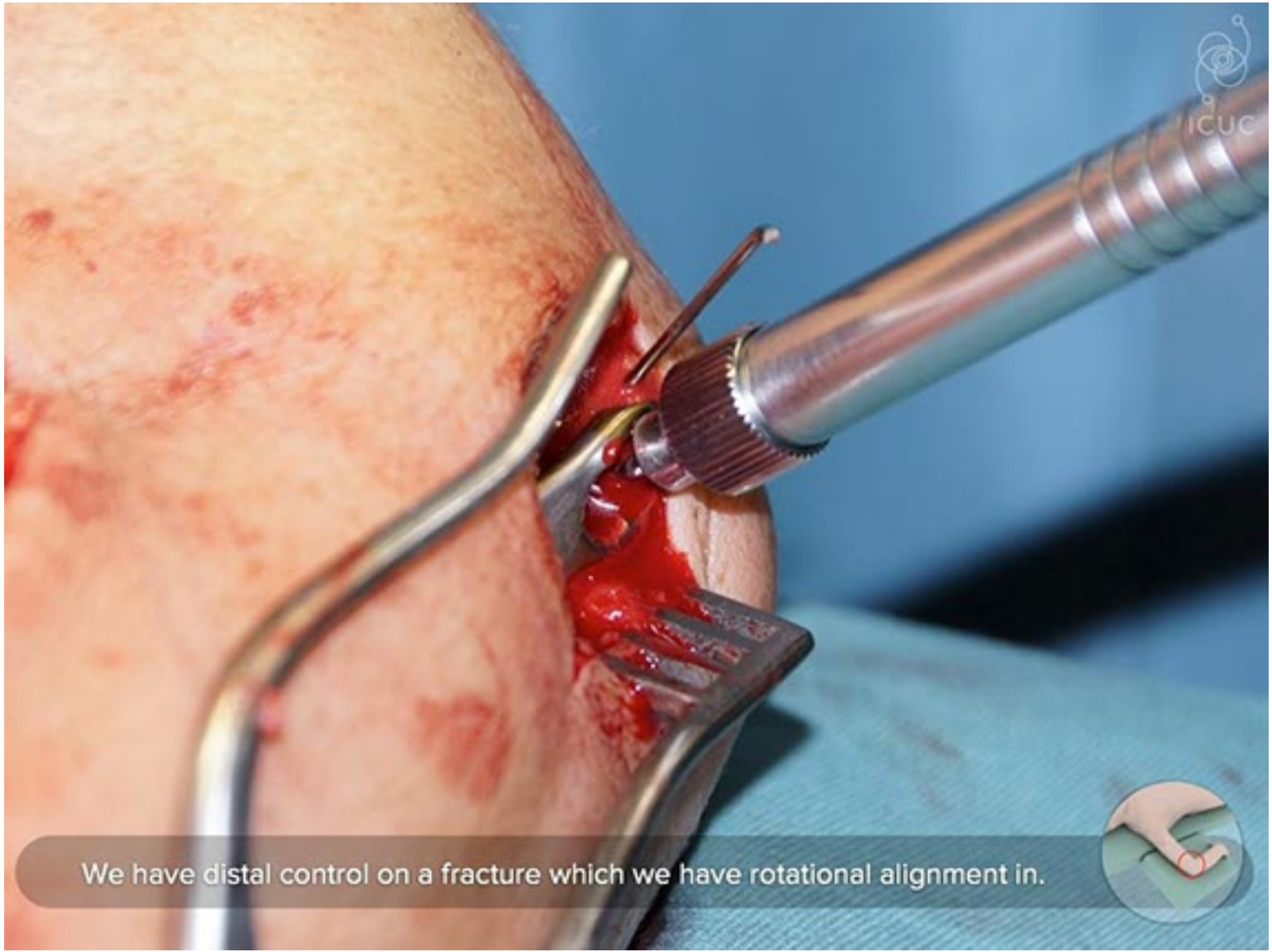






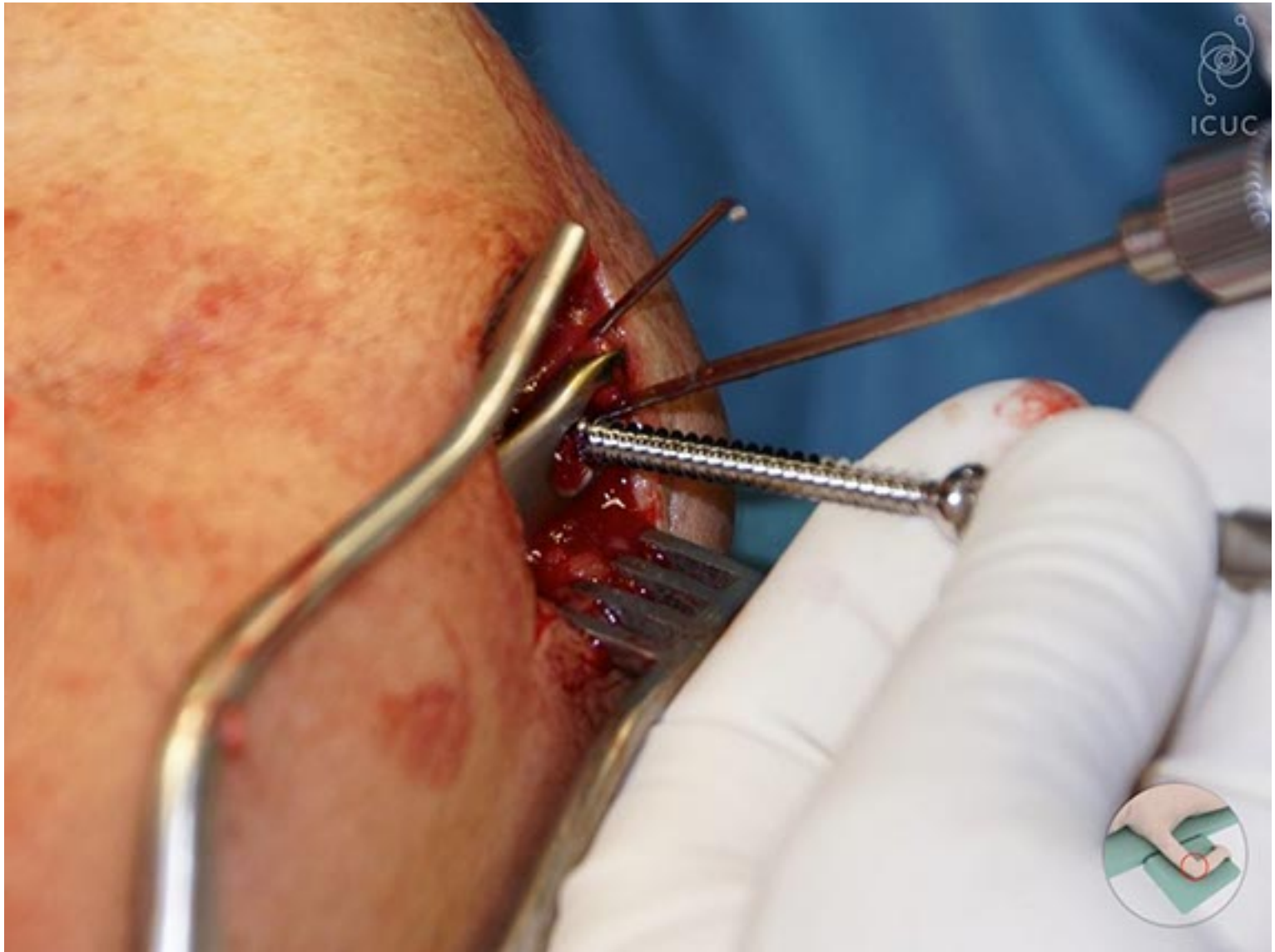
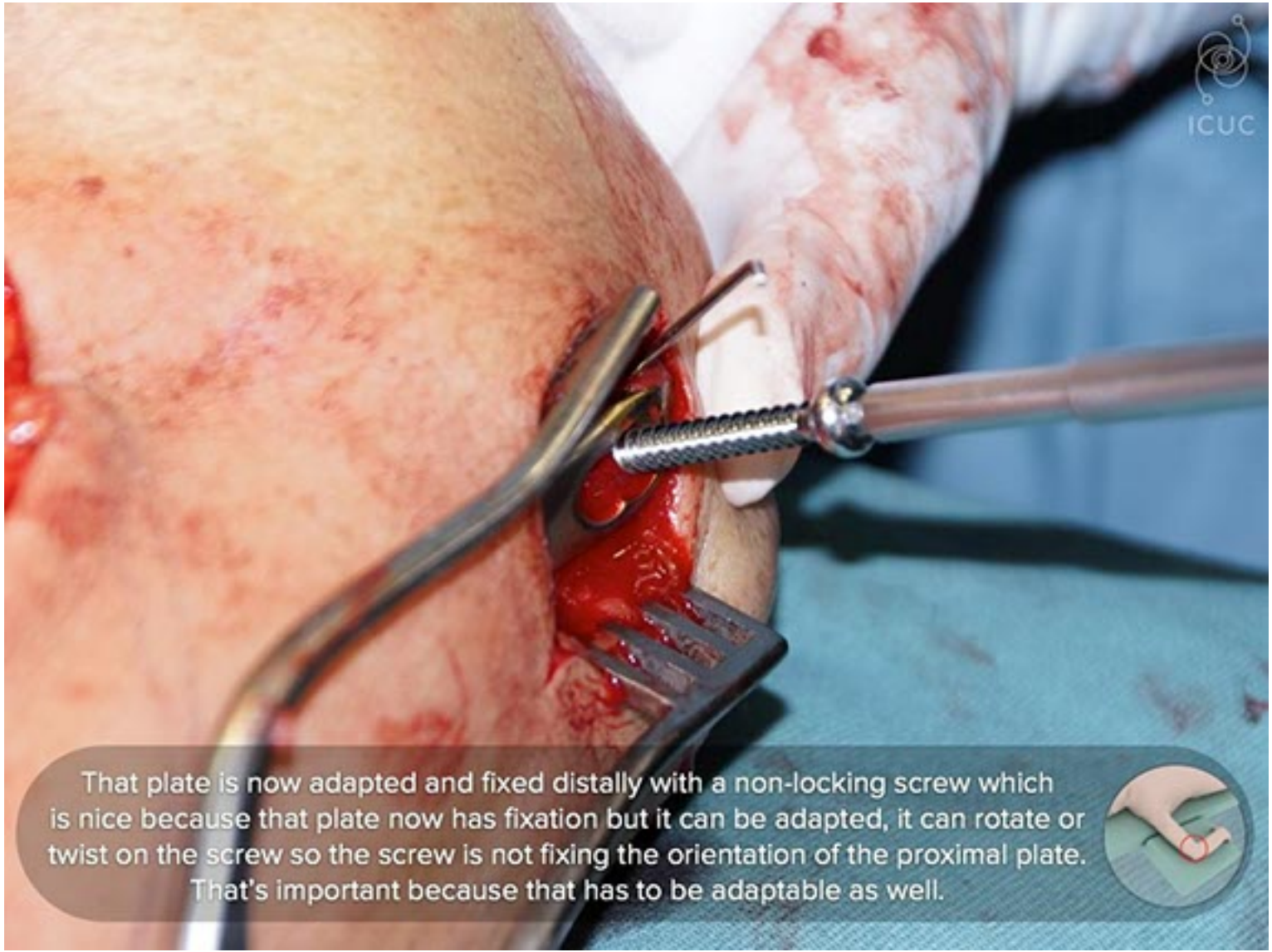




We have distal control on a fracture which we have rotational alignment in.

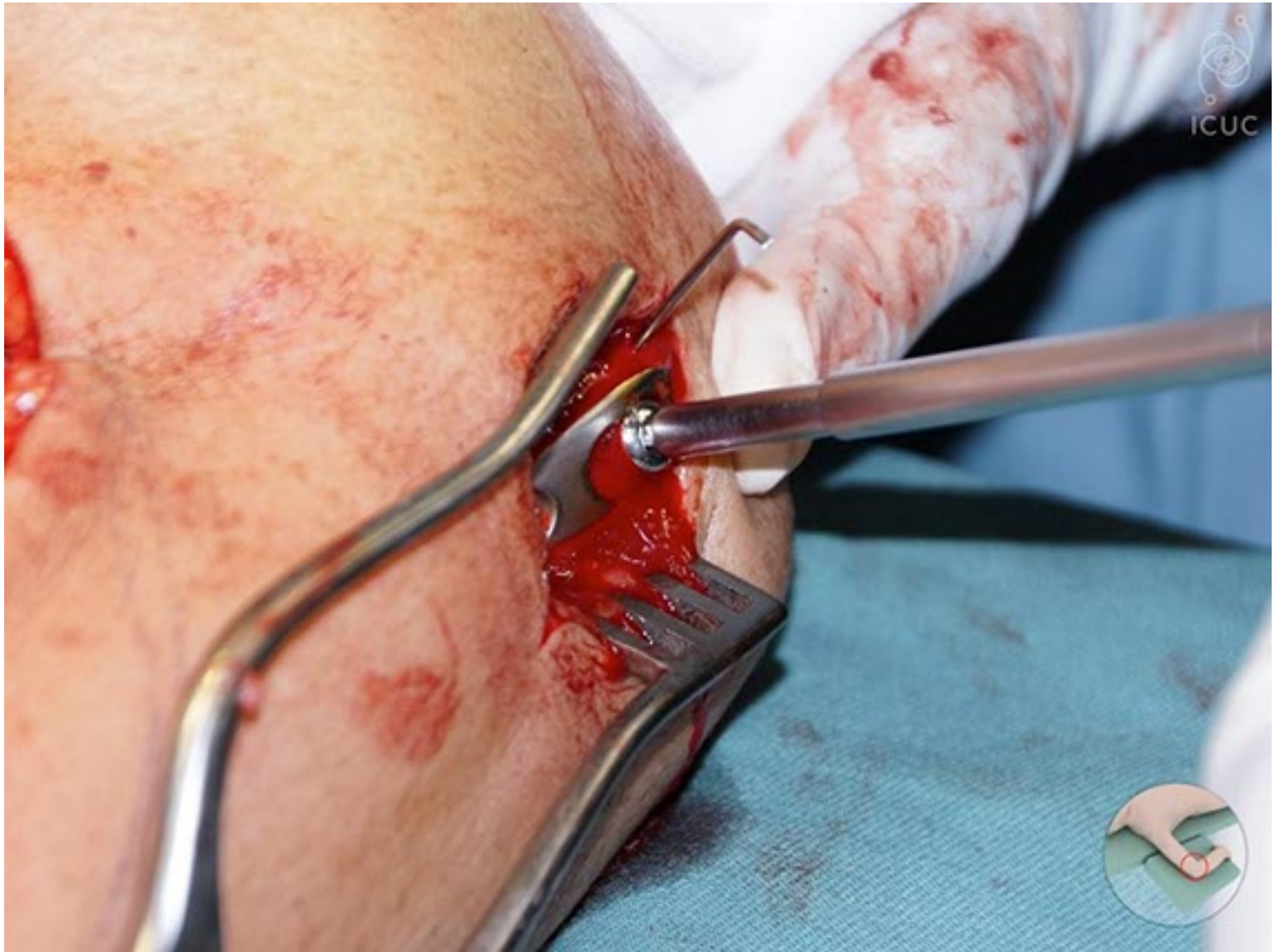


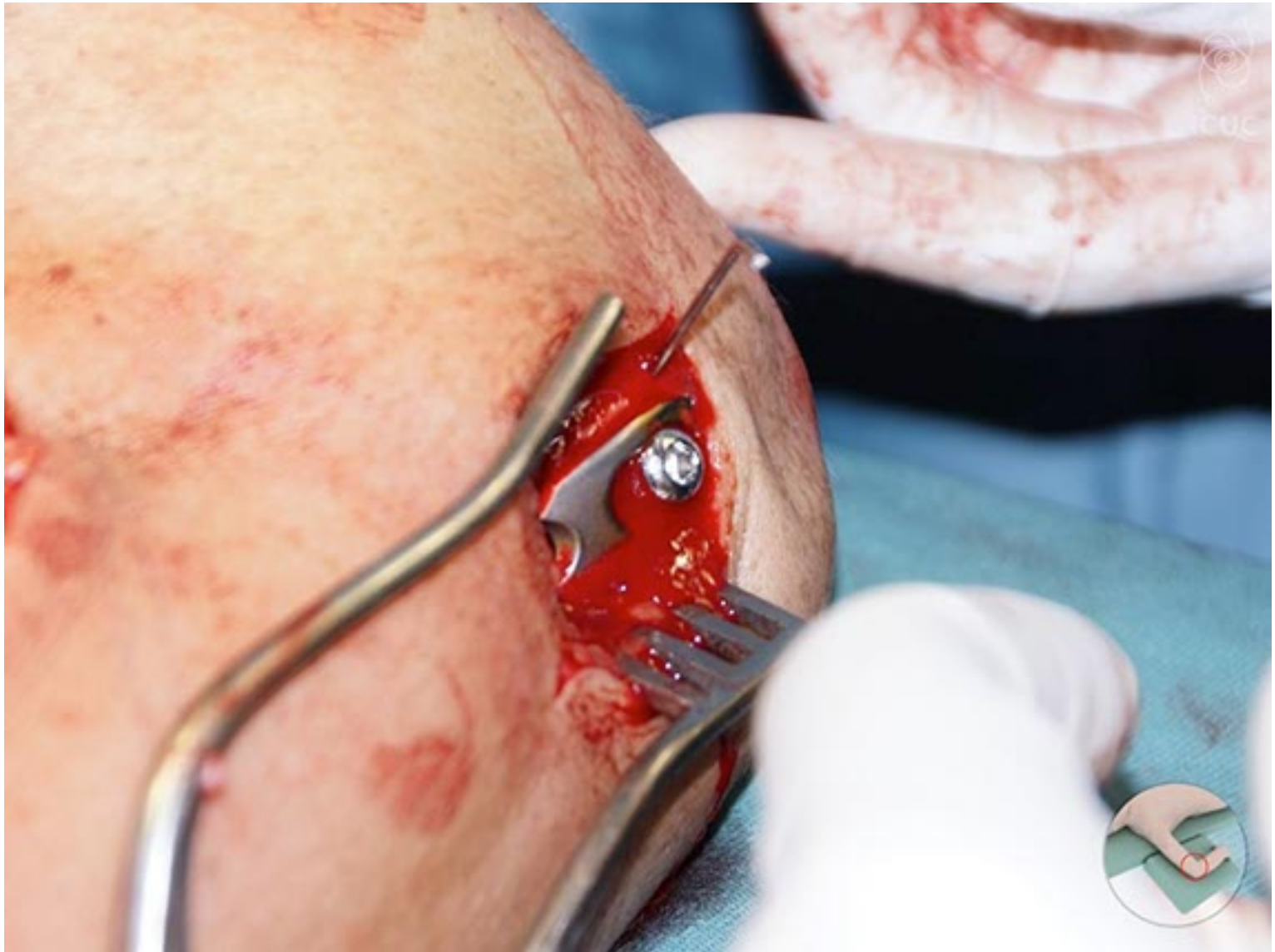


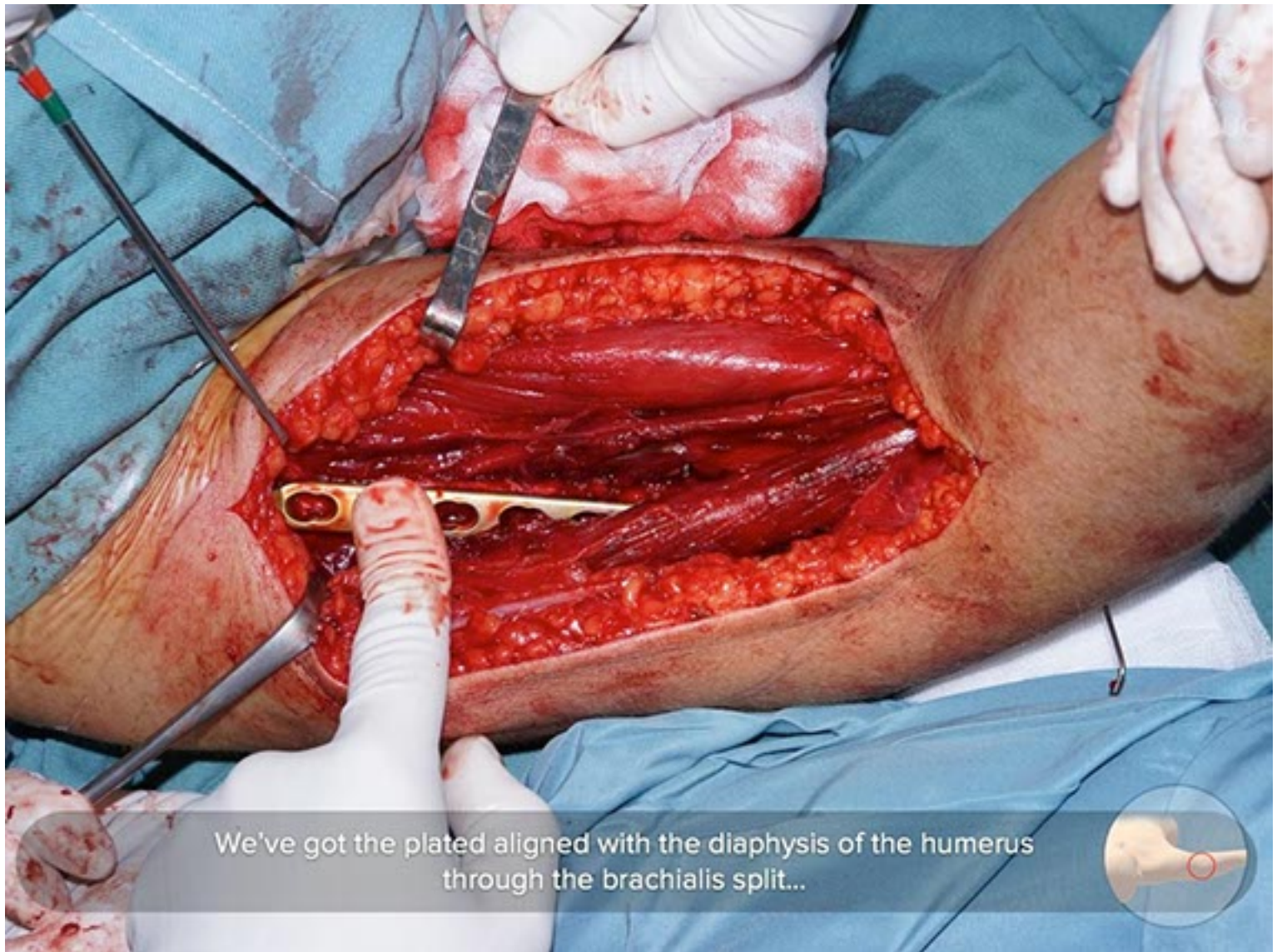That plate is now adapted and fixed distally with a non-locking screw which is nice because that plate now has fixation but it can be adapted, it can rotate or twist on the screw so the screw is not fixing the orientation of the proximal plate. That's important because that has to be adaptable as well.

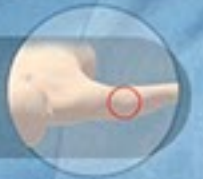

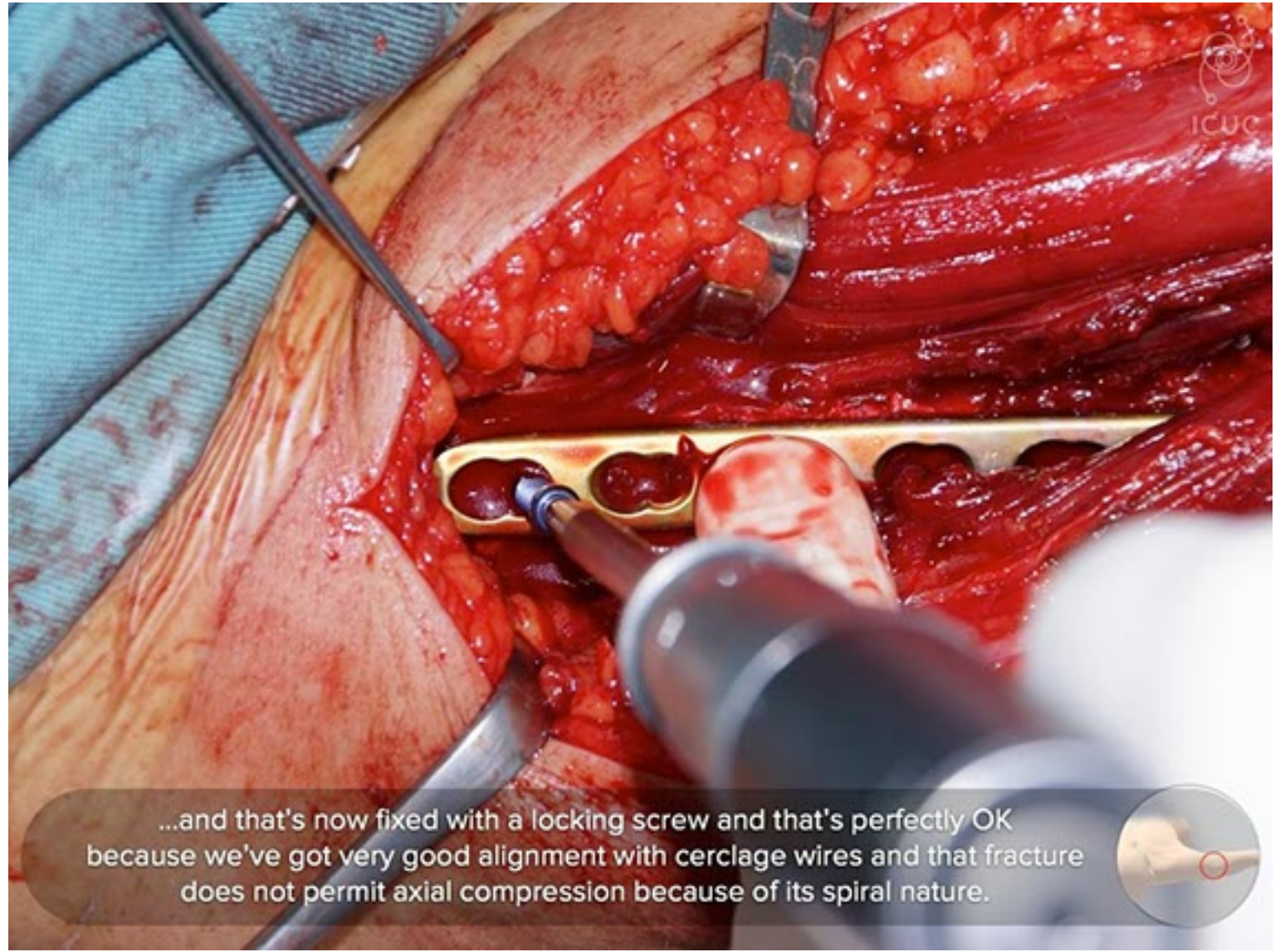





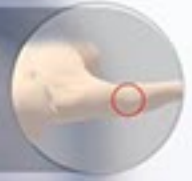
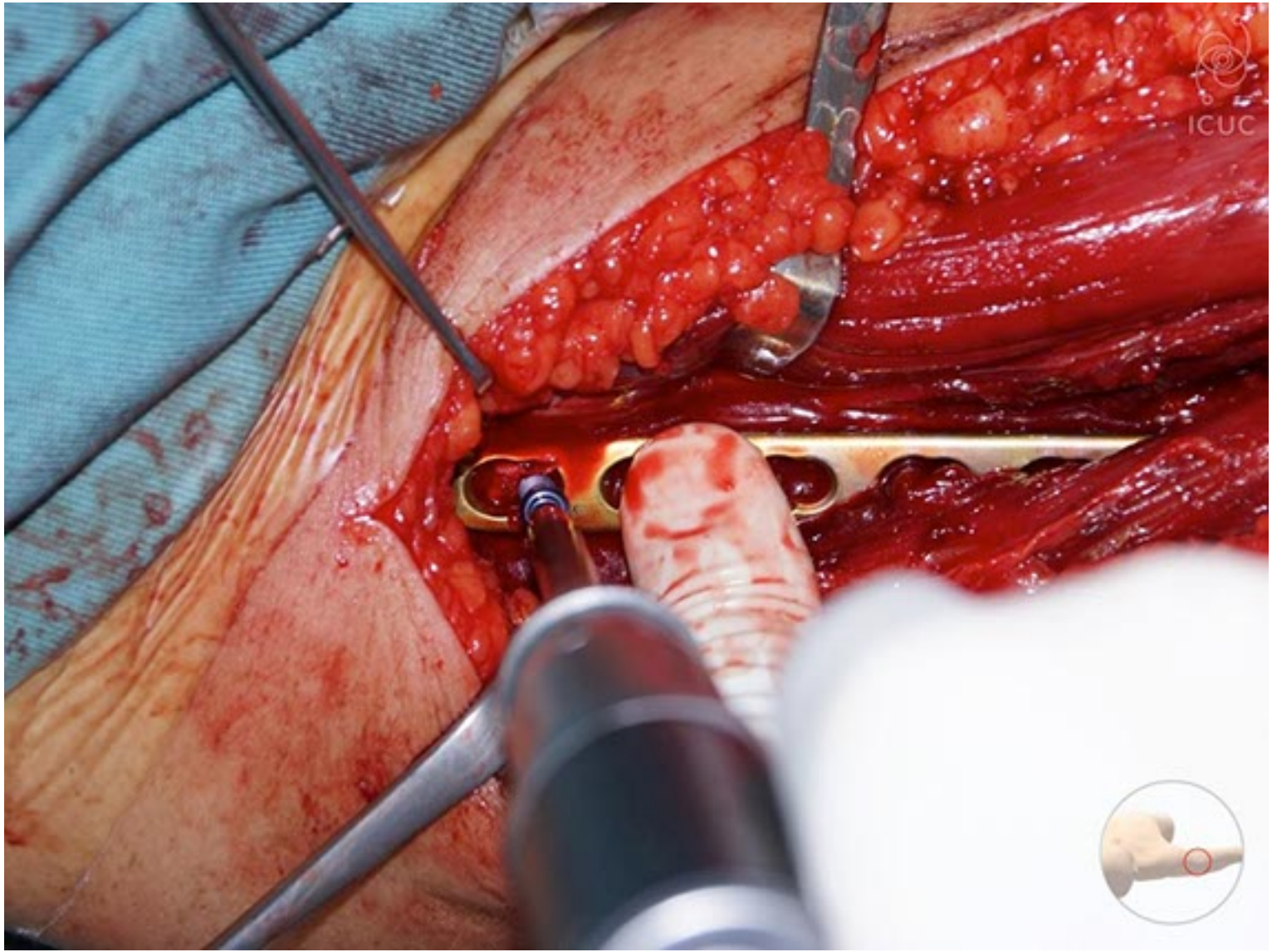
We've got the plated aligned with the diaphysis of the humerus through the brachialis split...

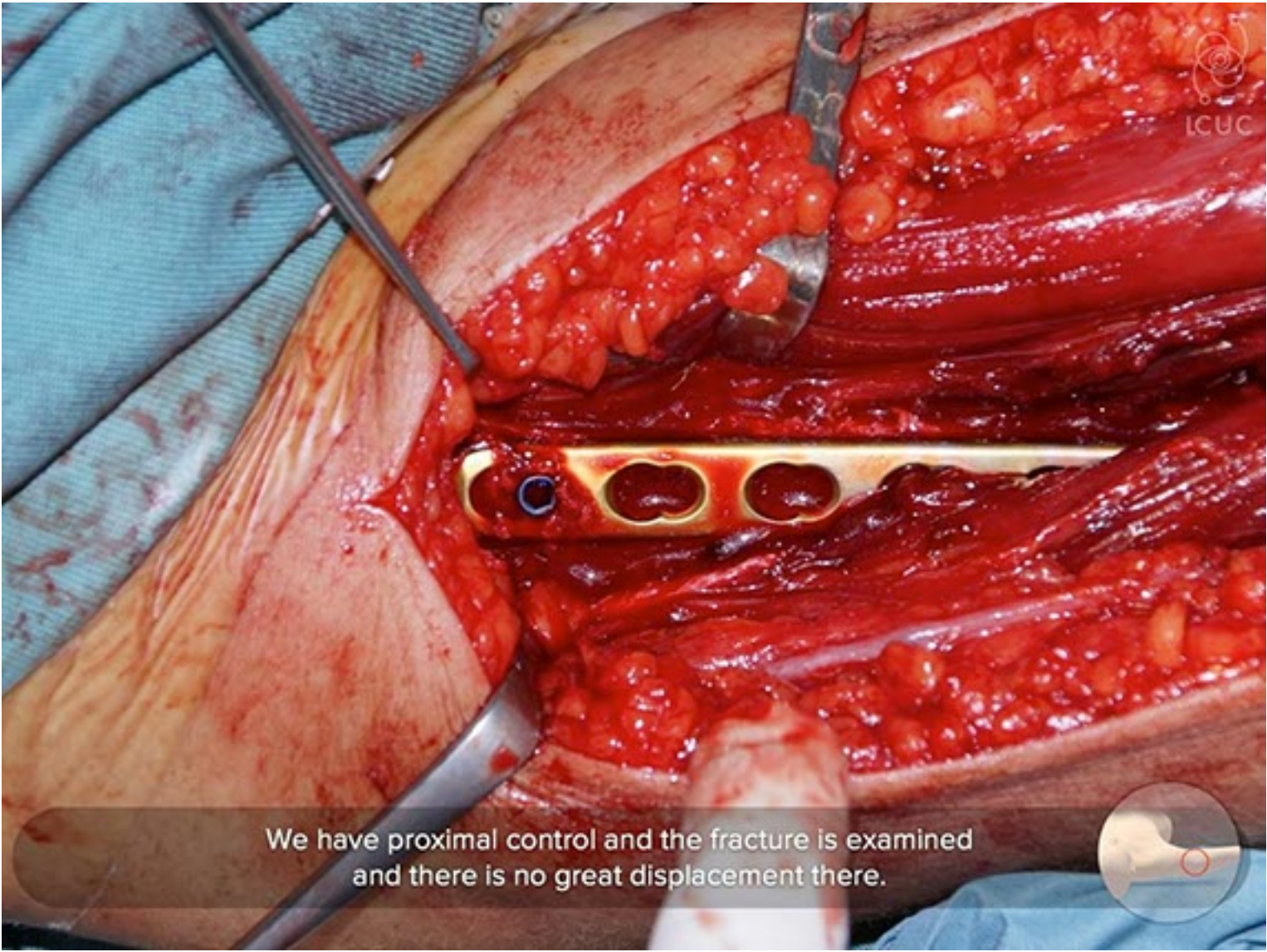




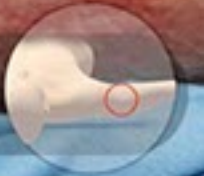...and that's now fixed with a locking screw and that's perfectly OK because we've got very good alignment with cerclage wires and that fracture does not permit axial compression because of its spiral nature.

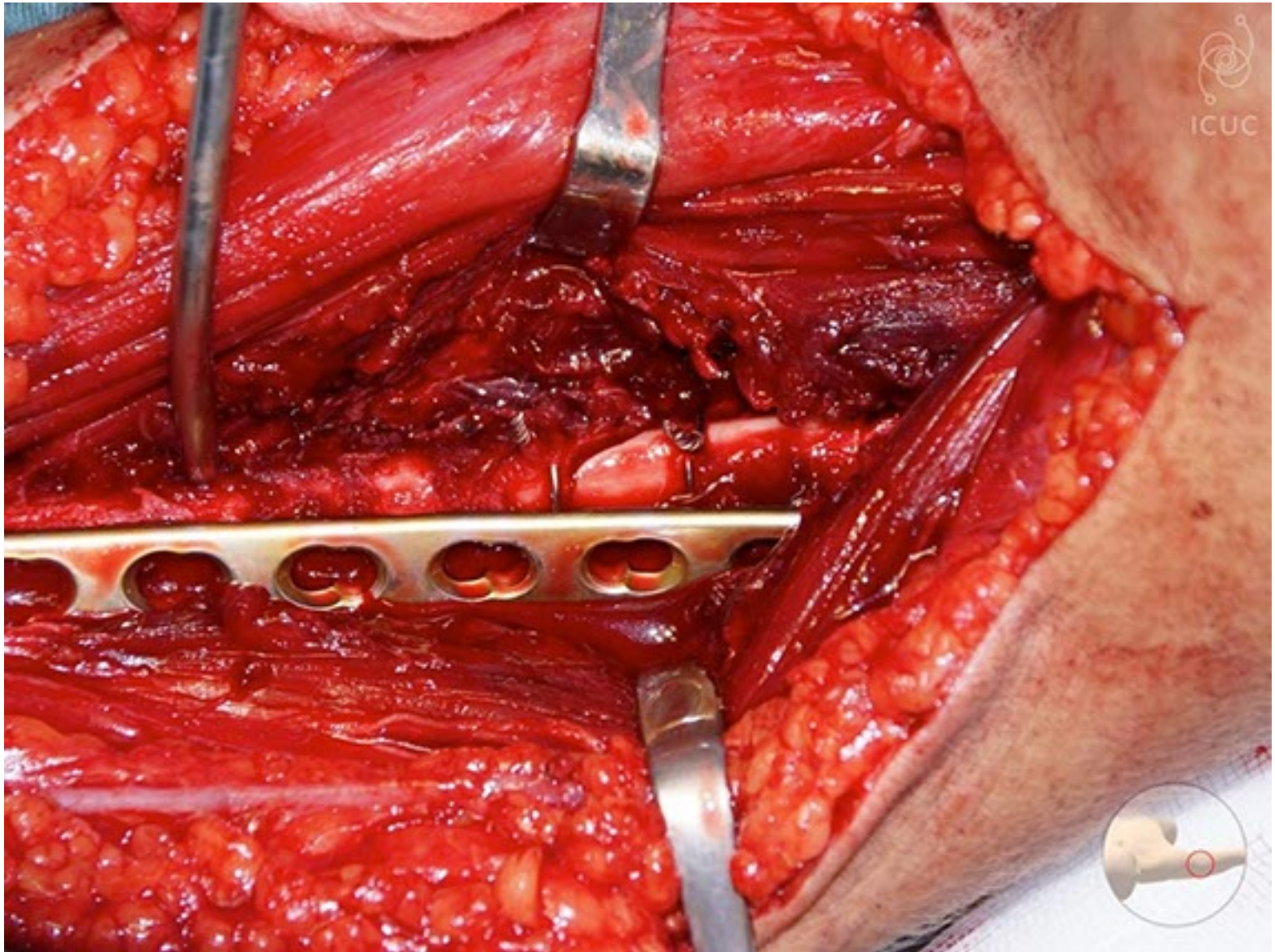


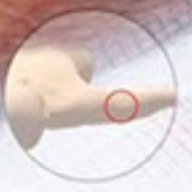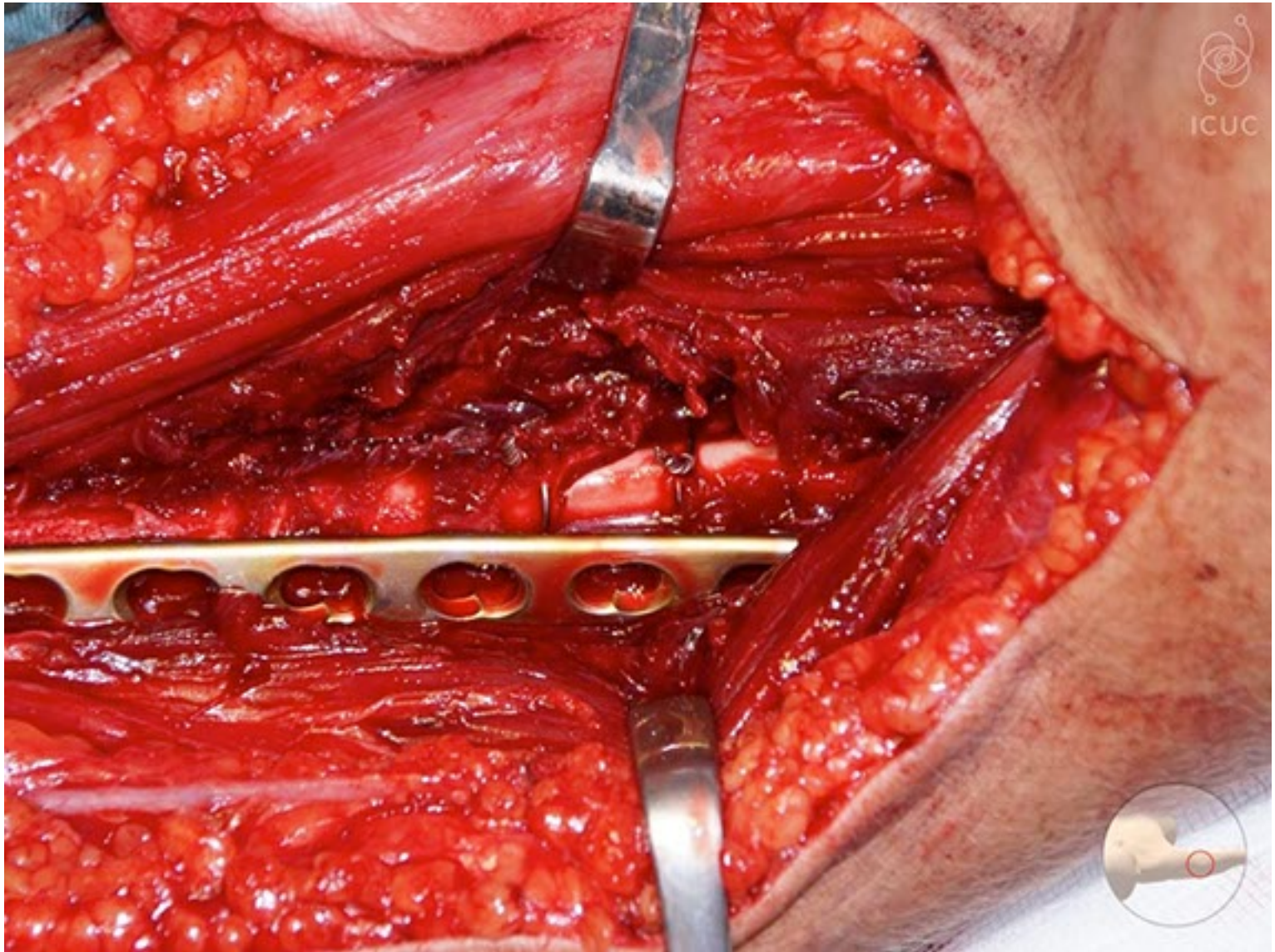


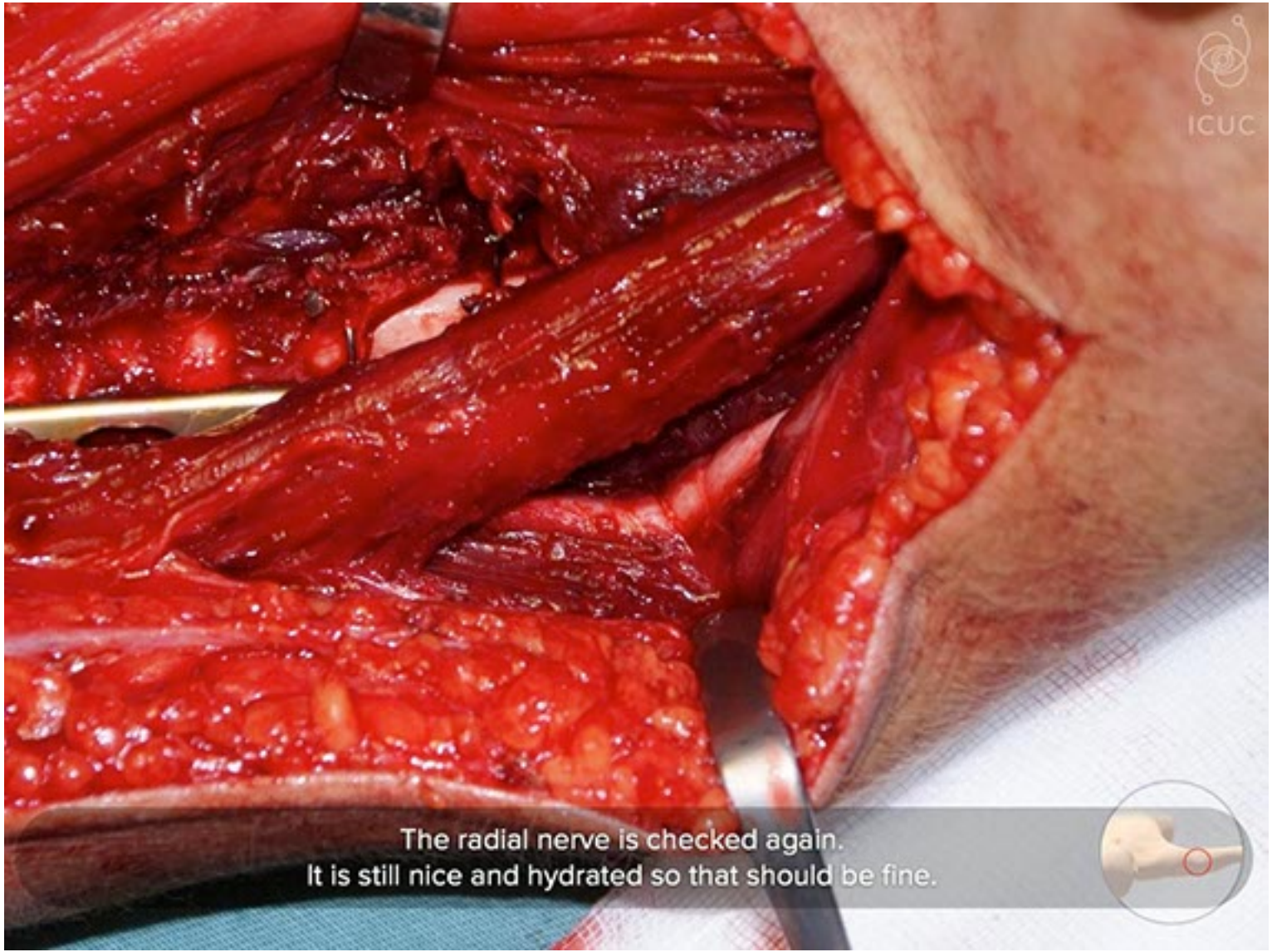


We have proximal control and the fracture is examined and there is no great displacement there.

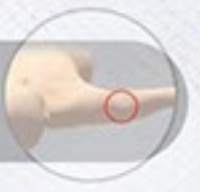

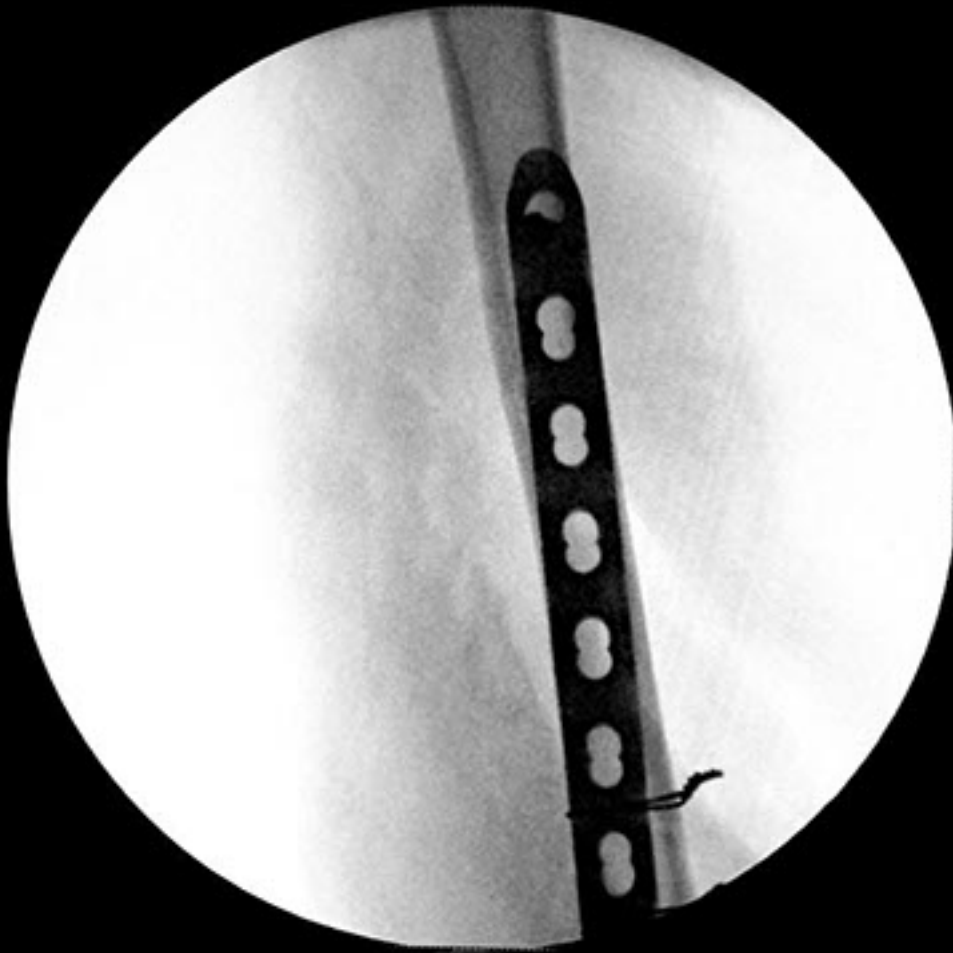





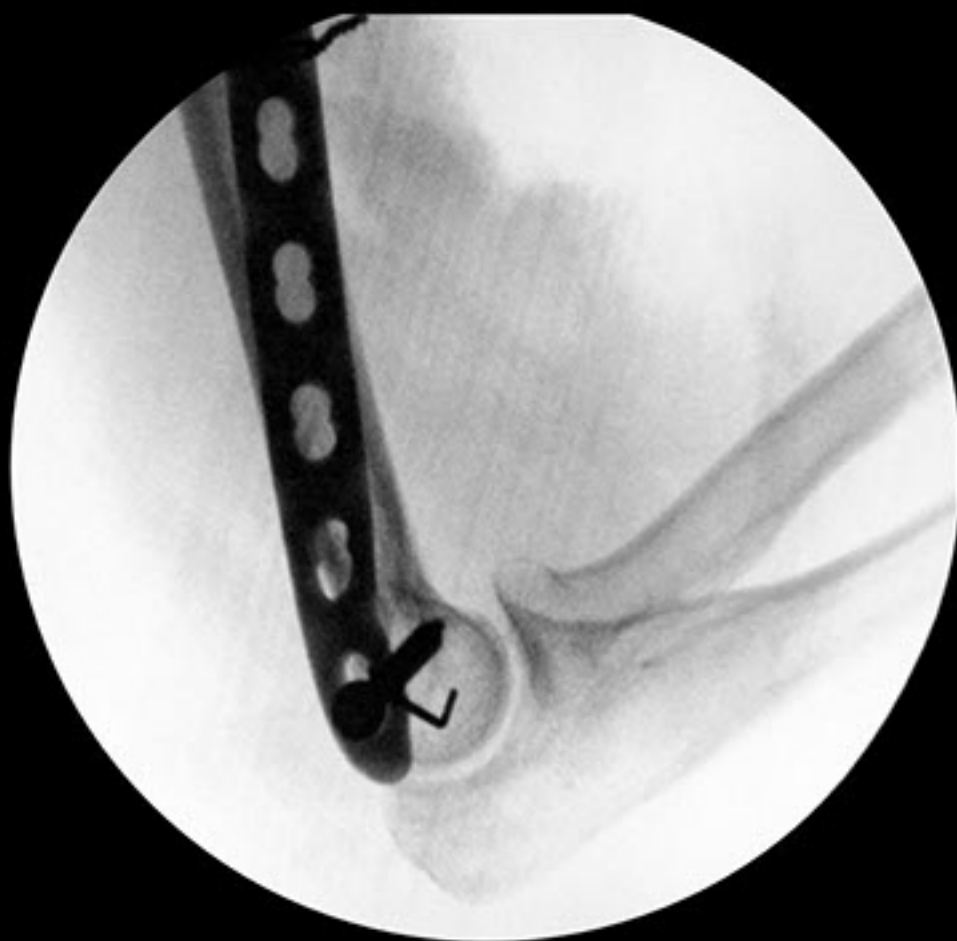
The radial nerve is checked again.
It is still nice and hydrated so that should be fine.





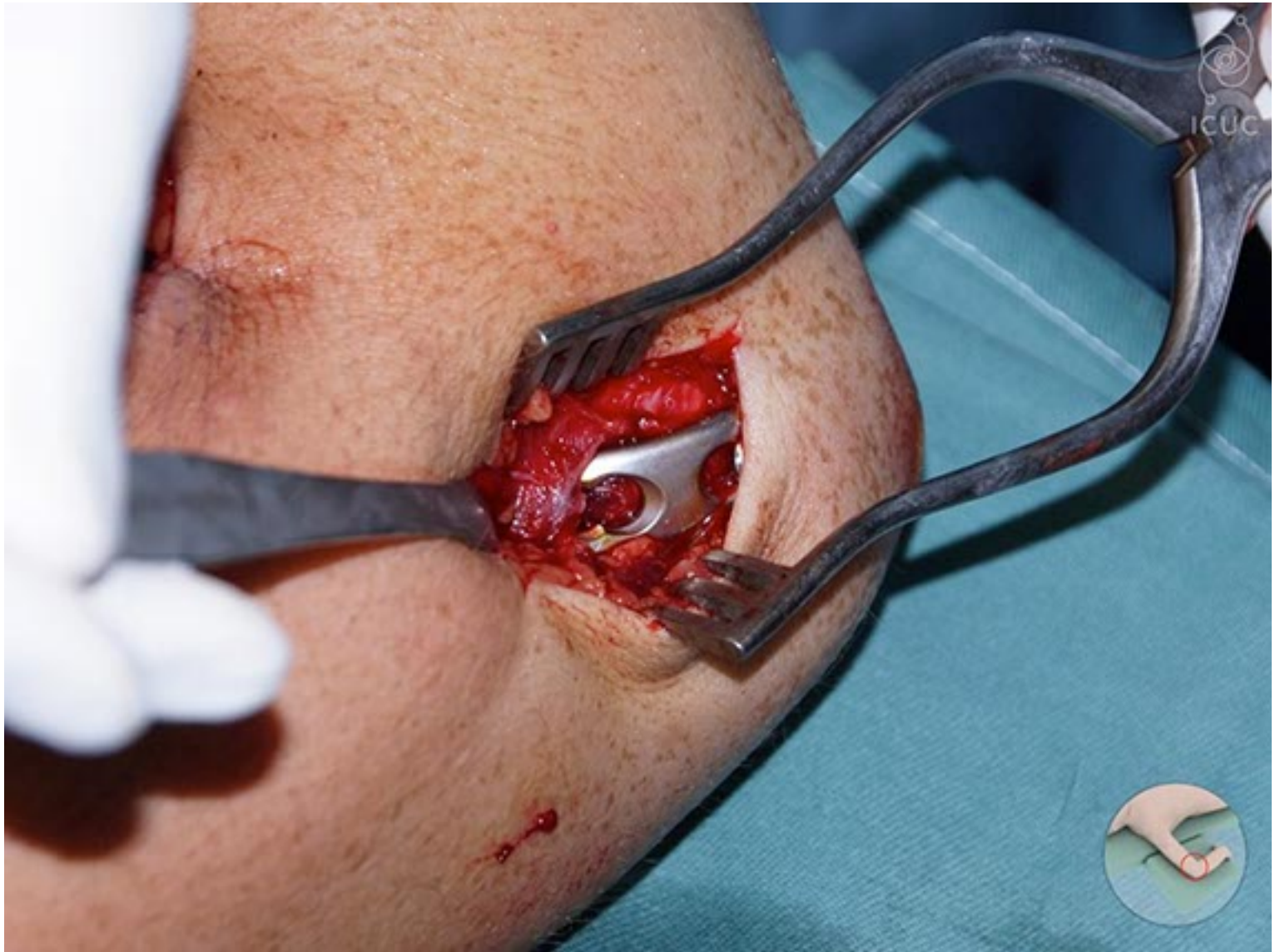
An image intensifier check.

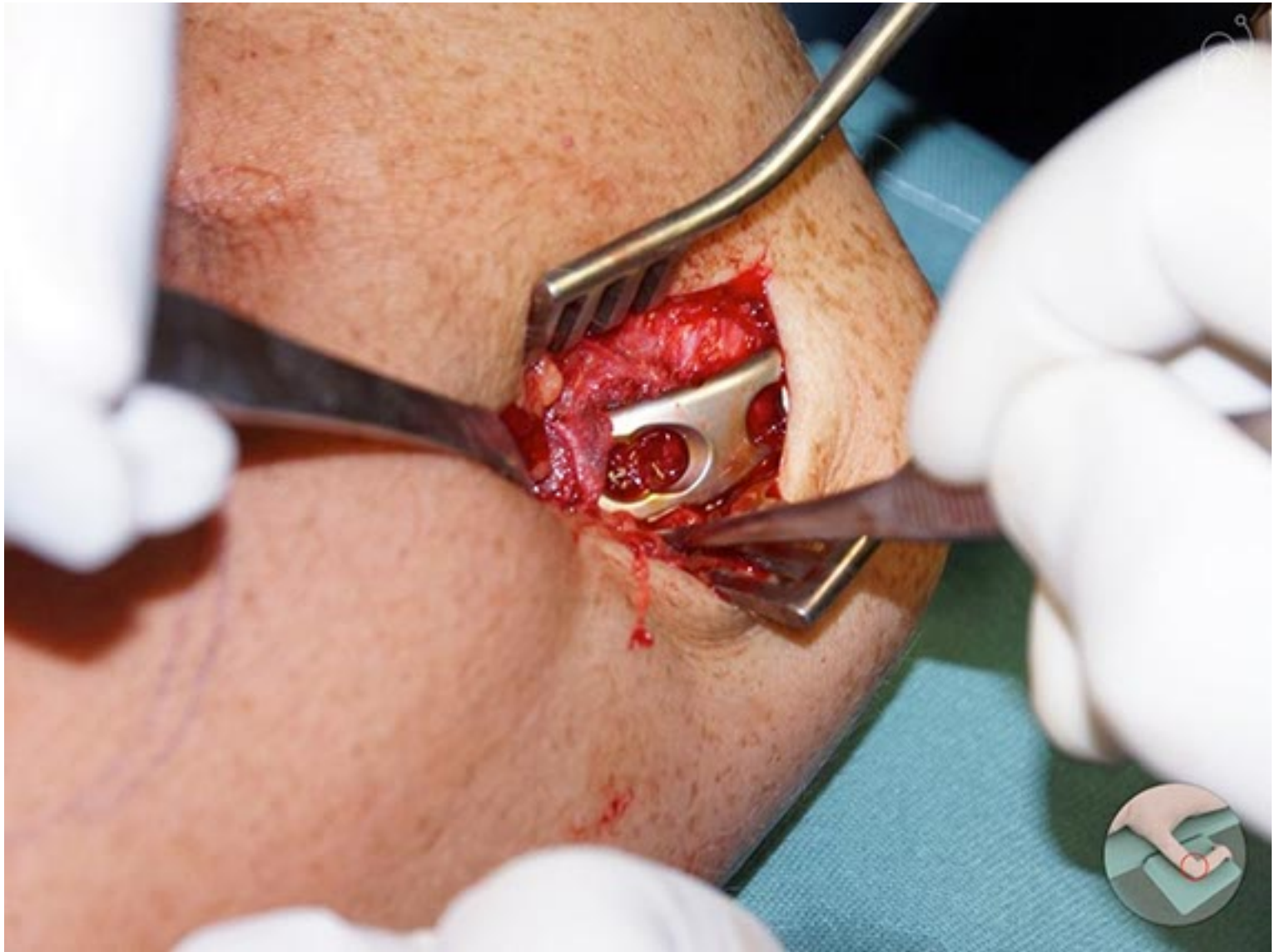


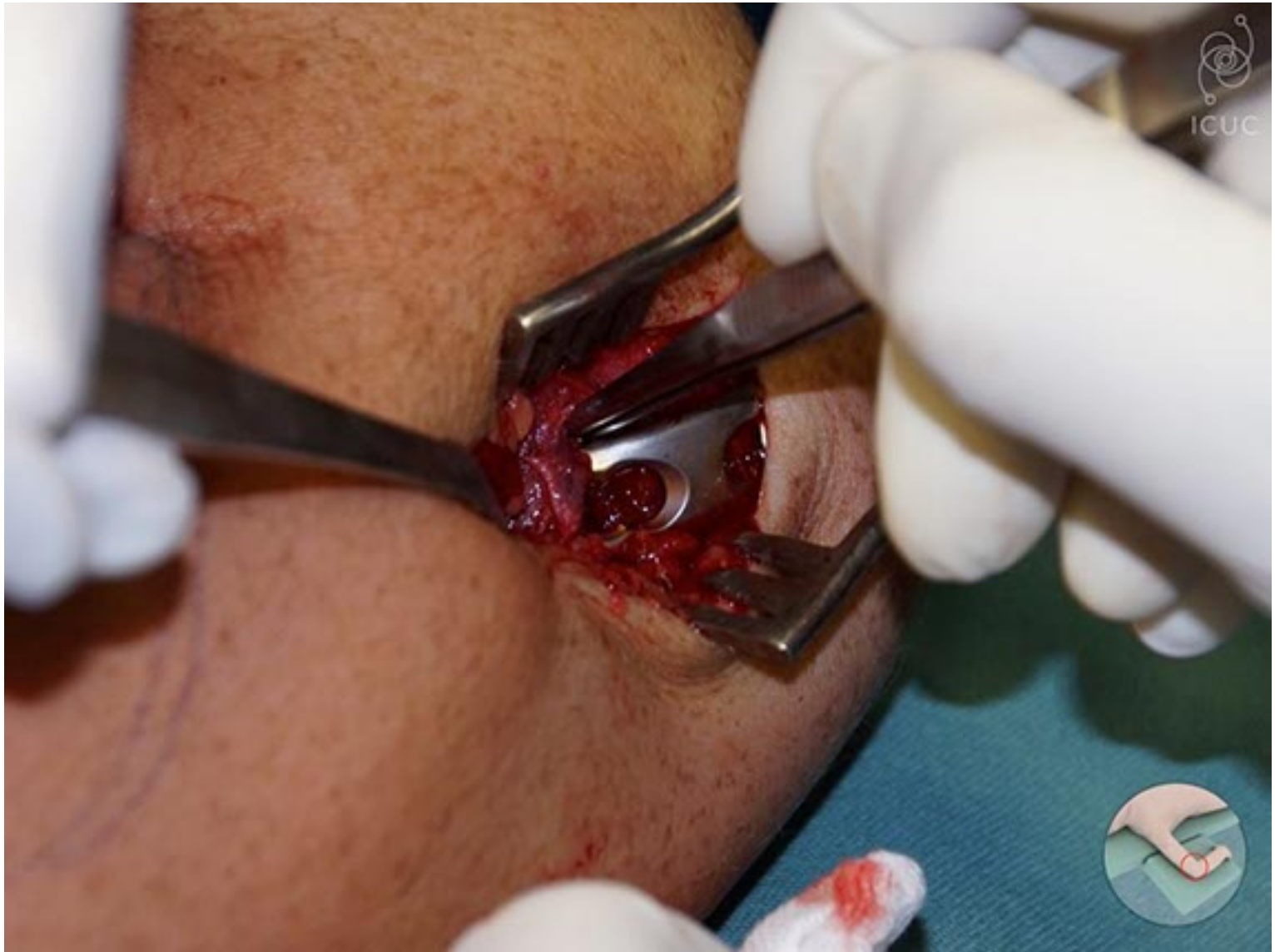Everything is aligned very well. We don't have any overlap of the plate in the joint line.

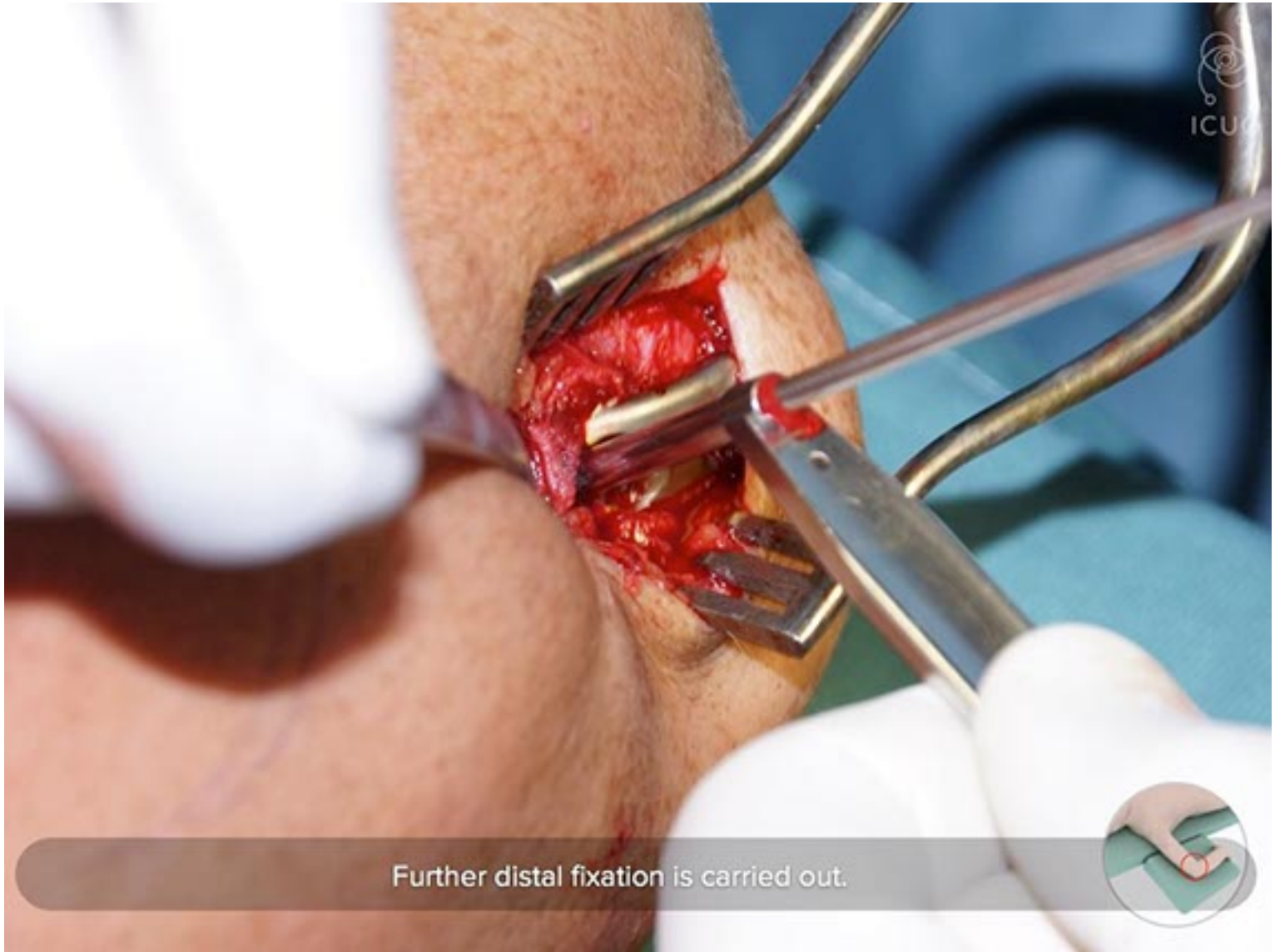Elbow flexion is tested again so we know we haven't got a big issue with impingement of the plate on the soft tissues.





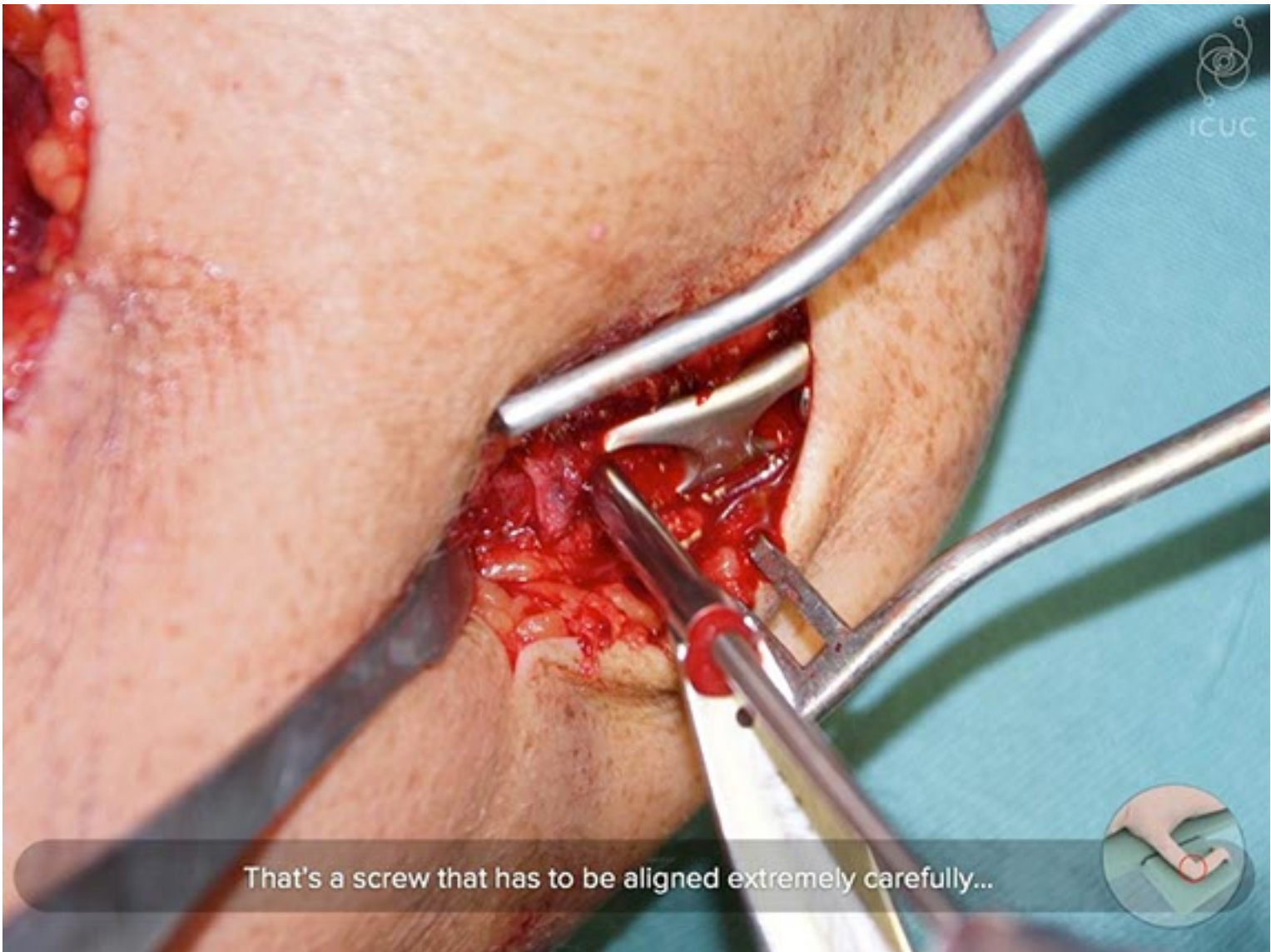






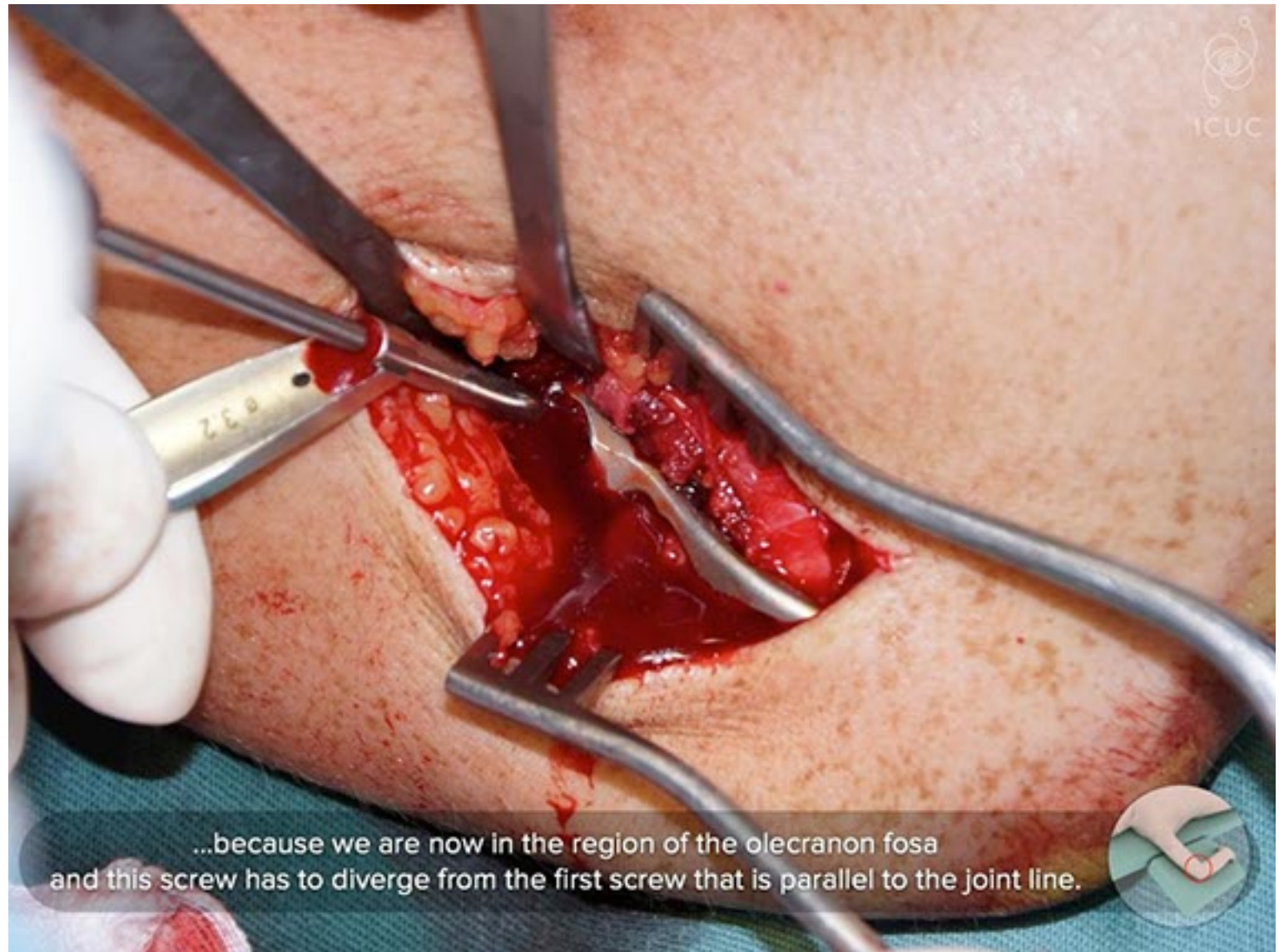
Further distal fixation is carried out.



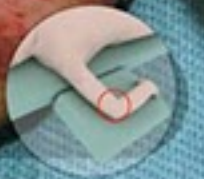

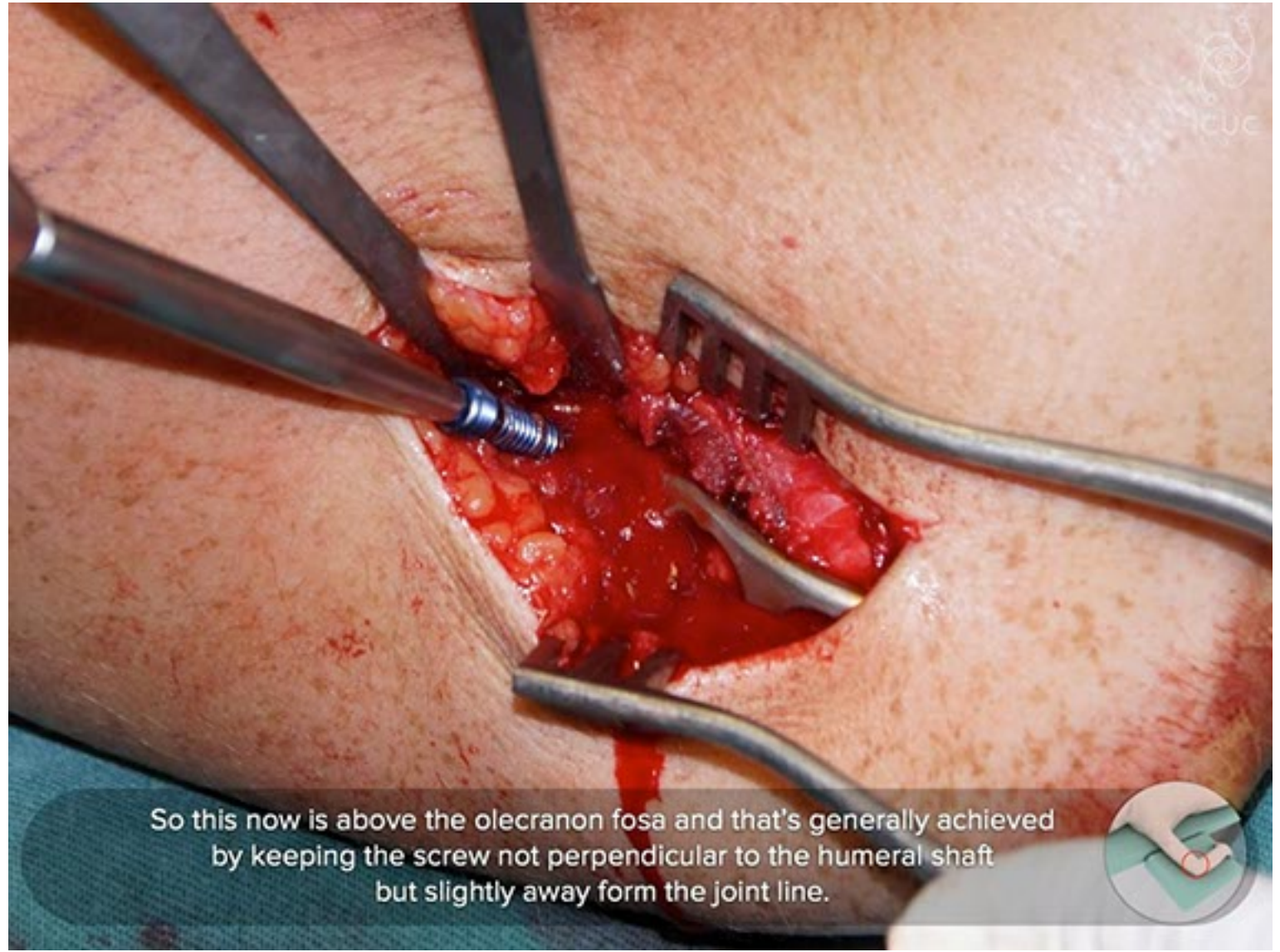That's a screw that has to be aligned extremely carefully...





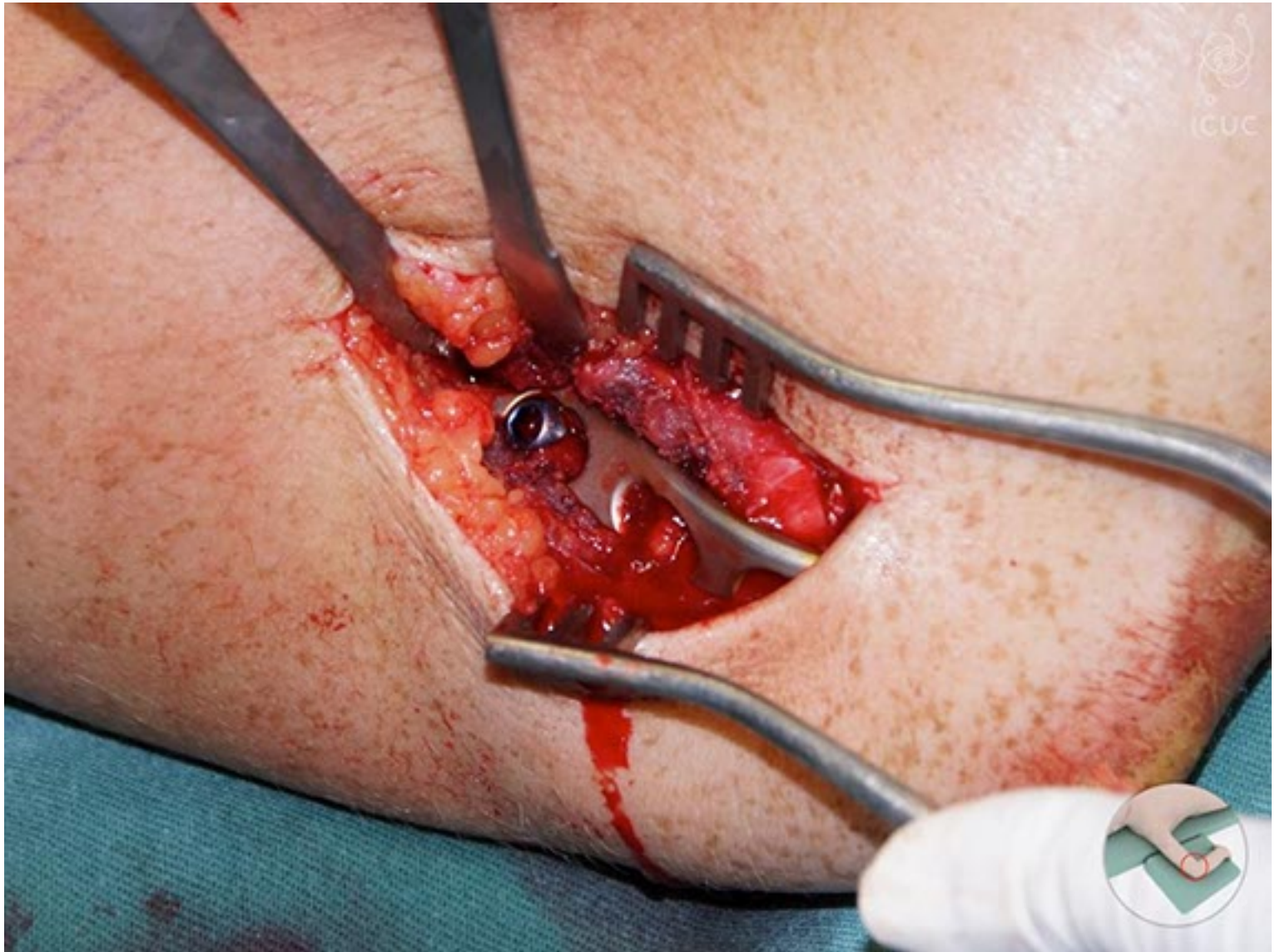
...because we are now in the region of the olecranon fossa and this screw has to diverge from the first screw that is parallel to the joint line.

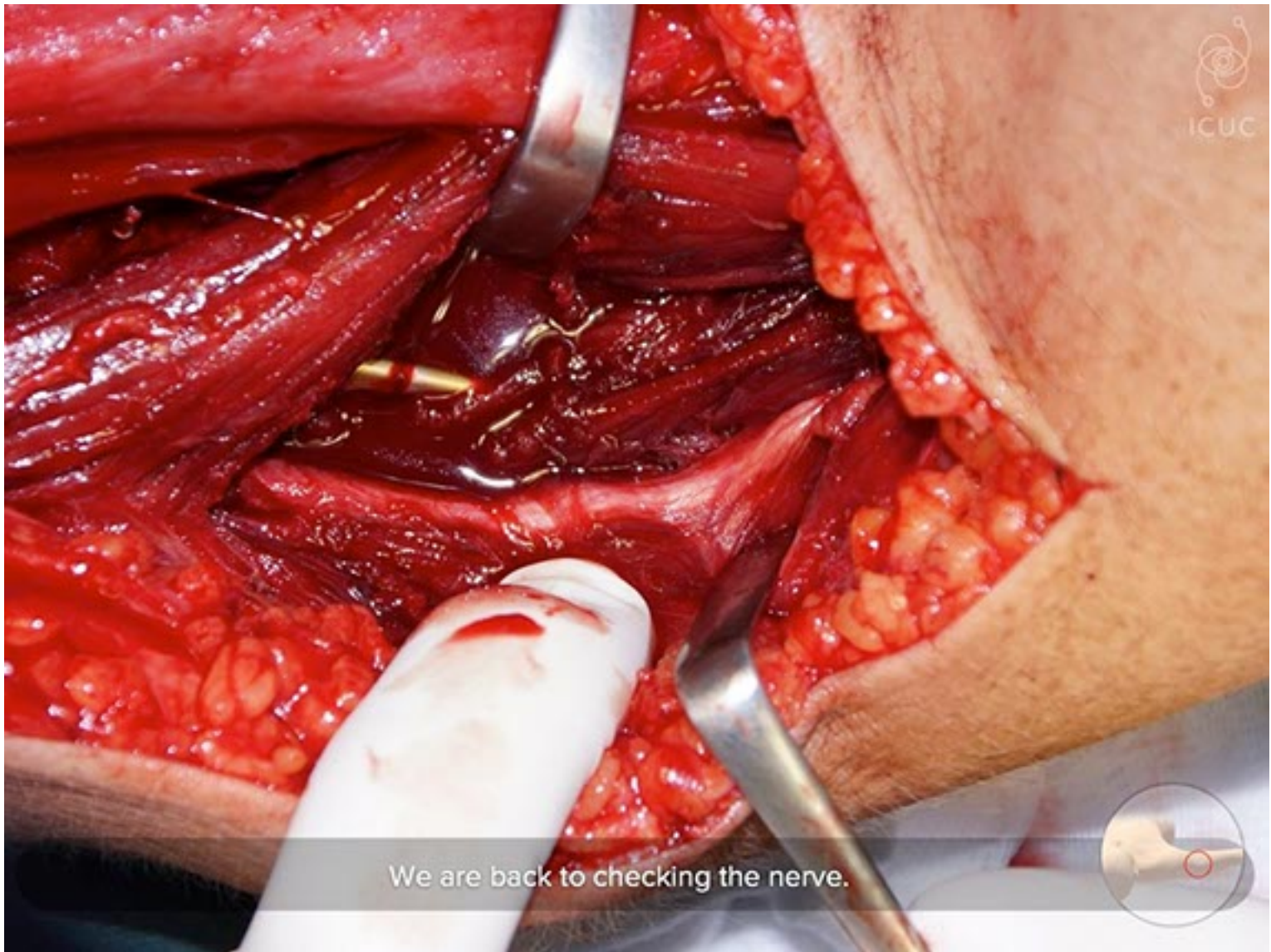



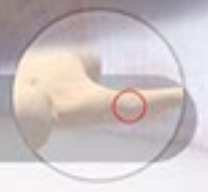So this now is above the olecranon fossa and that's generally achieved by keeping the screw not perpendicular to the humeral shaft but slightly away from the joint line.

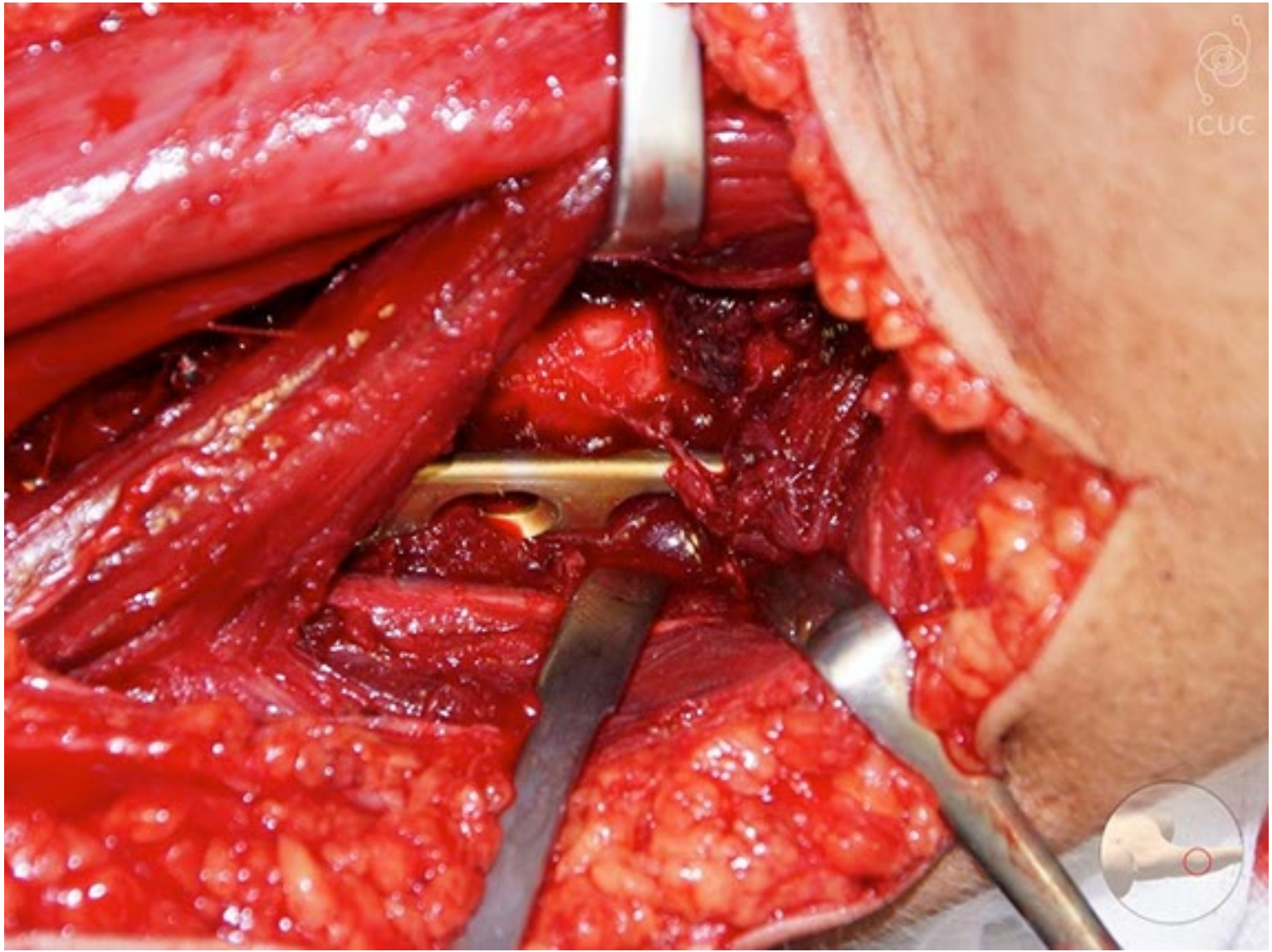


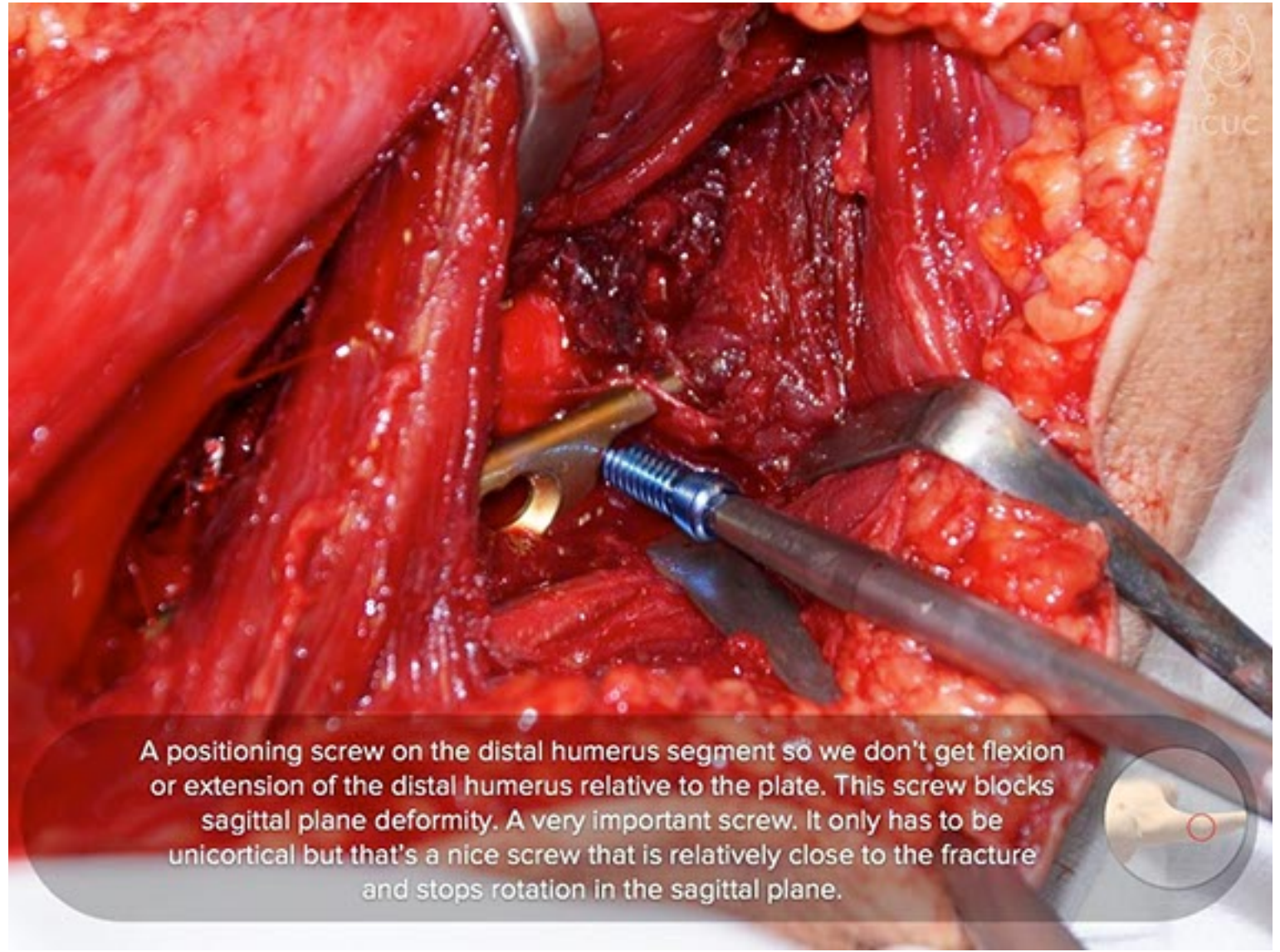




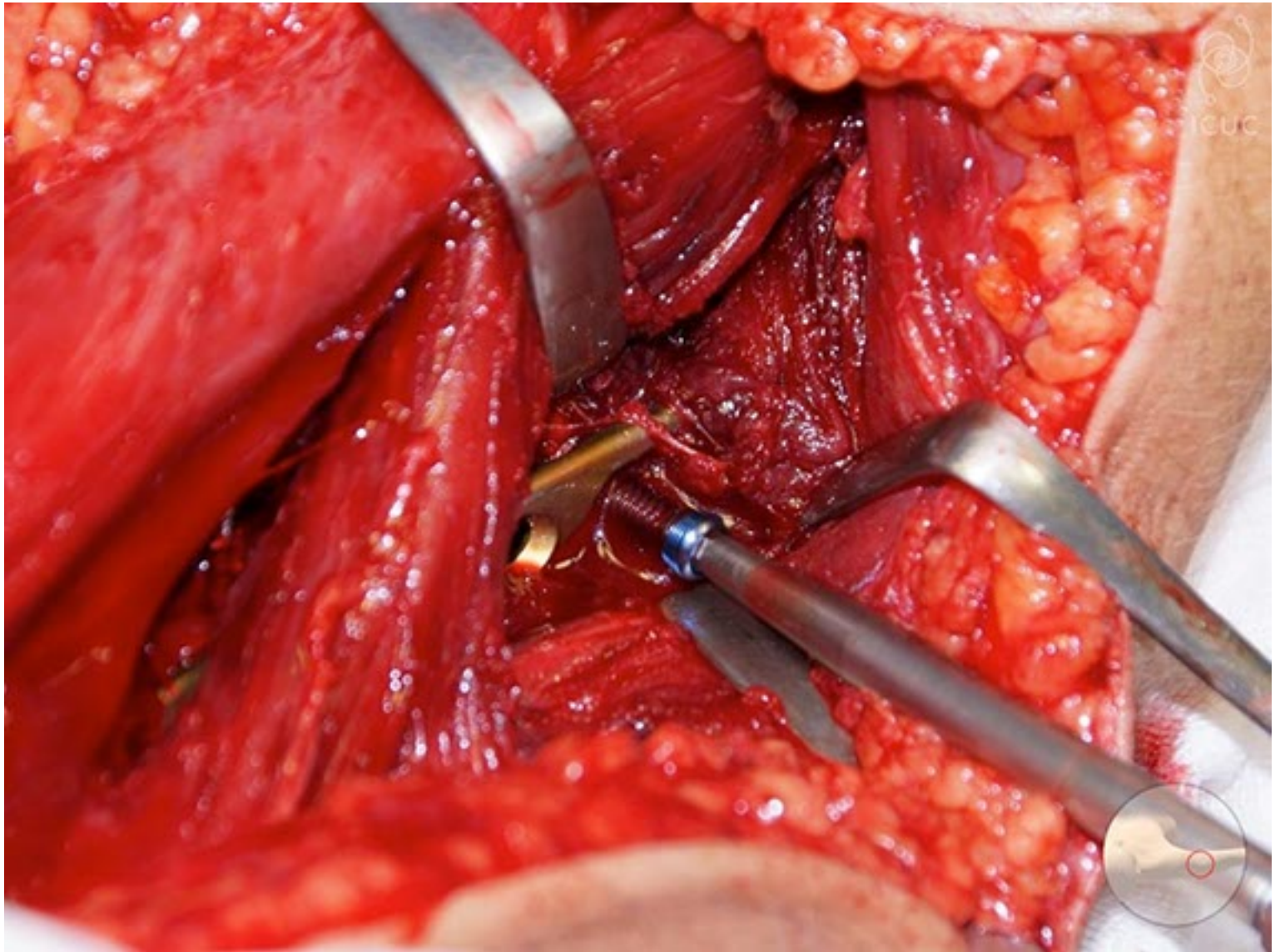
We are back to checking the nerve.

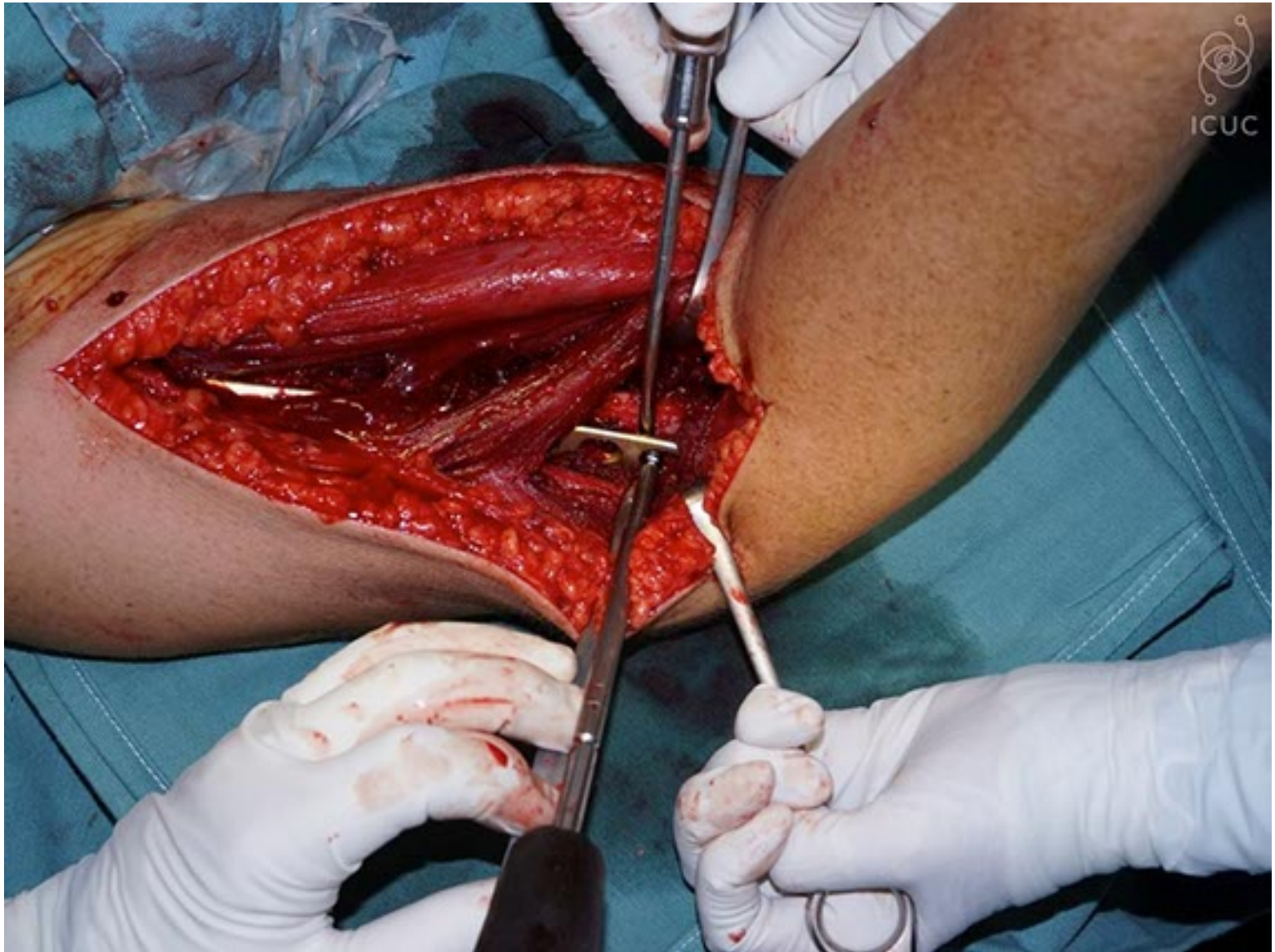


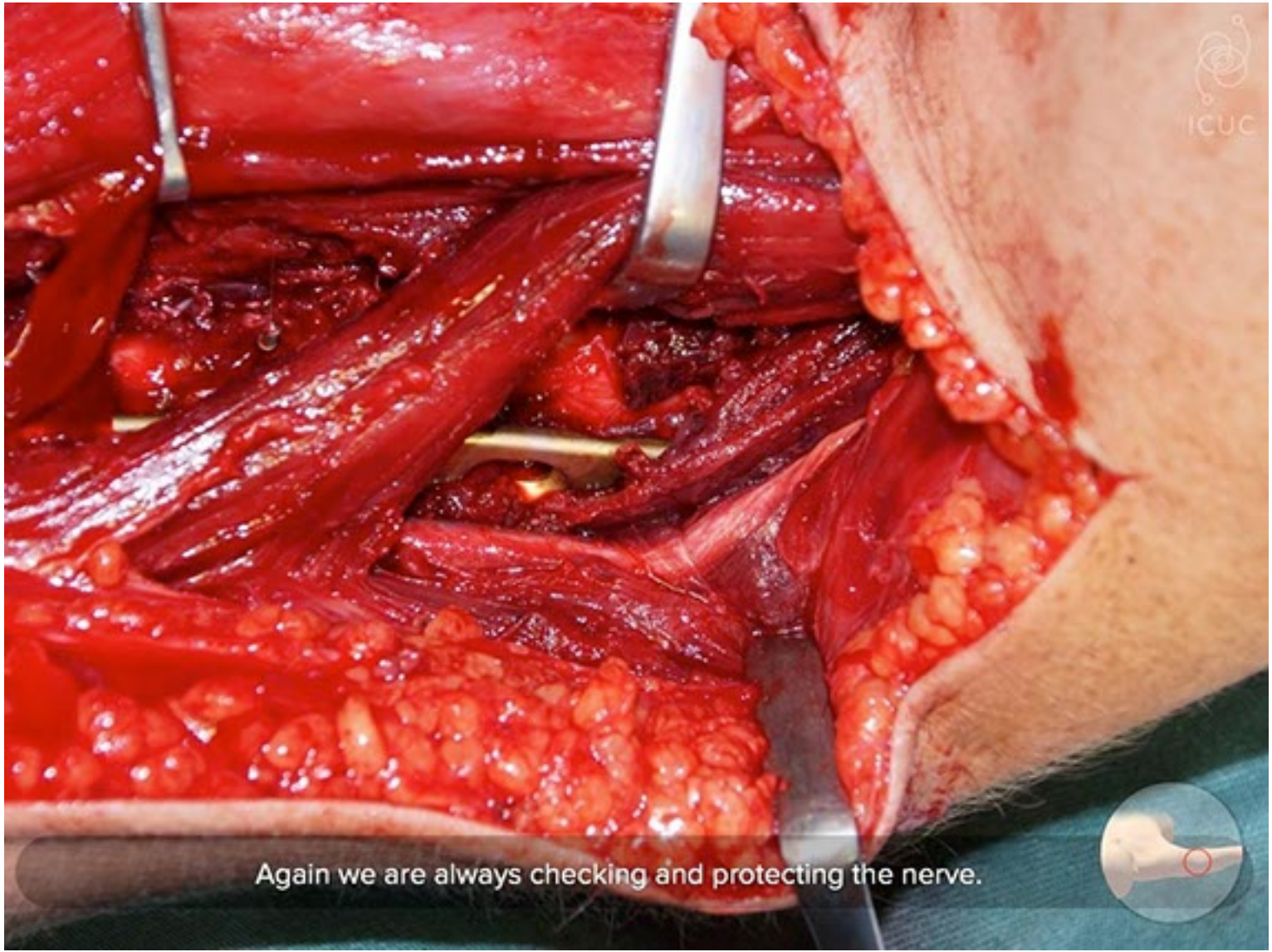




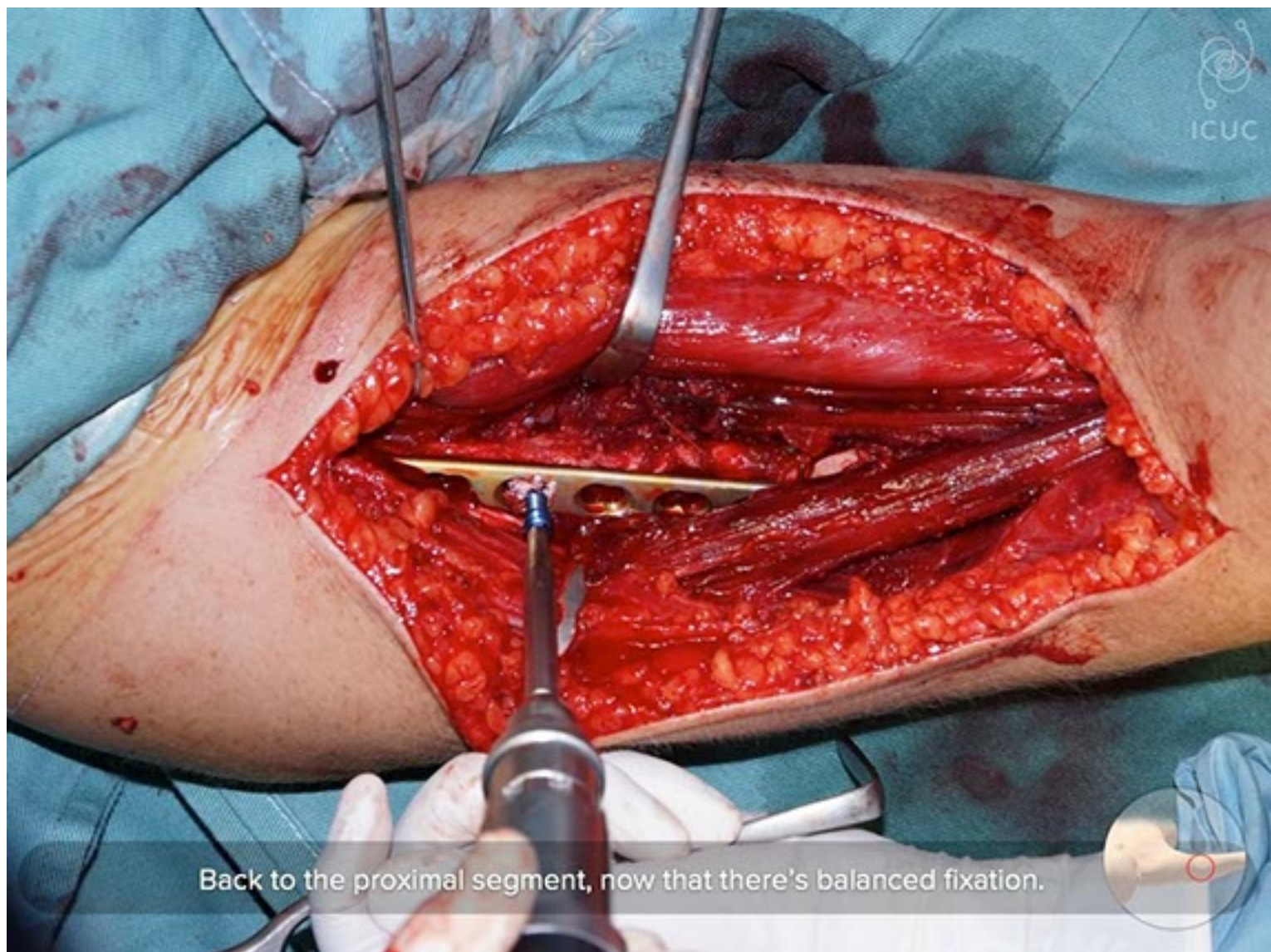
A positioning screw on the distal humerus segment so we don't get flexion or extension of the distal humerus relative to the plate. This screw blocks sagittal plane deformity. A very important screw. It only has to be unicortical but that's a nice screw that is relatively close to the fracture and stops rotation in the sagittal plane.



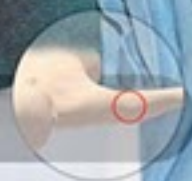

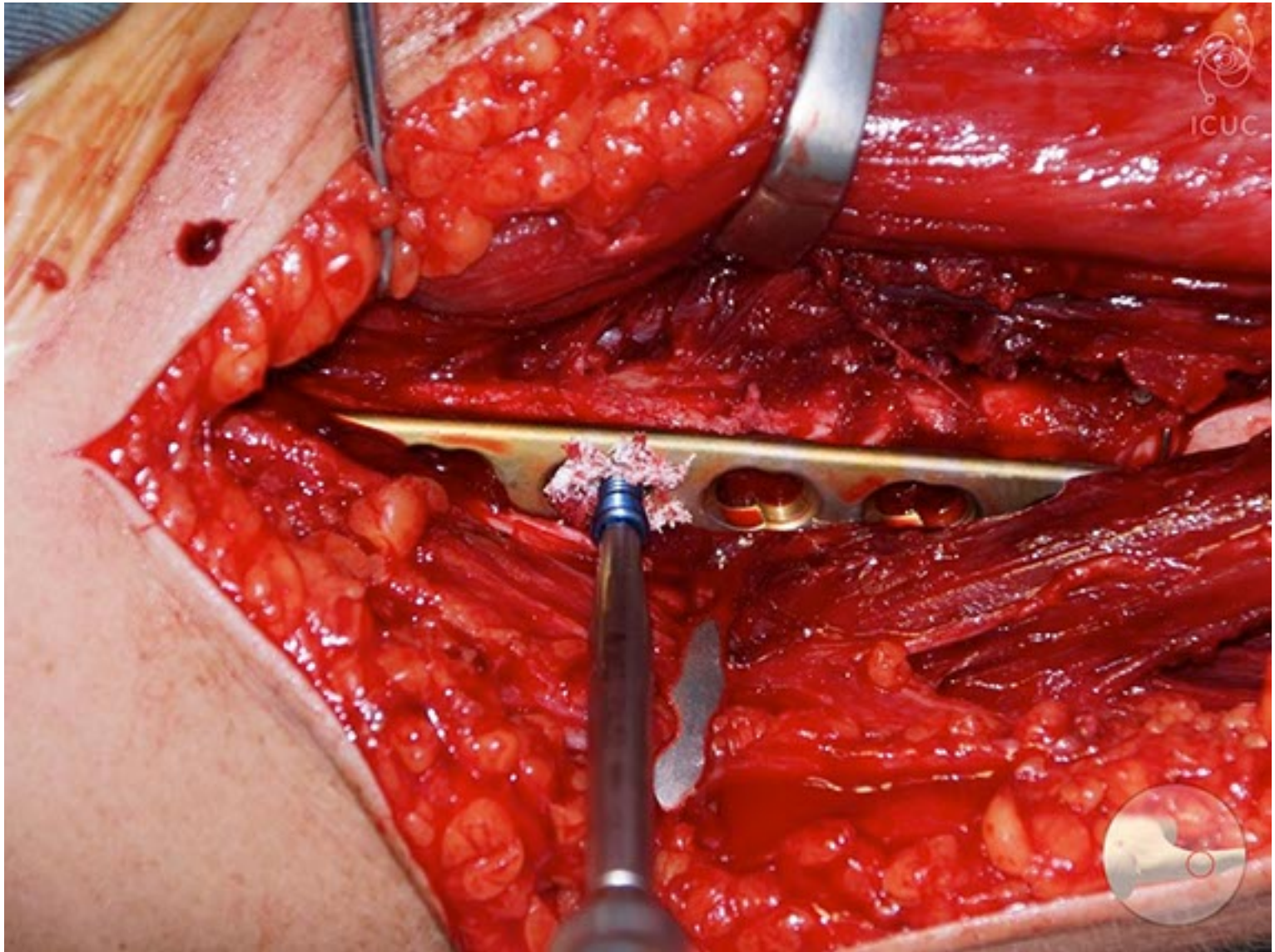


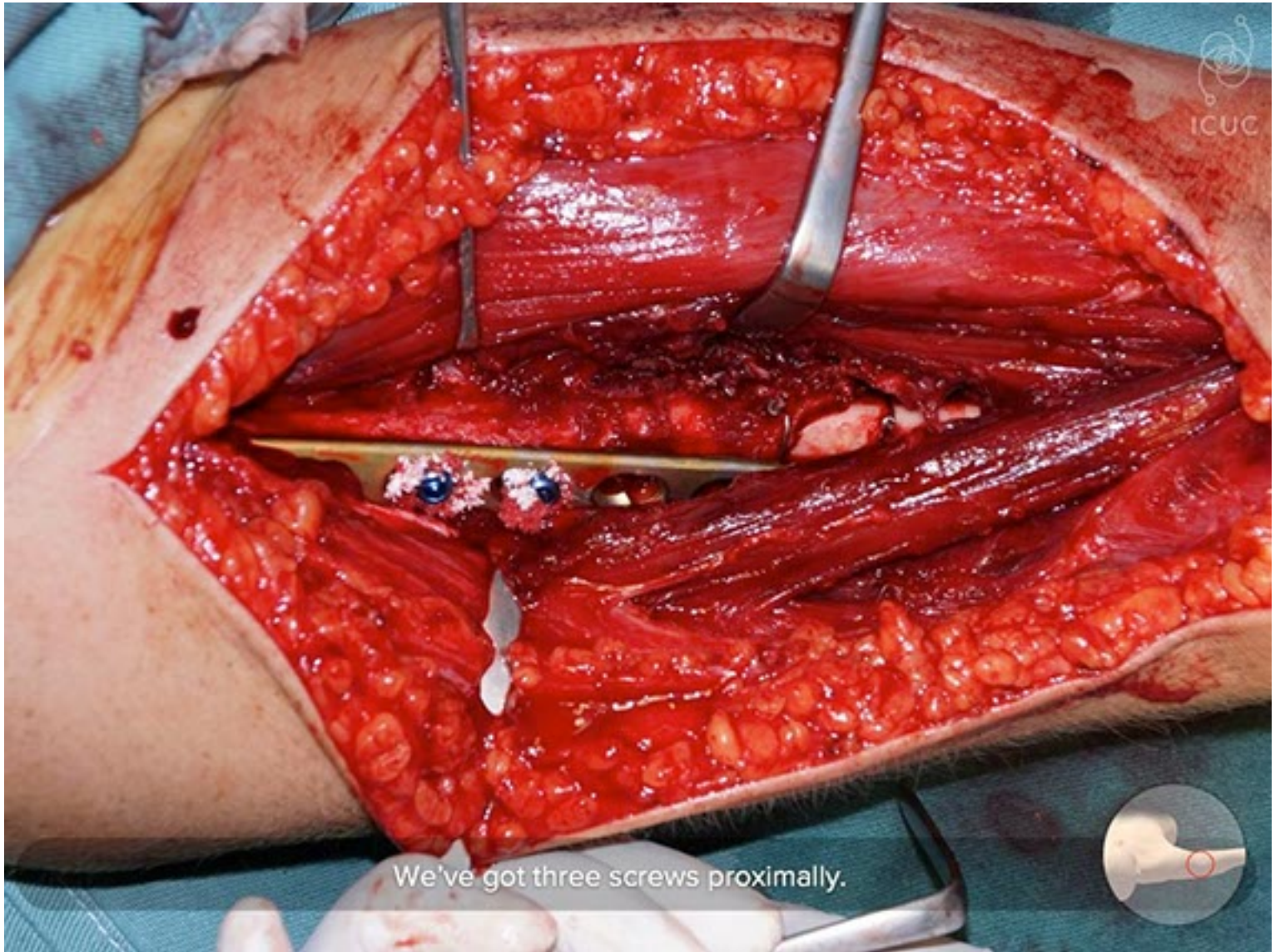
Again we are always checking and protecting the nerve.



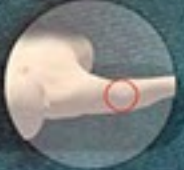Back to the proximal segment, now that there's balanced fixation.

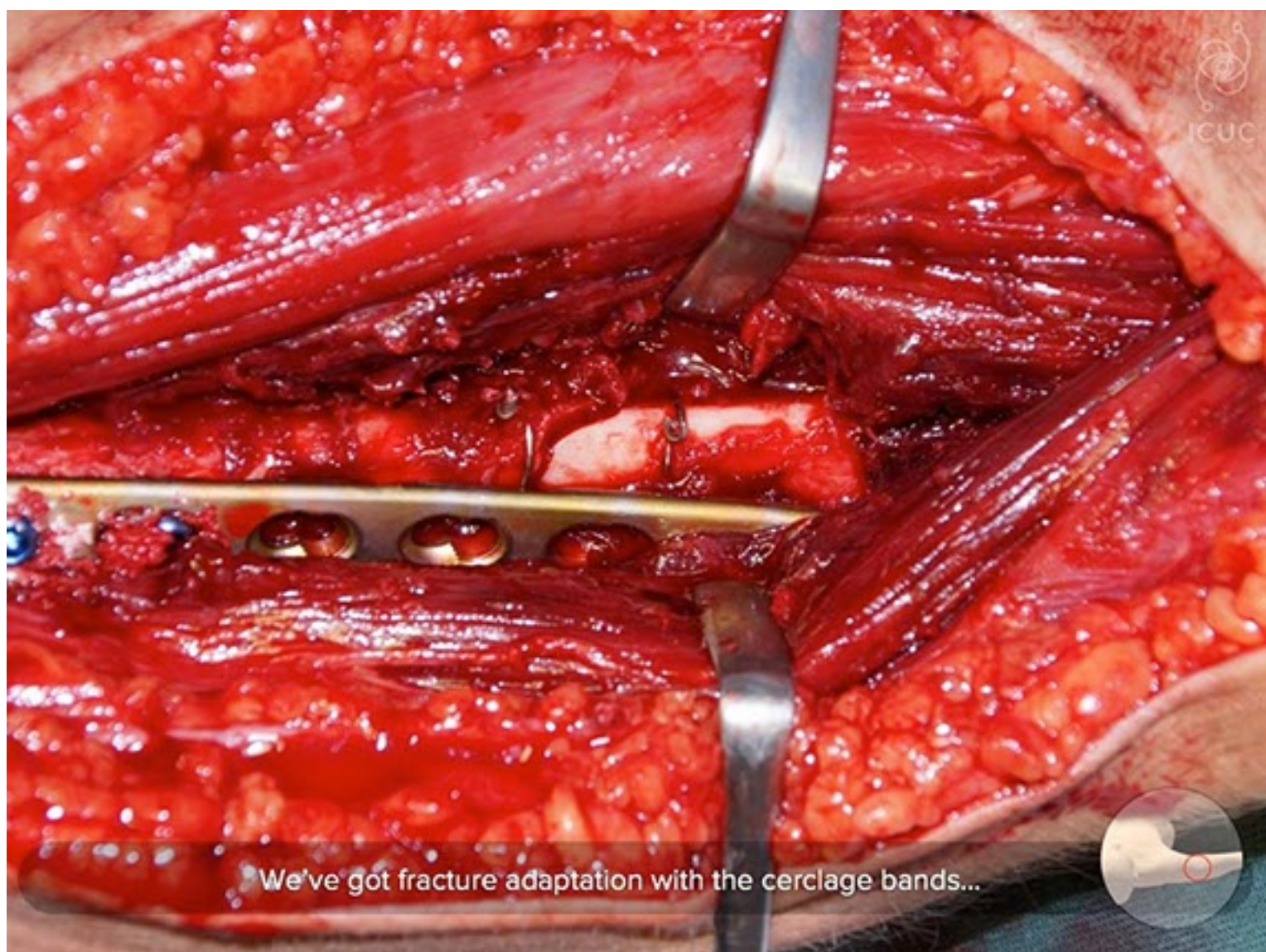




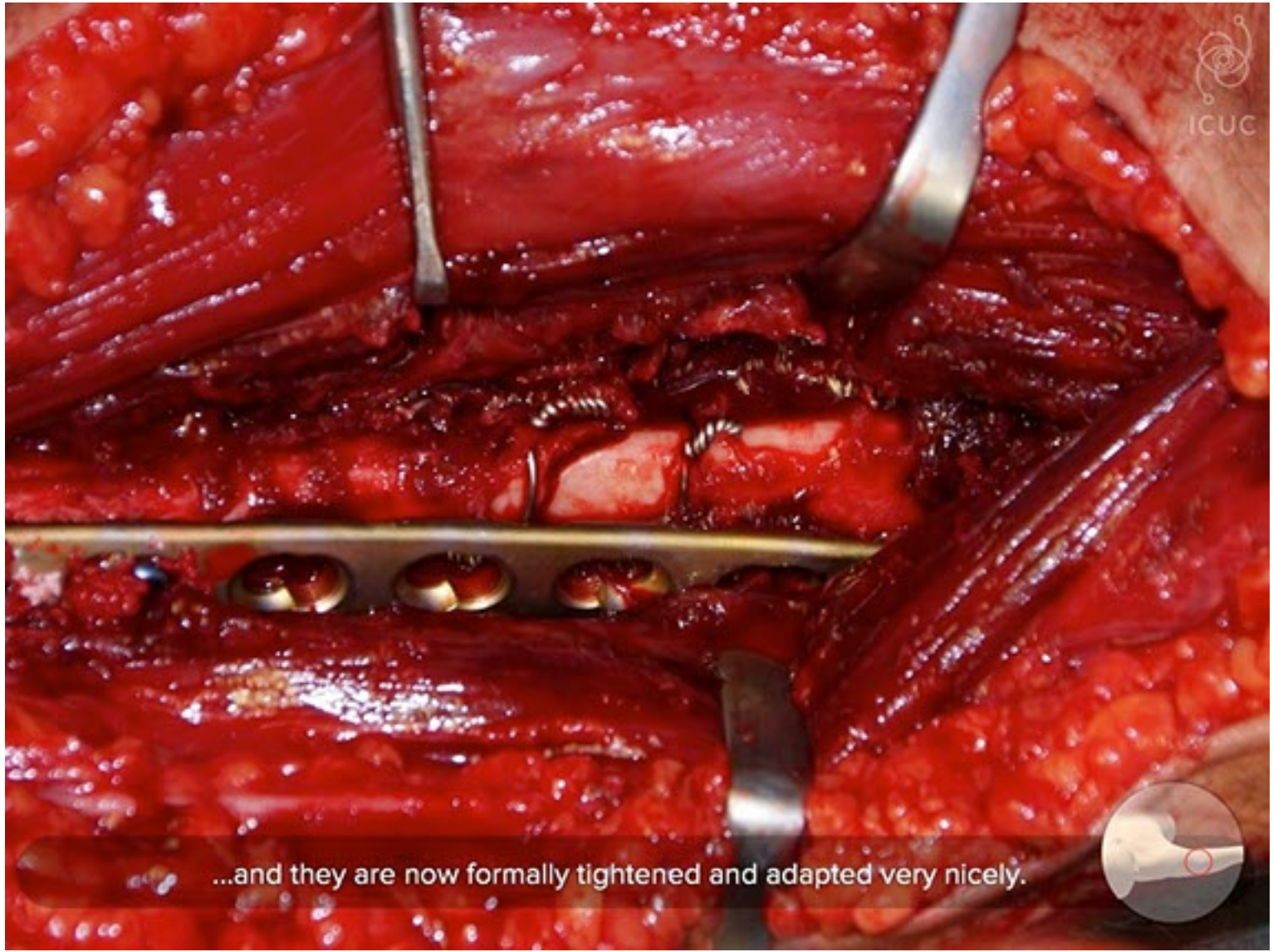
We've got three screws proximally.



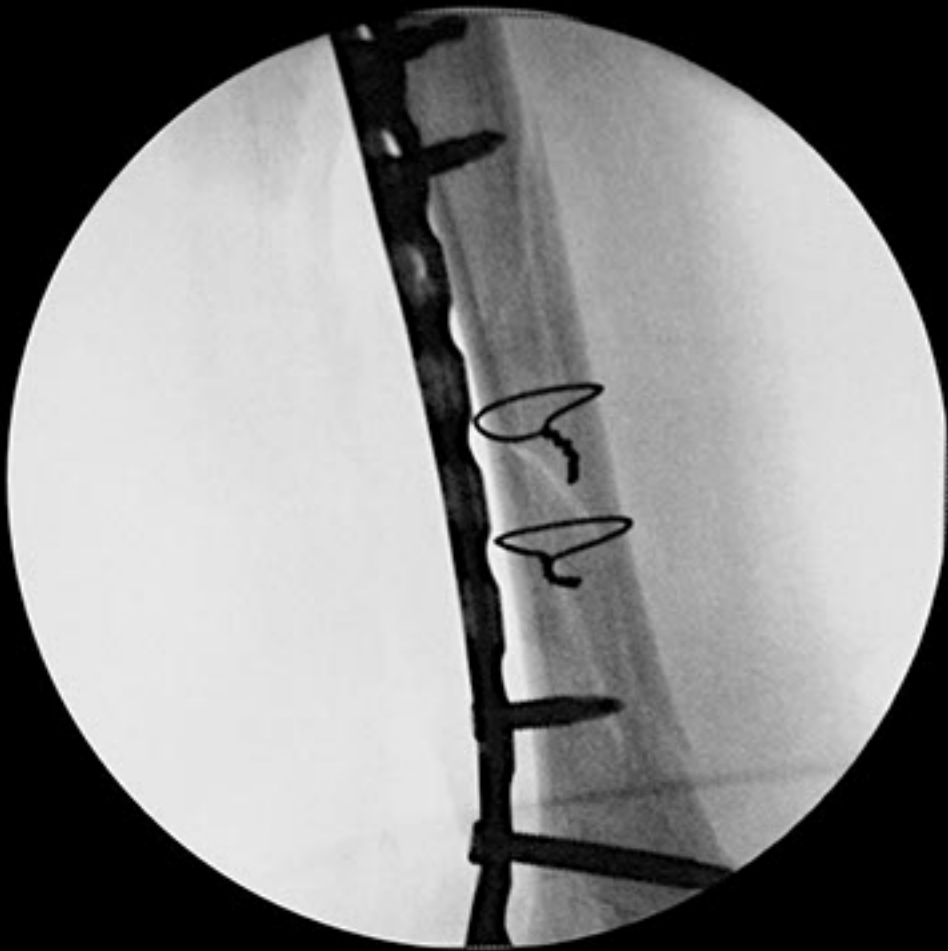

We've got fracture adaptation with the cerclage bands...

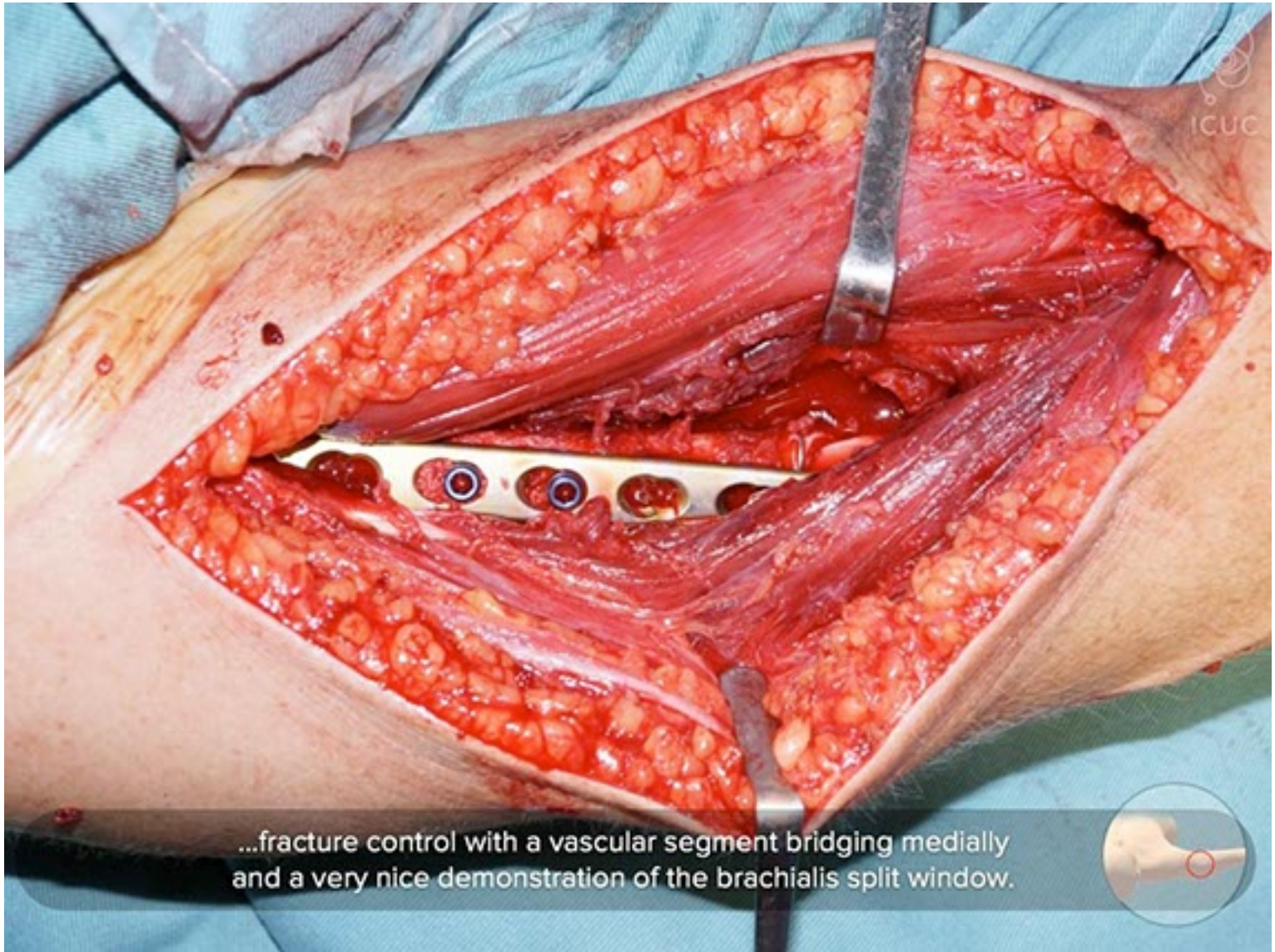


...and they are now formally tightened and adapted very nicely.

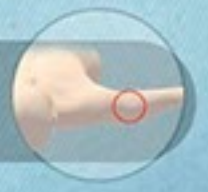

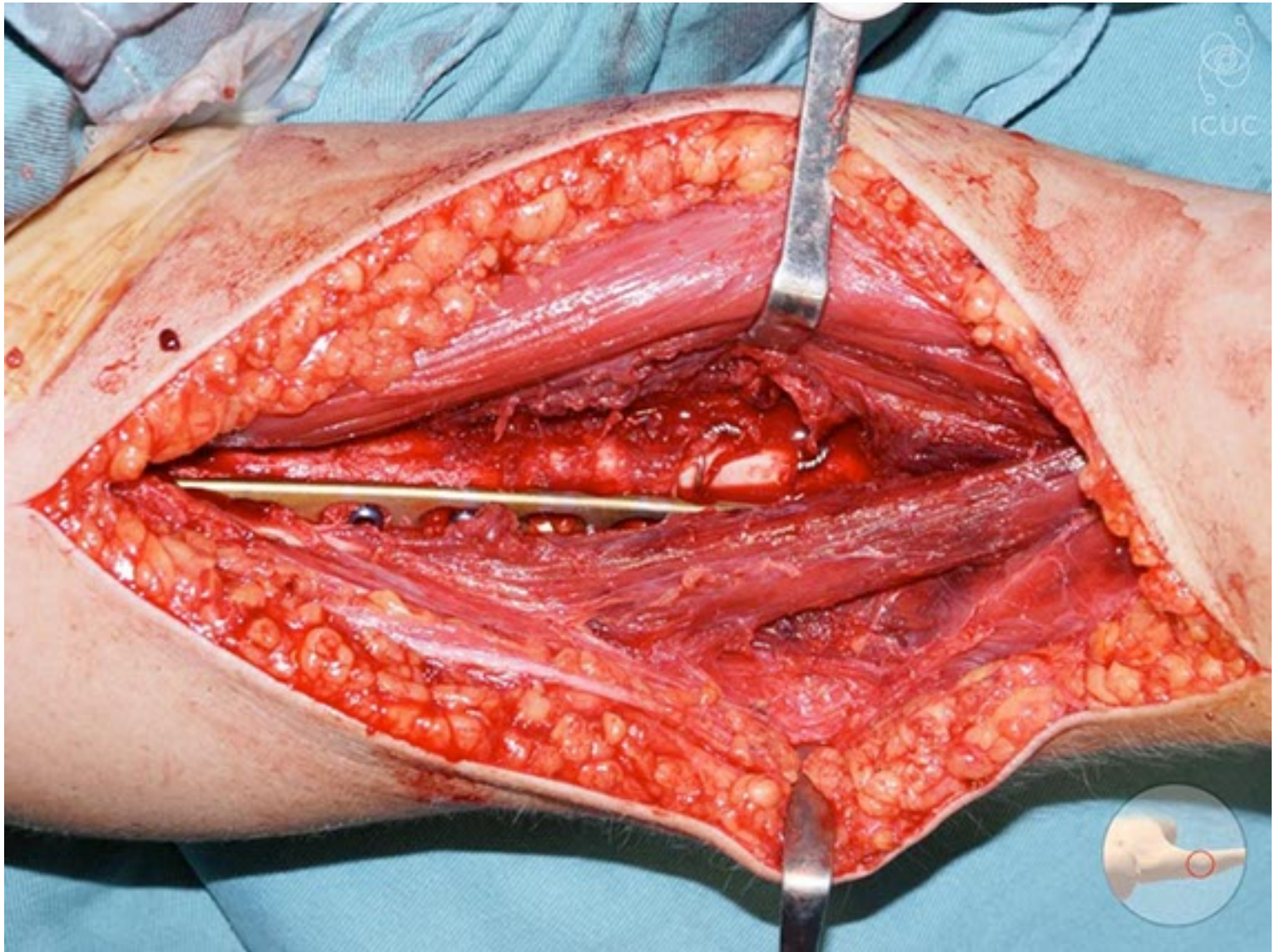


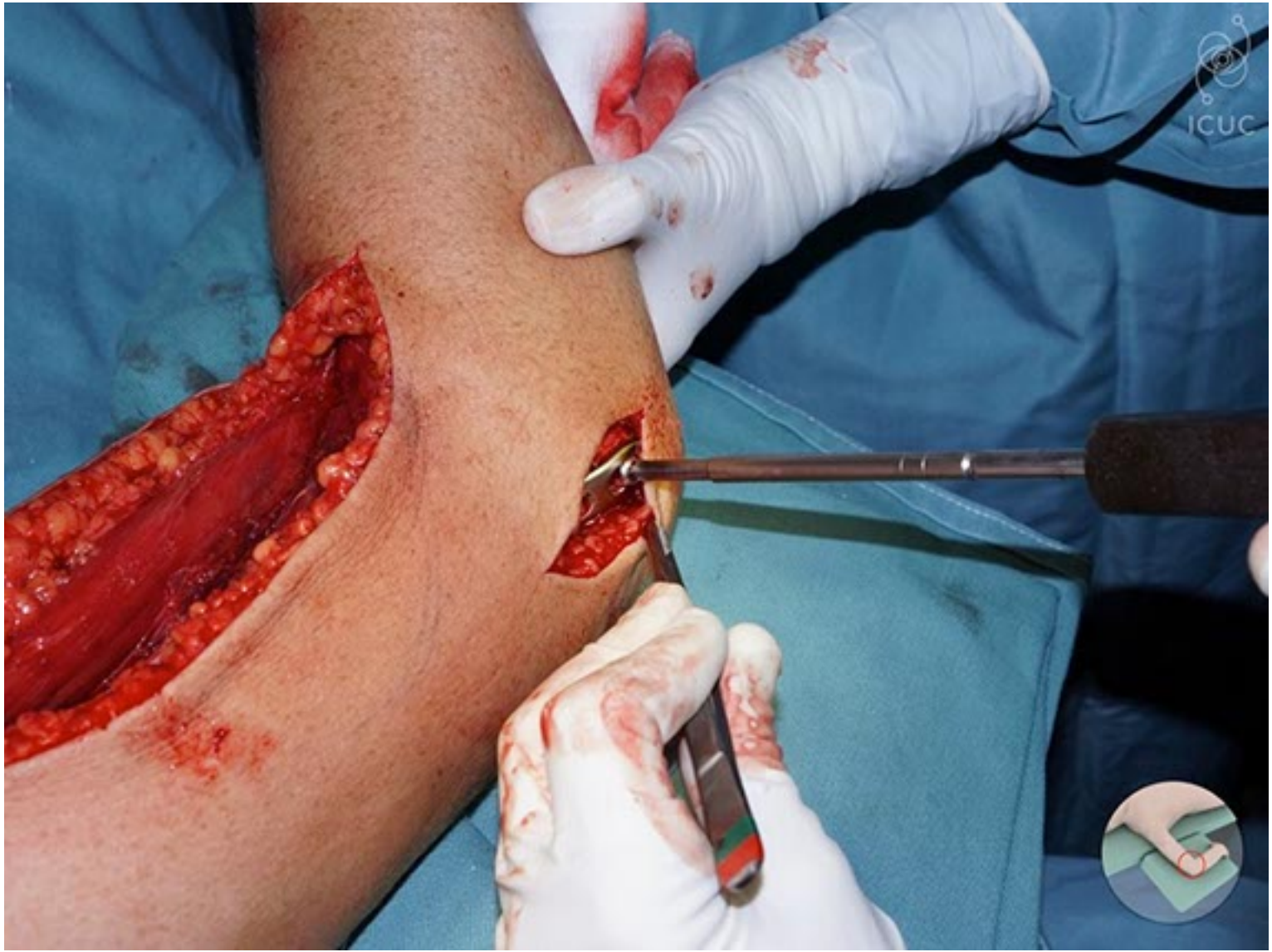
Completely fracture fixation with balanced fixation, proximally, distally,...

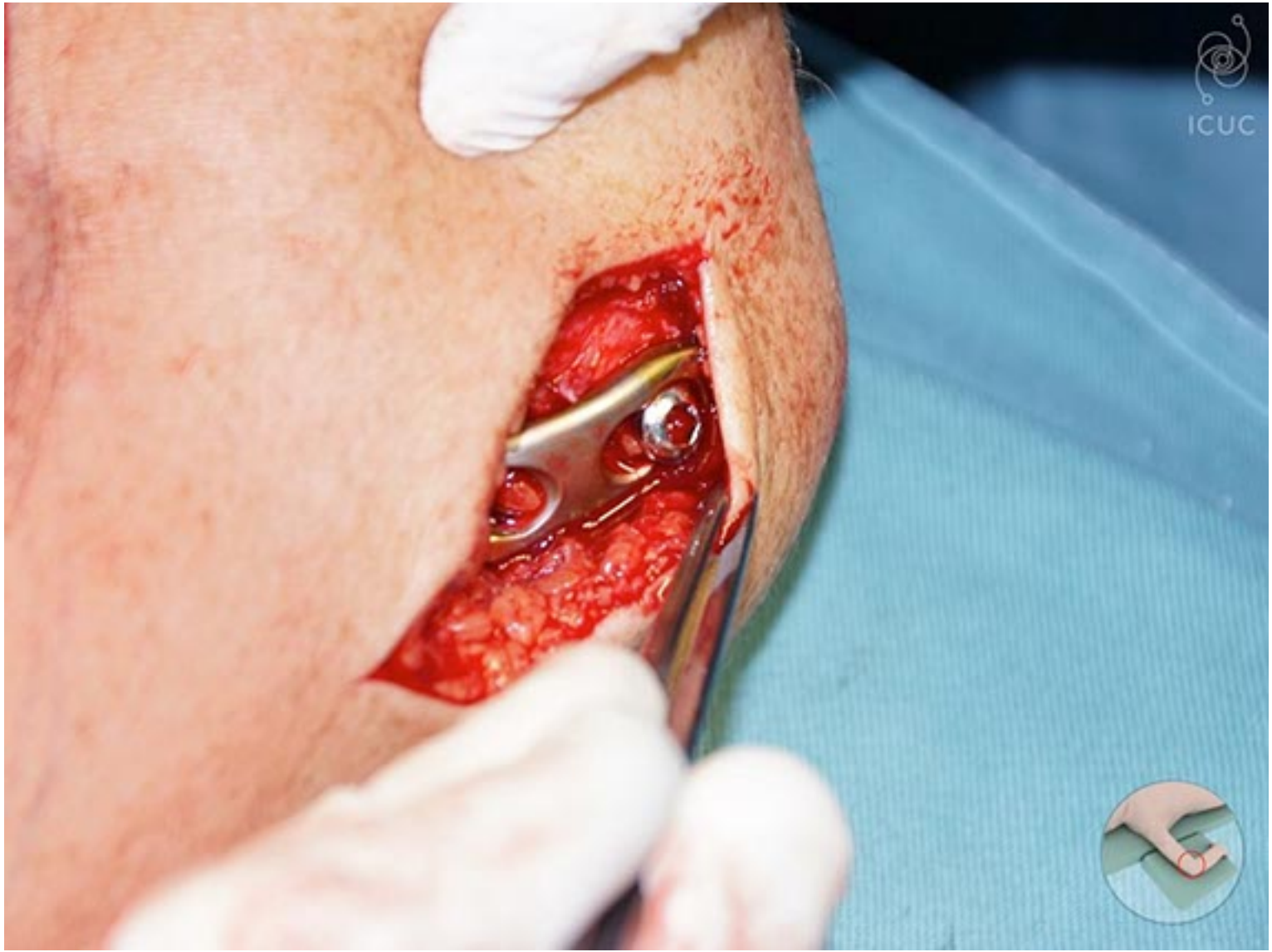

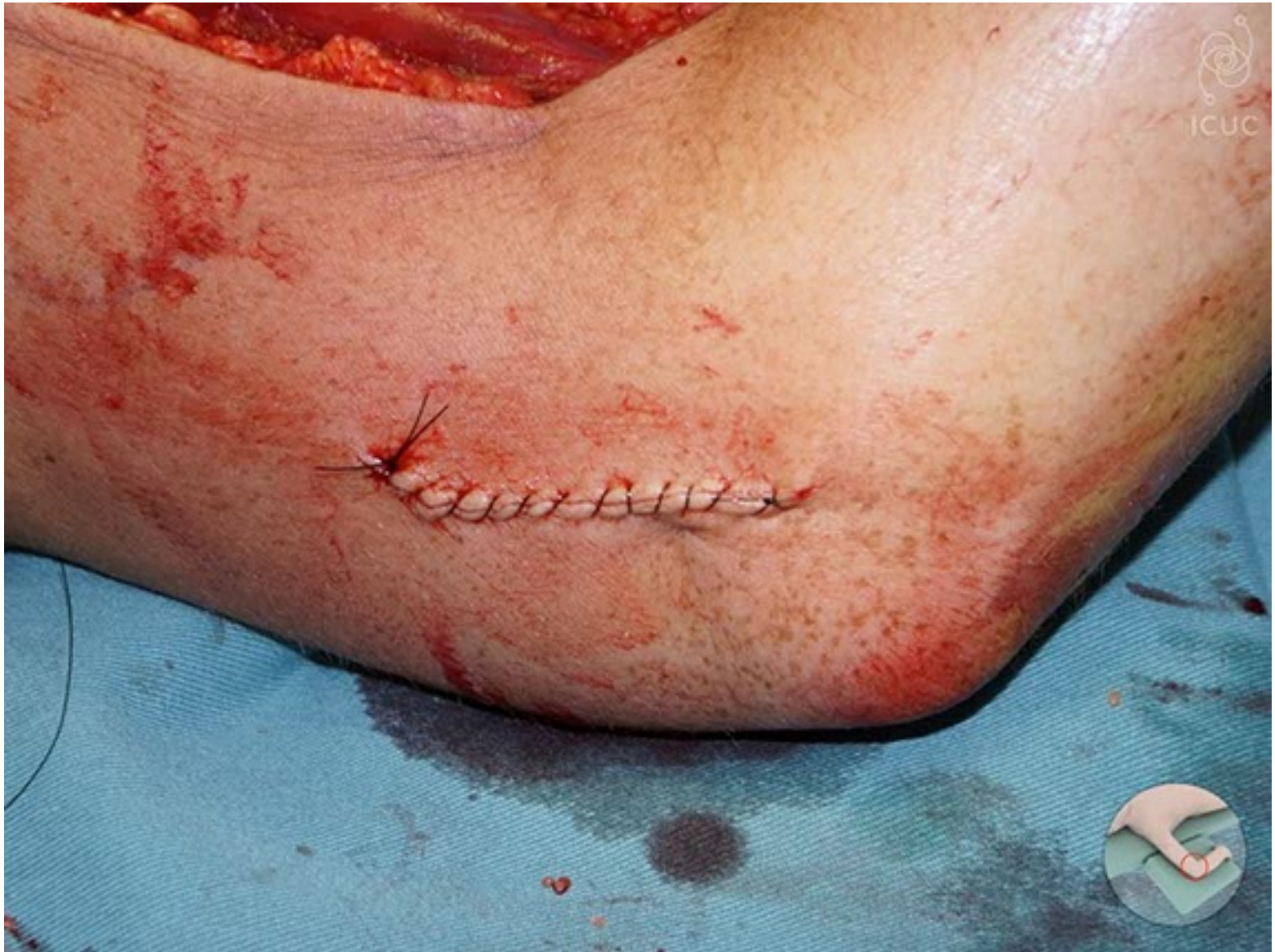...fracture control with a vascular segment bridging medially and a very nice demonstration of the brachialis split window.

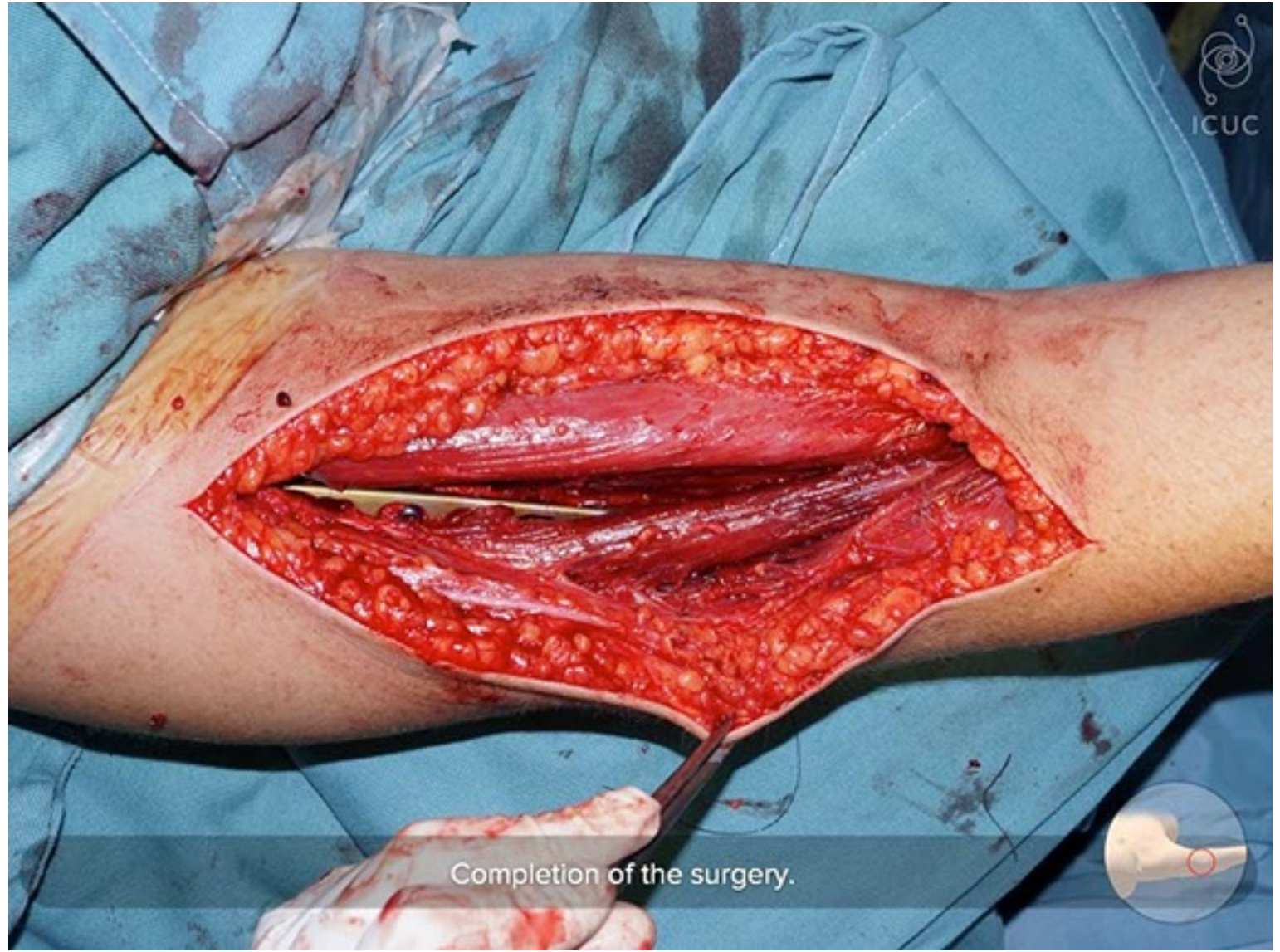




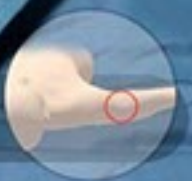
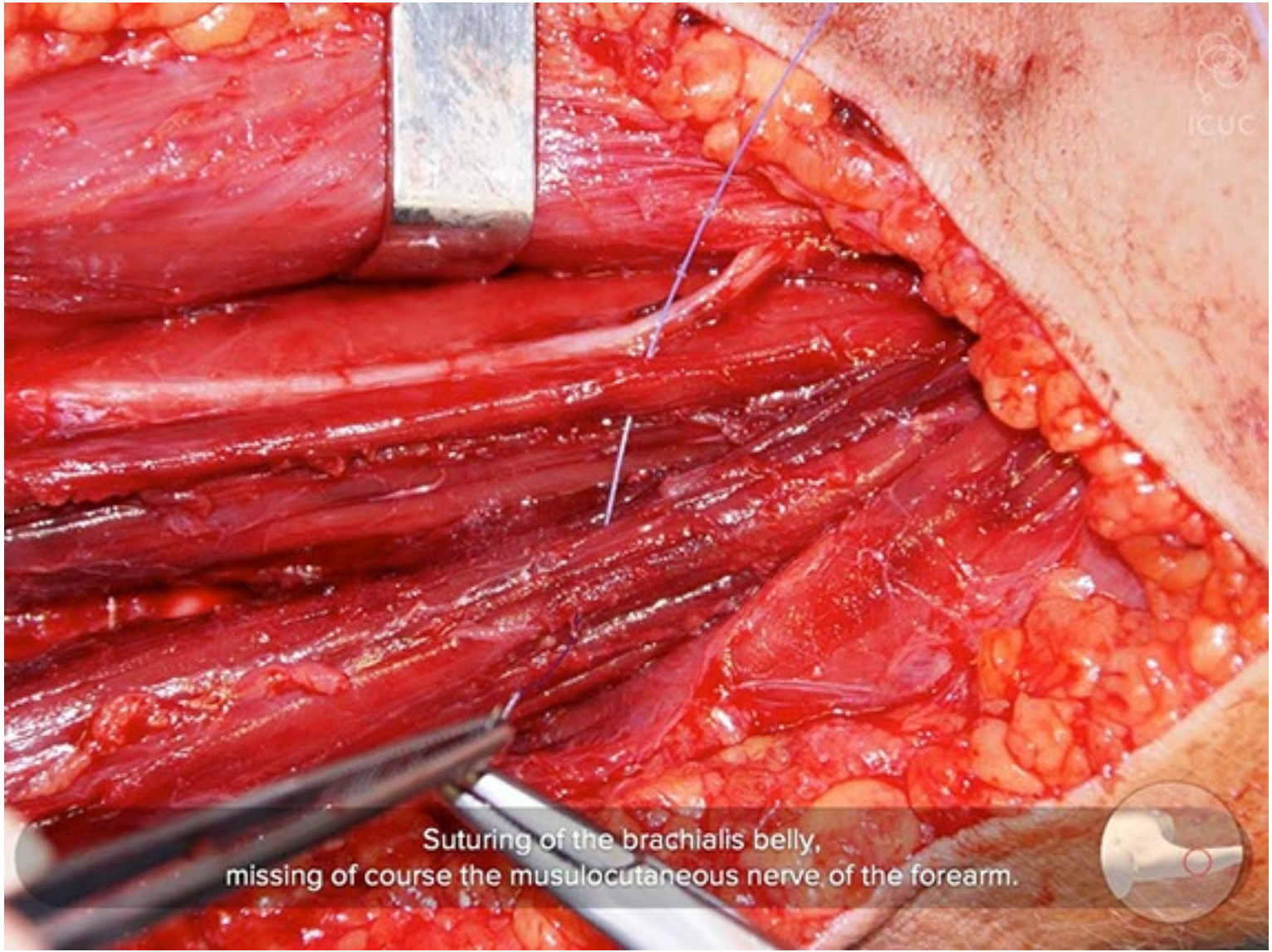






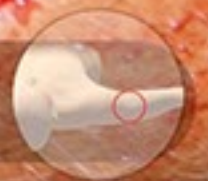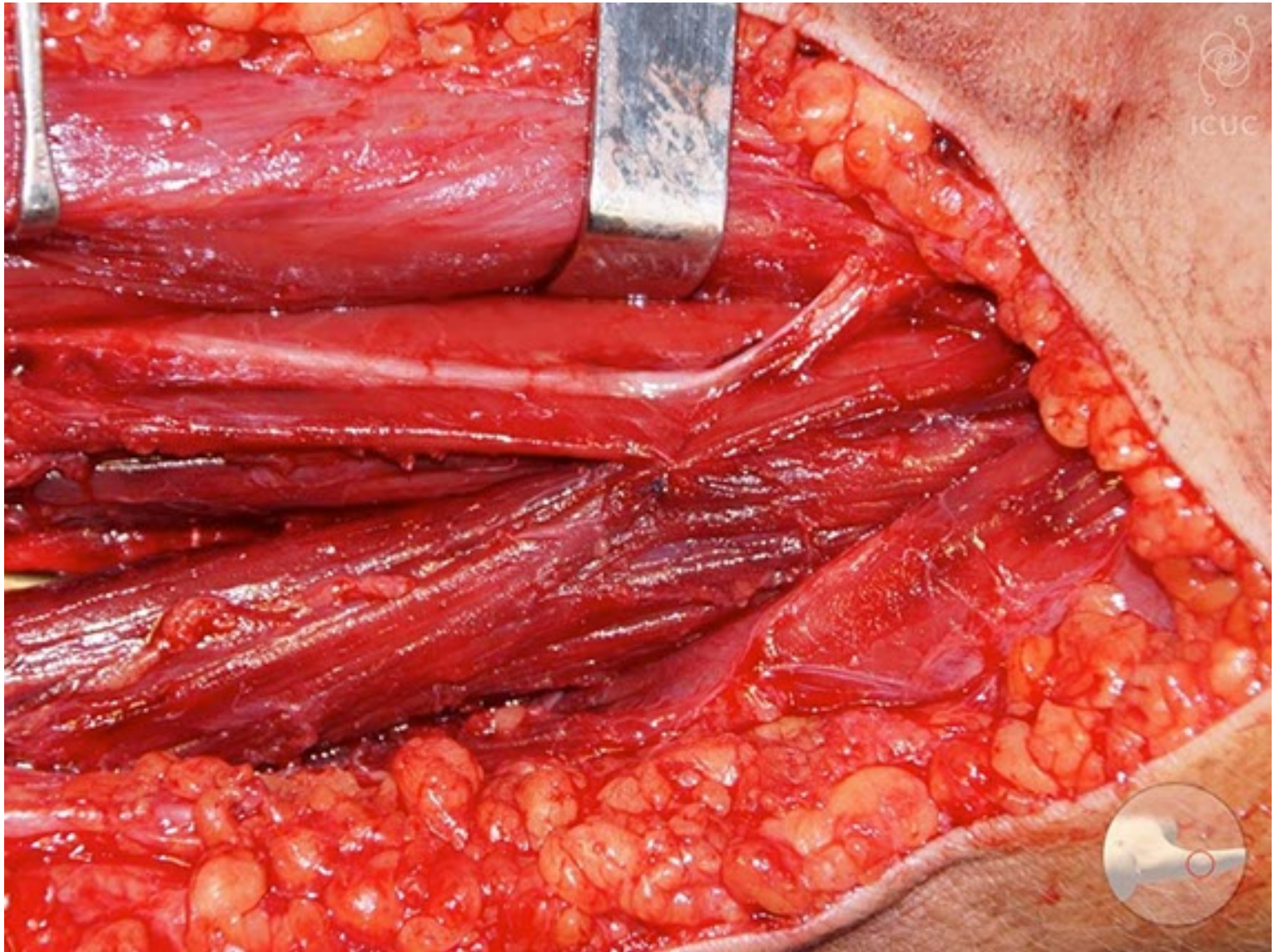
Completion of the surgery.

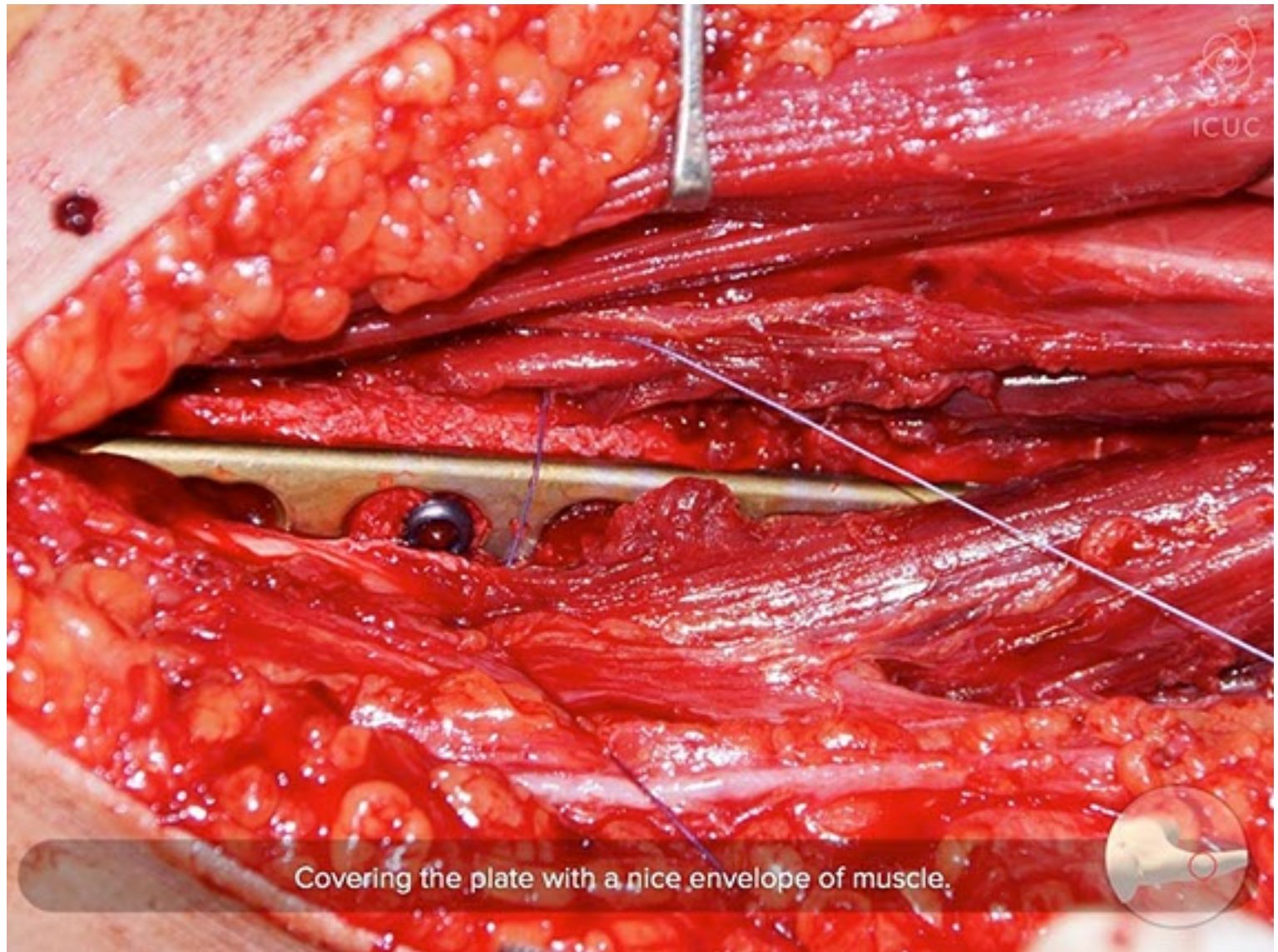




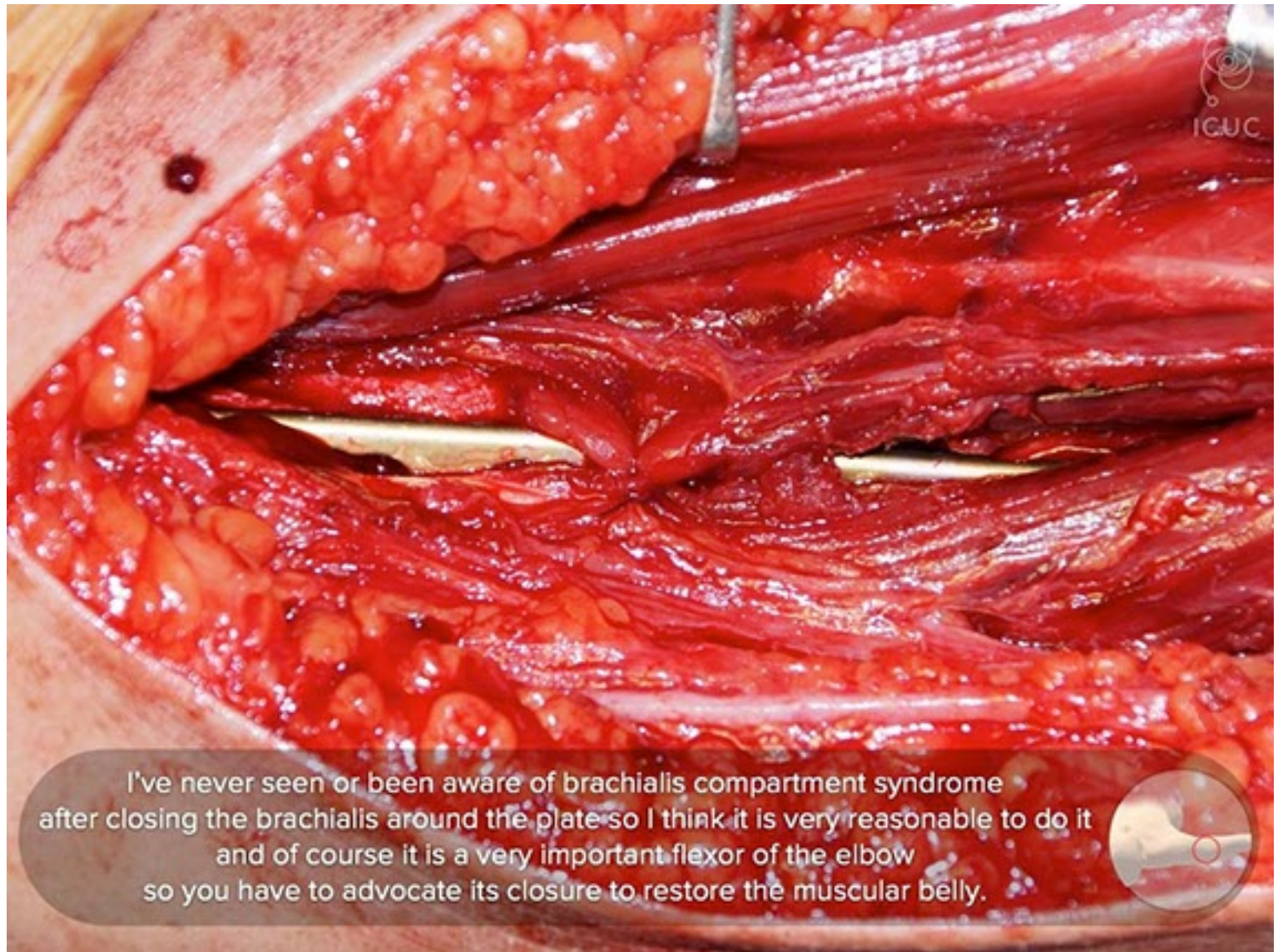Suturing of the brachialis belly,
missing of course the musculocutaneous nerve of the forearm.



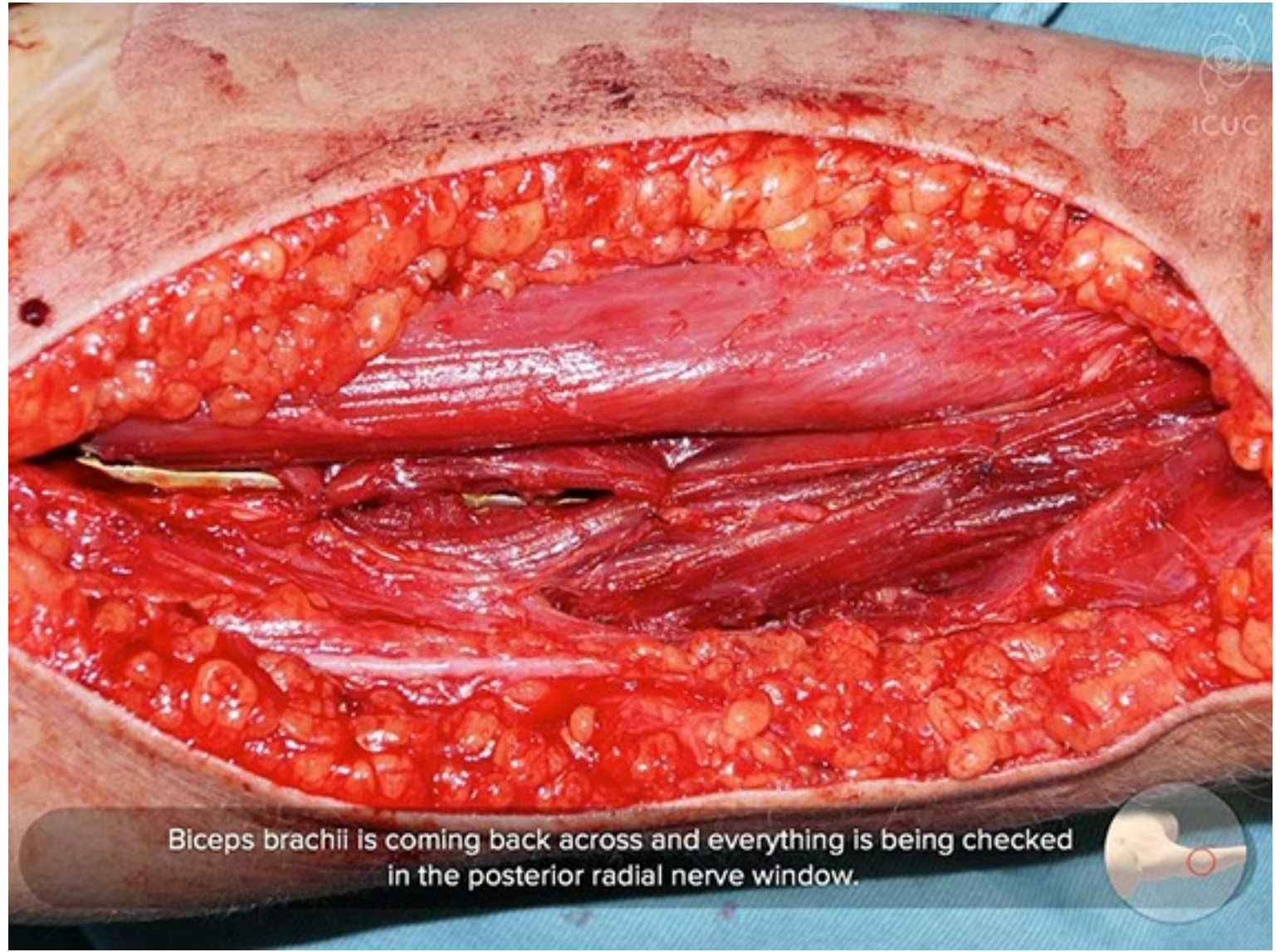




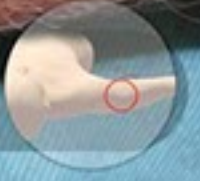Covering the plate with a nice envelope of muscle.

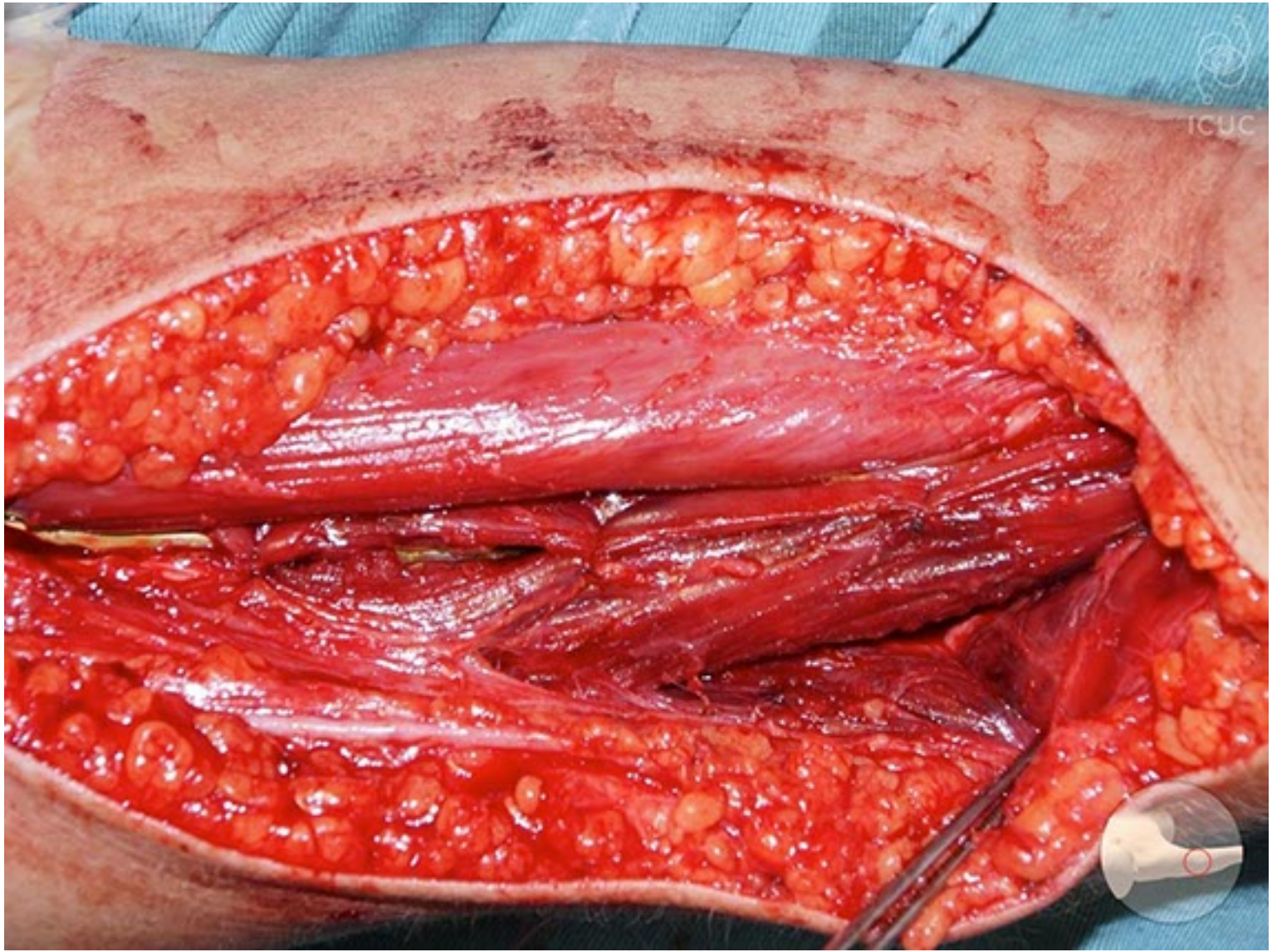

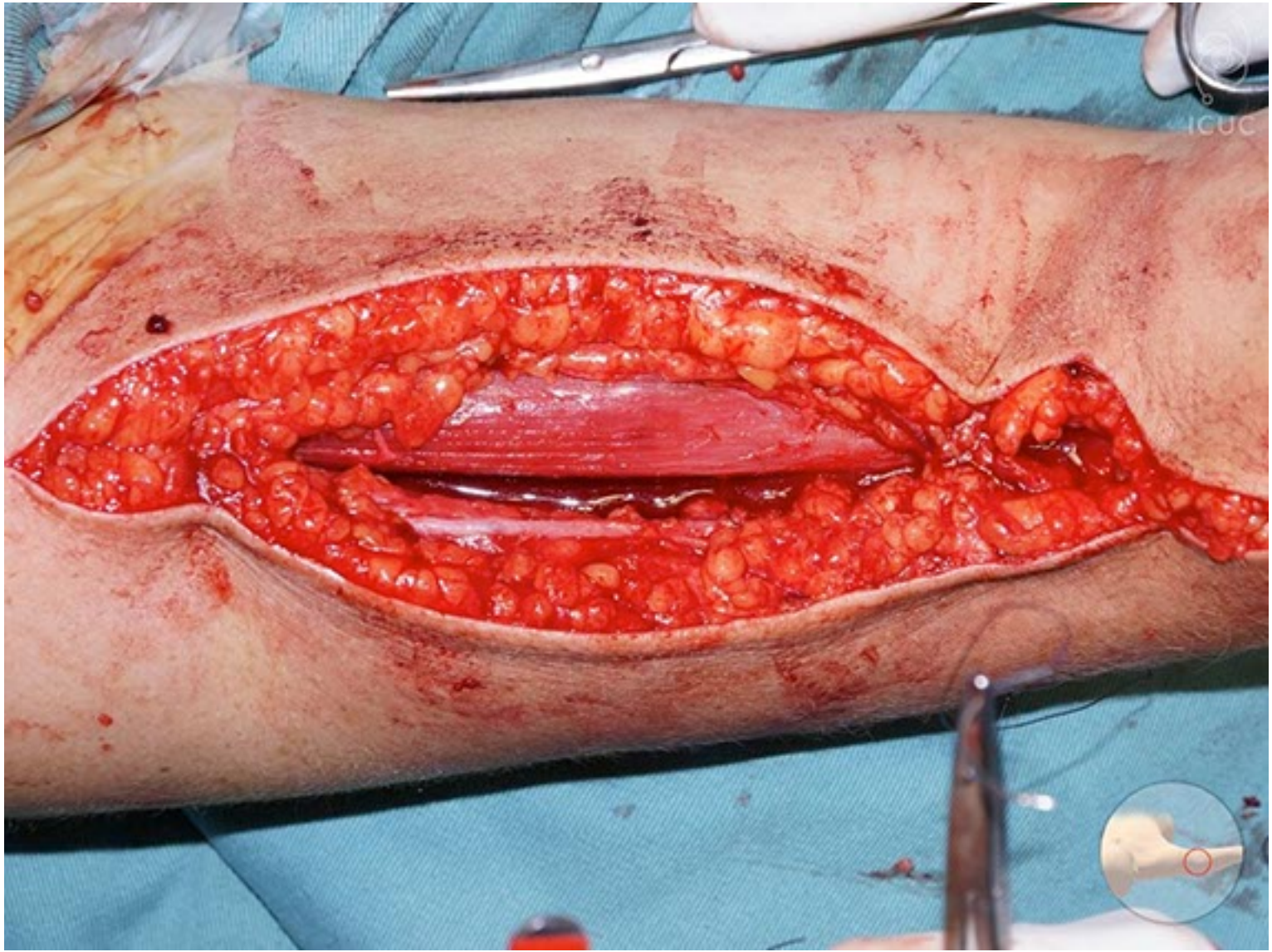I've never seen or been aware of brachialis compartment syndrome after closing the brachialis around the plate so I think it is very reasonable to do it and of course it is a very important flexor of the elbow so you have to advocate its closure to restore the muscular belly.

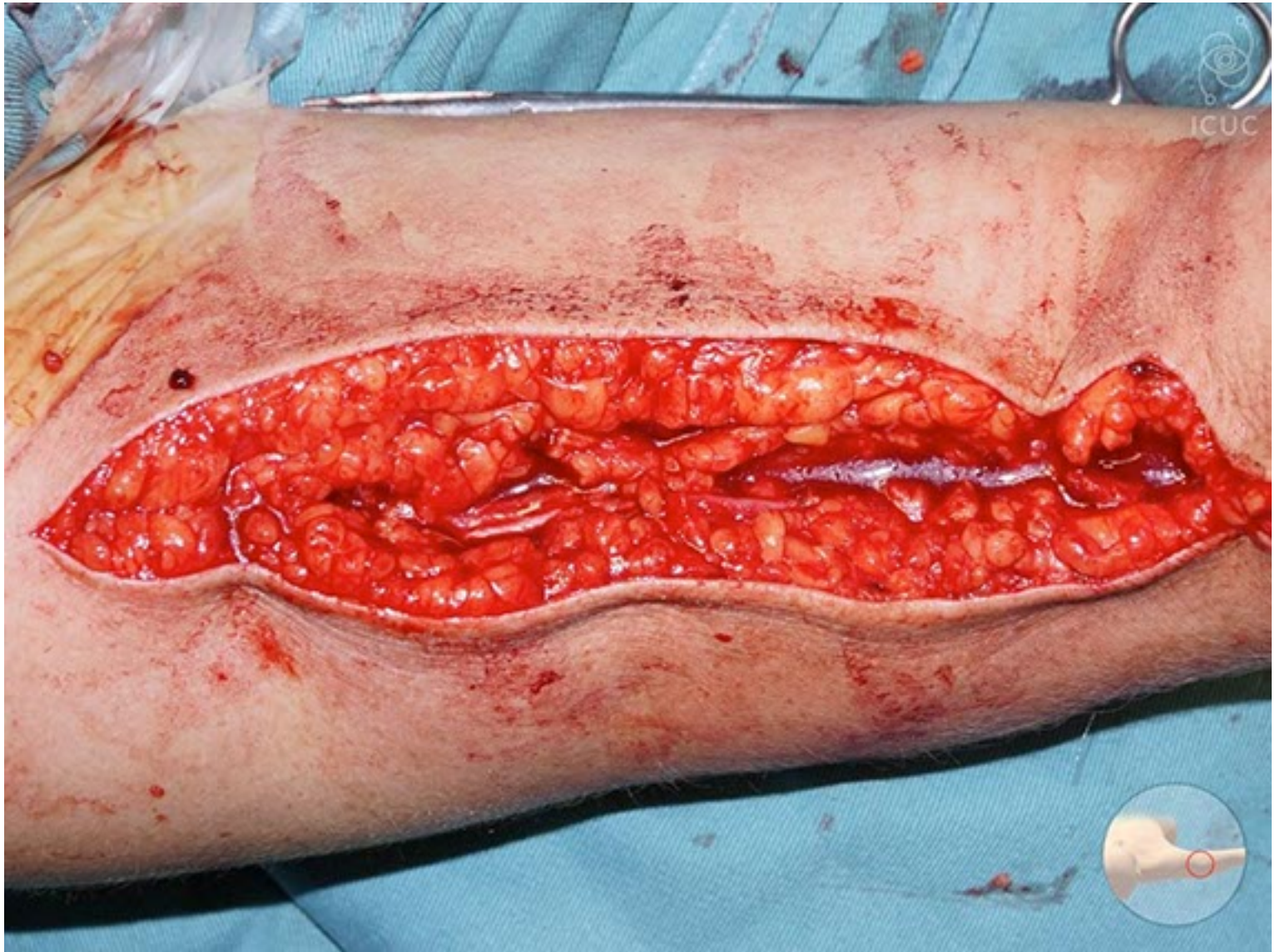

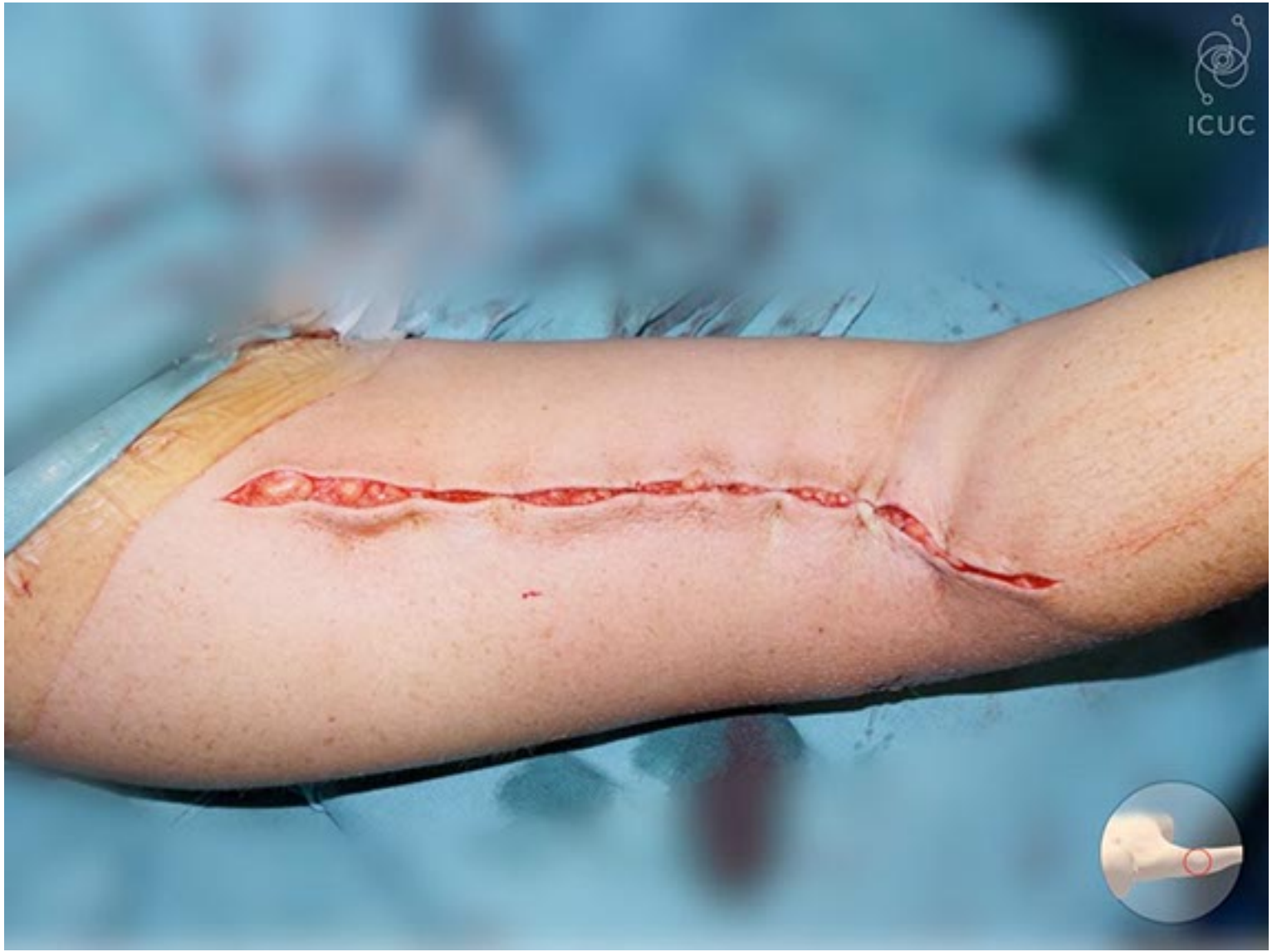Biceps brachii is coming back across and everything is being checked in the posterior radial nerve window.

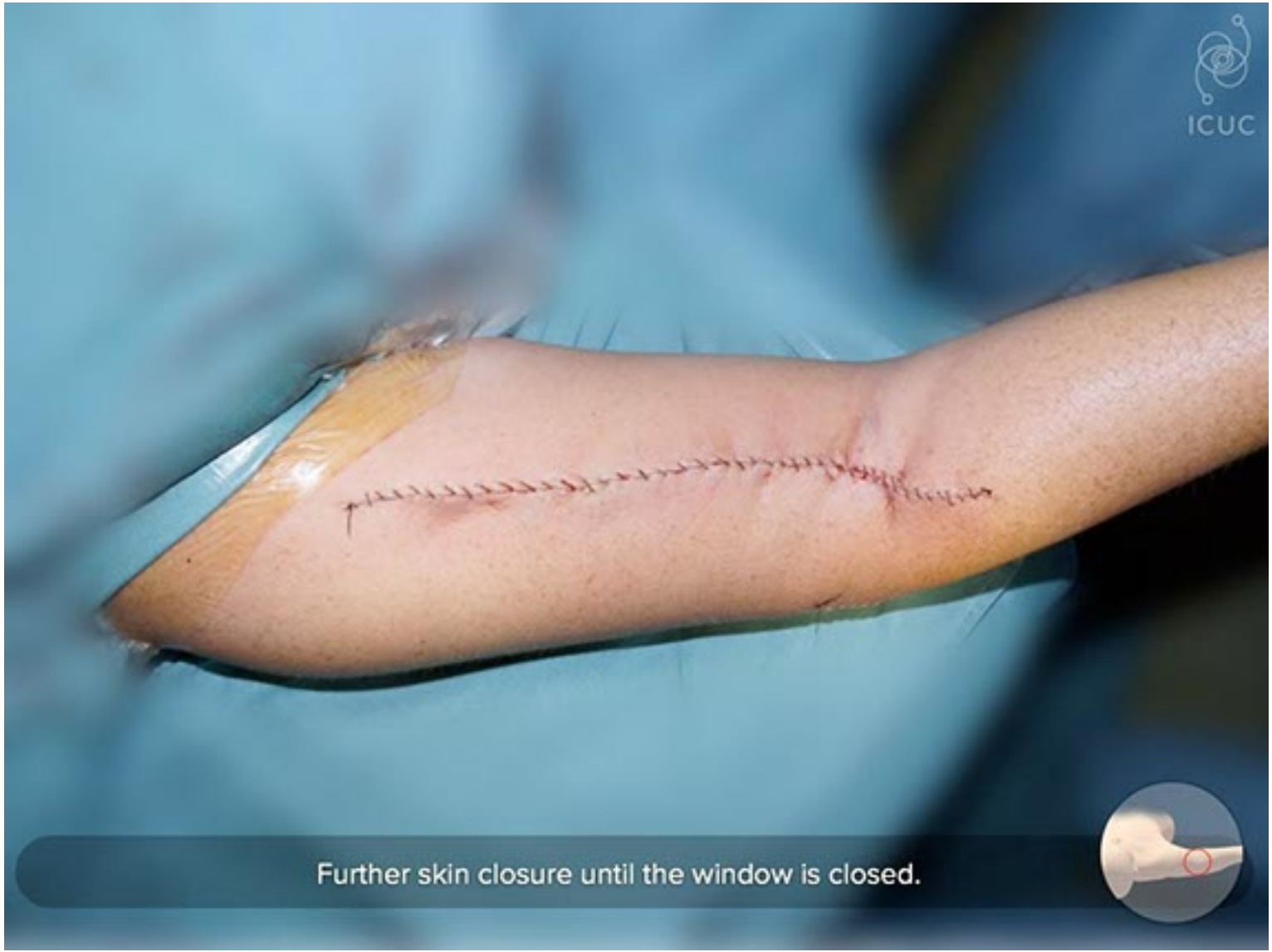




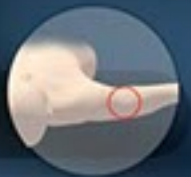


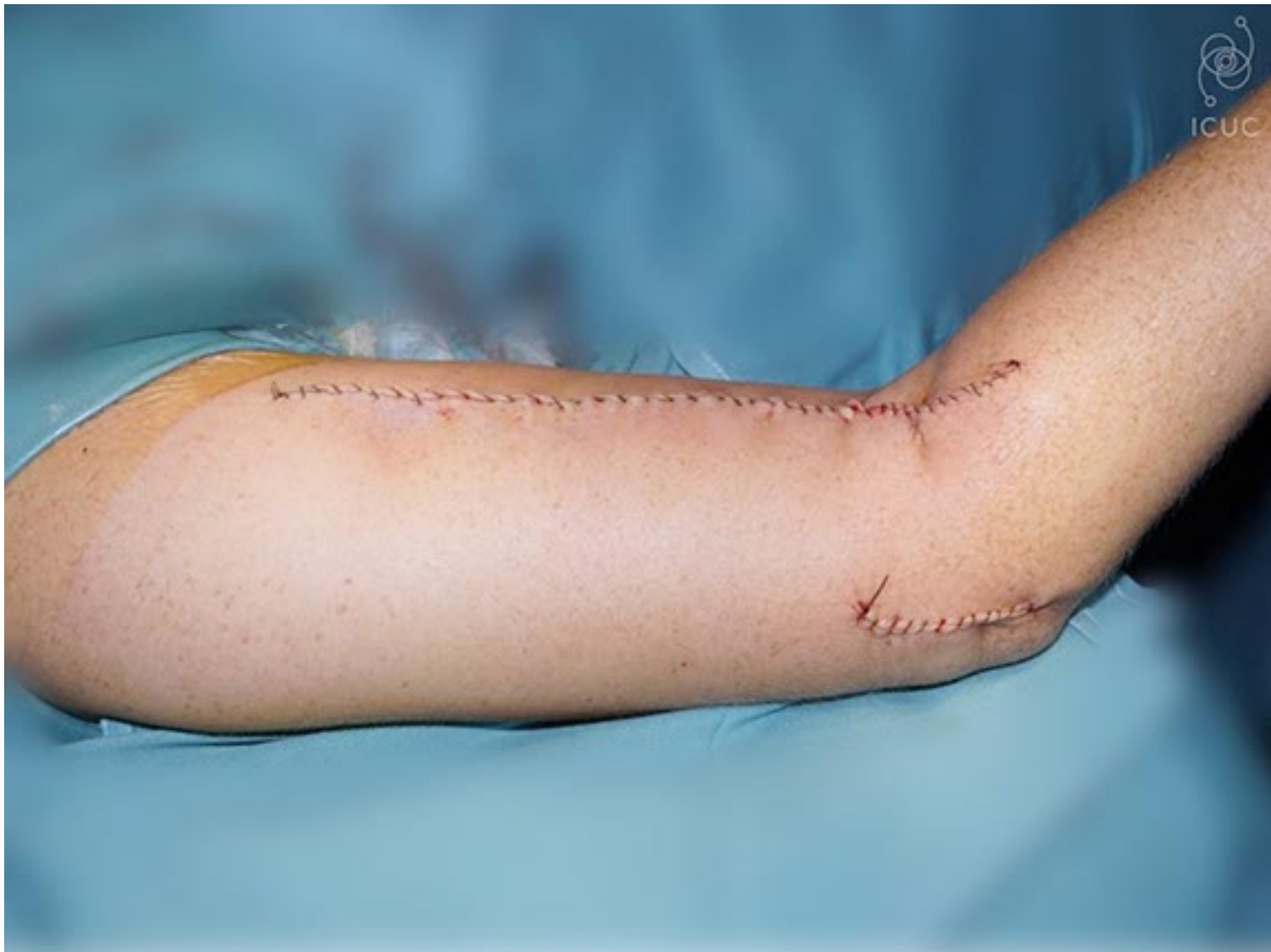


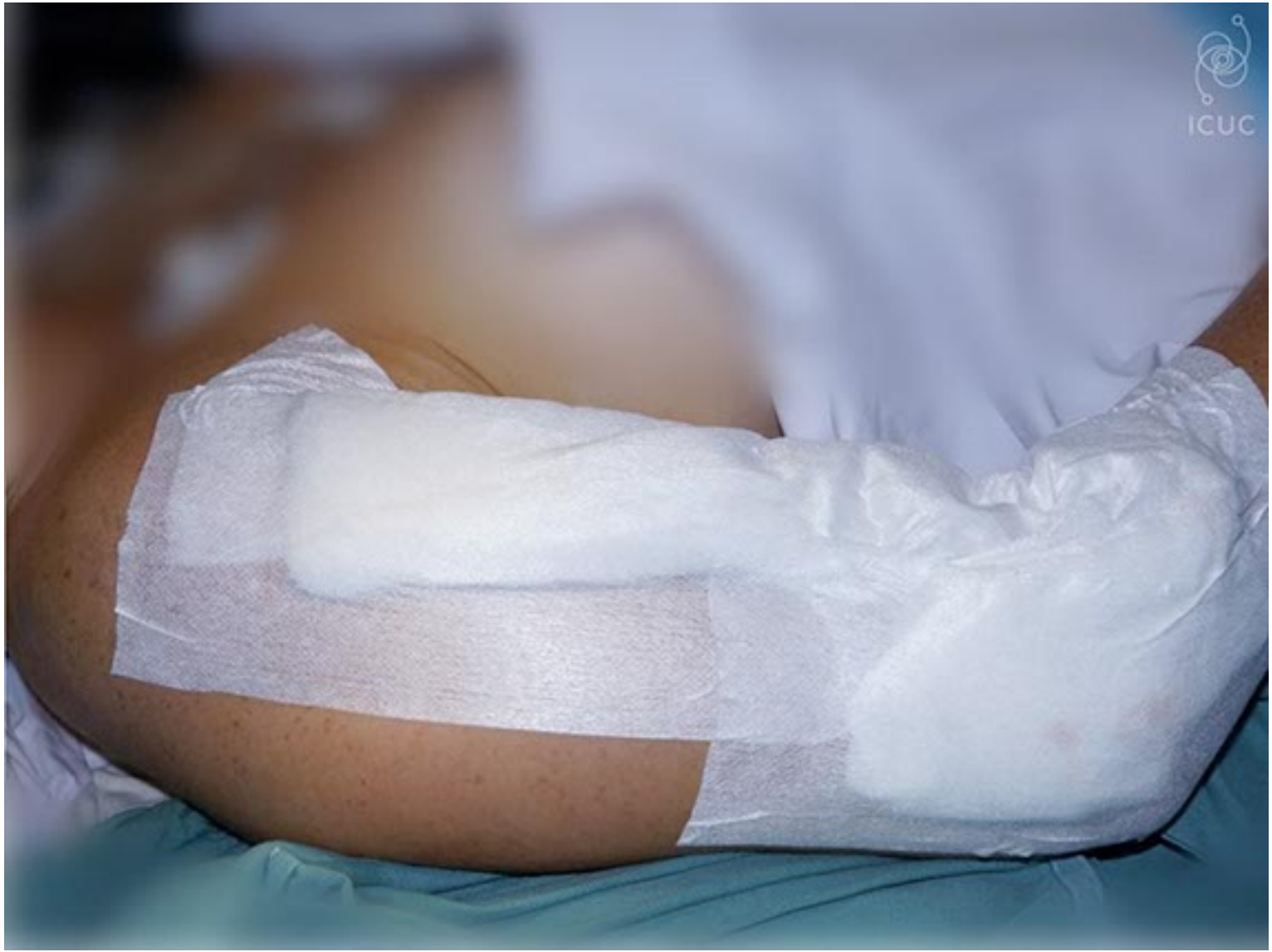
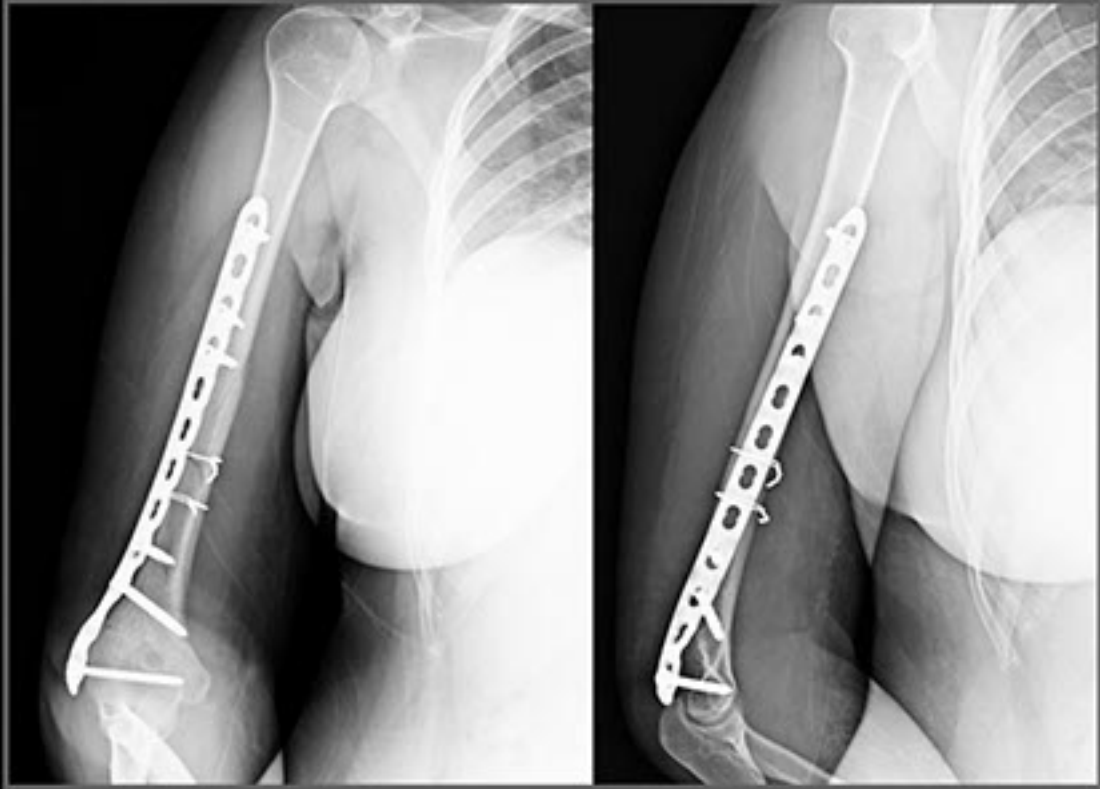
Further skin closure until the window is closed.





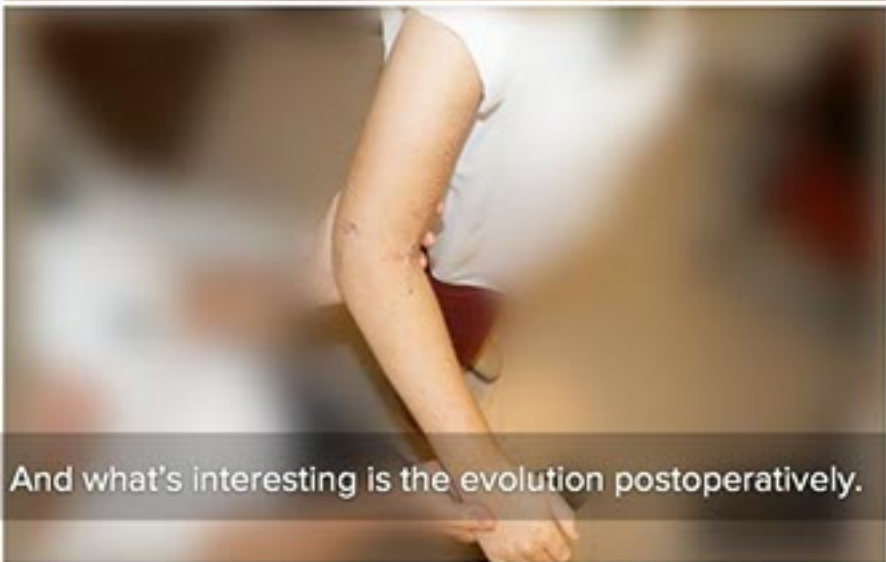
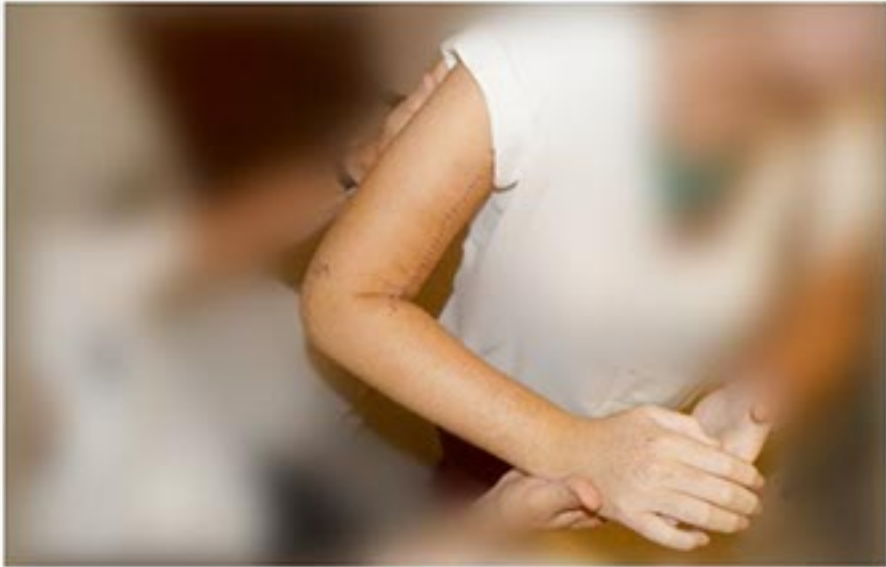
0w



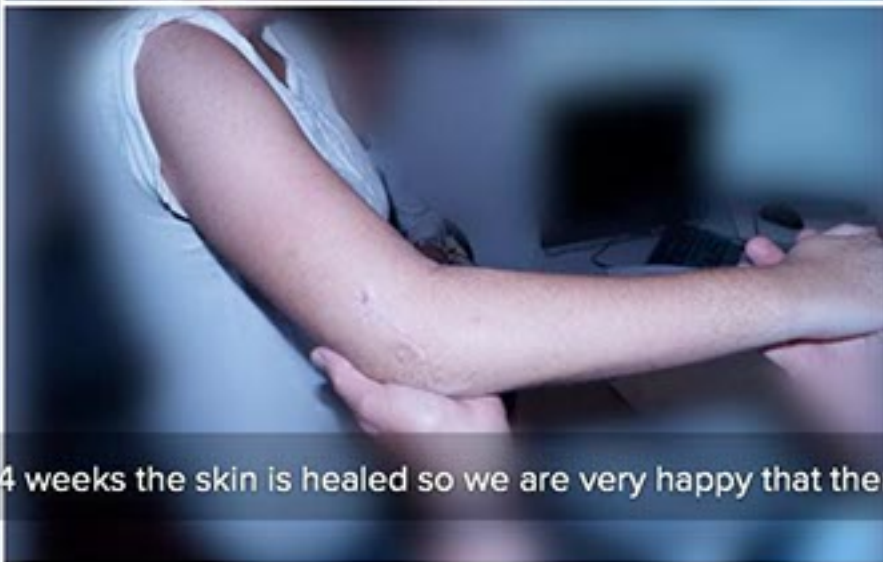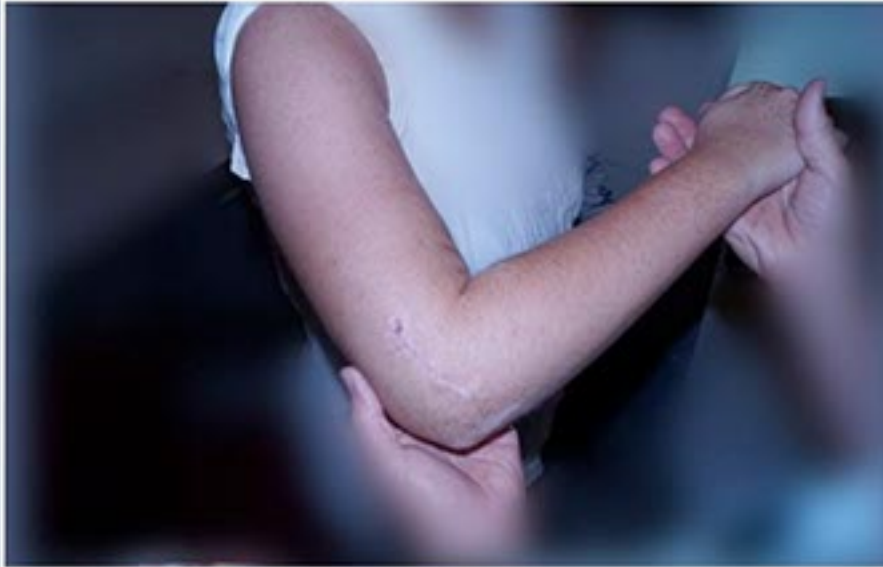Very nice fixation of the anterolateral to posterolateral plate.
We know where the radial nerve is, it is immediately over the head of the upper most distal locking screw or just perhaps behind it.
We know that the cerclage bands are not close to the radial nerve because the radial nerve has been seen. So this is a safe technique employing this fenestration of muscles and the septum with a very nice alignment.

3w



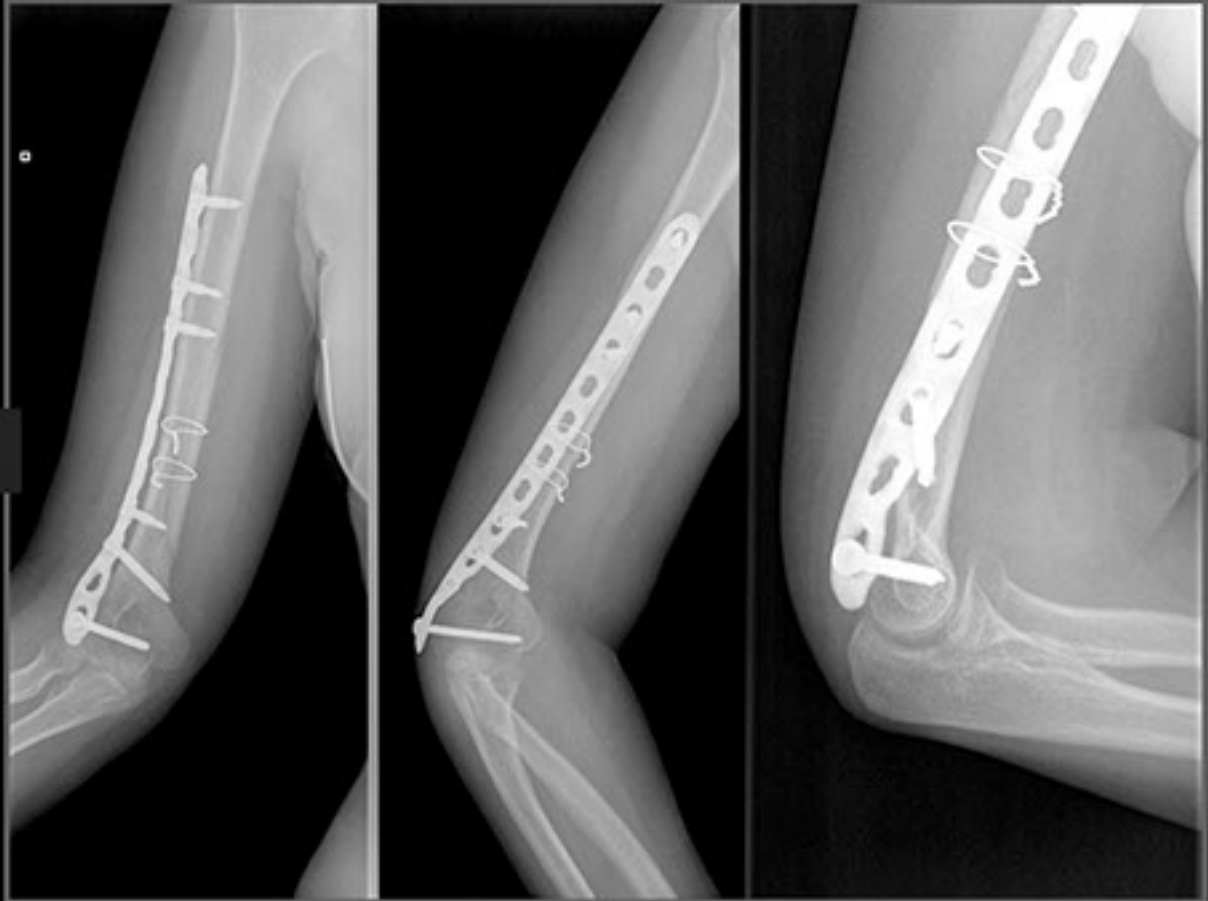
And what's interesting is the evolution postoperatively.

4w



At 3 weeks and 4 weeks the skin is healed so we are very happy that there is no infection.

7w



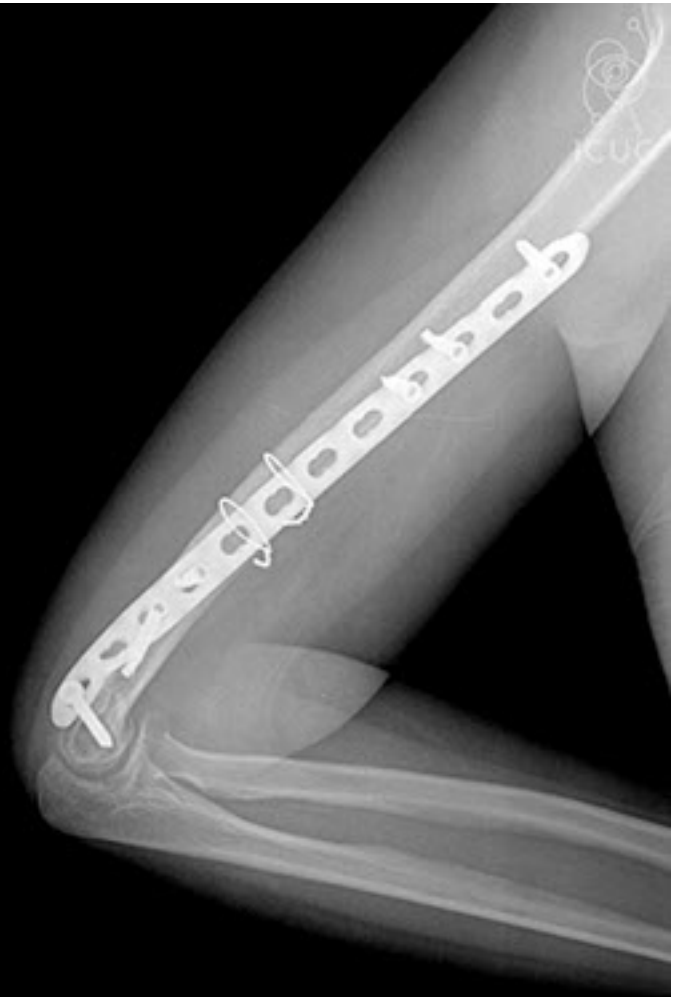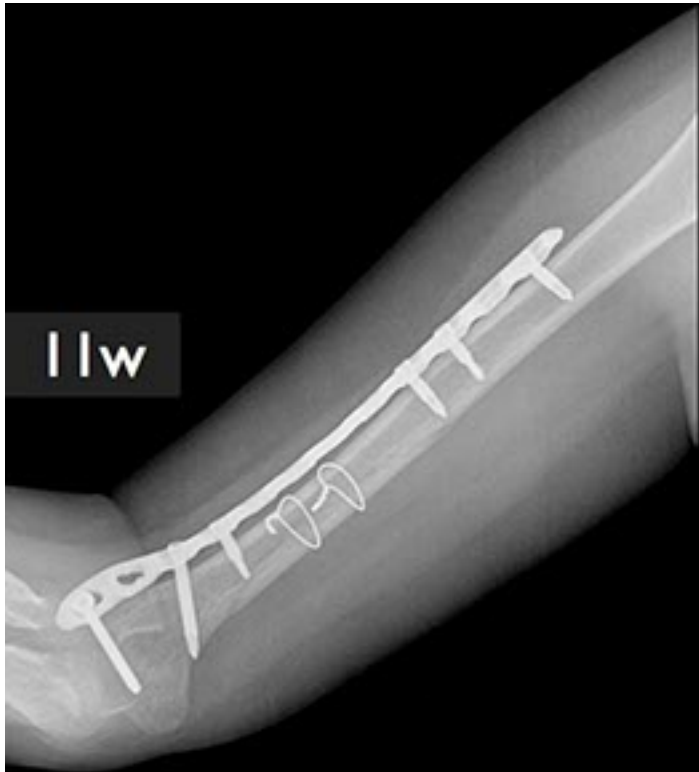At 7 weeks we're already seeing healing of the proximal and of the segmental fracture. The distal and medial are still open but the proximal is basically healed indicating super vascularity well maintained.



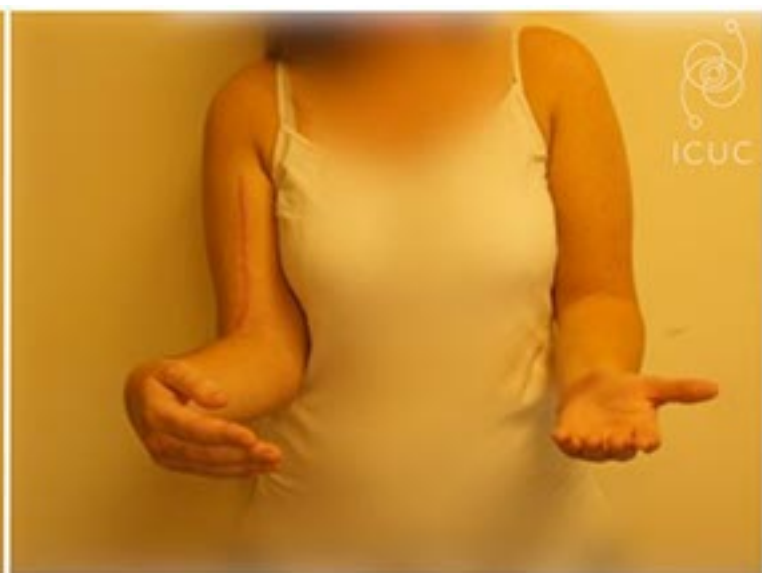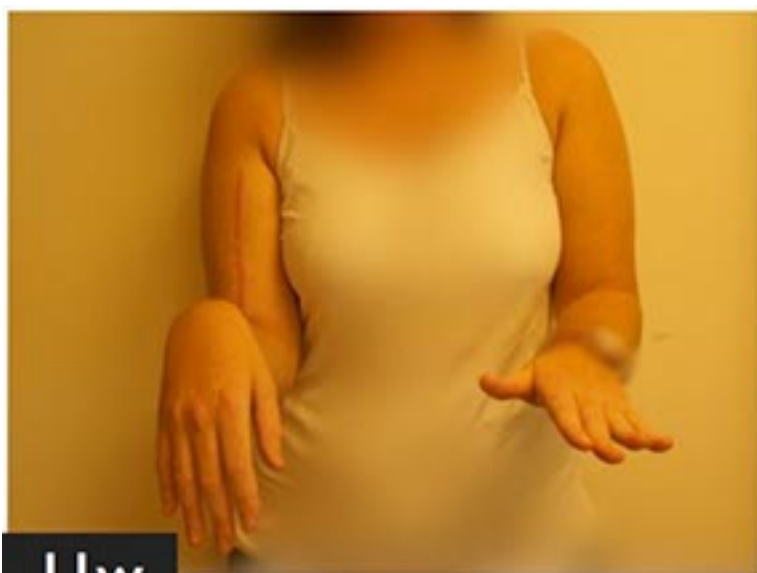ICUC



7w

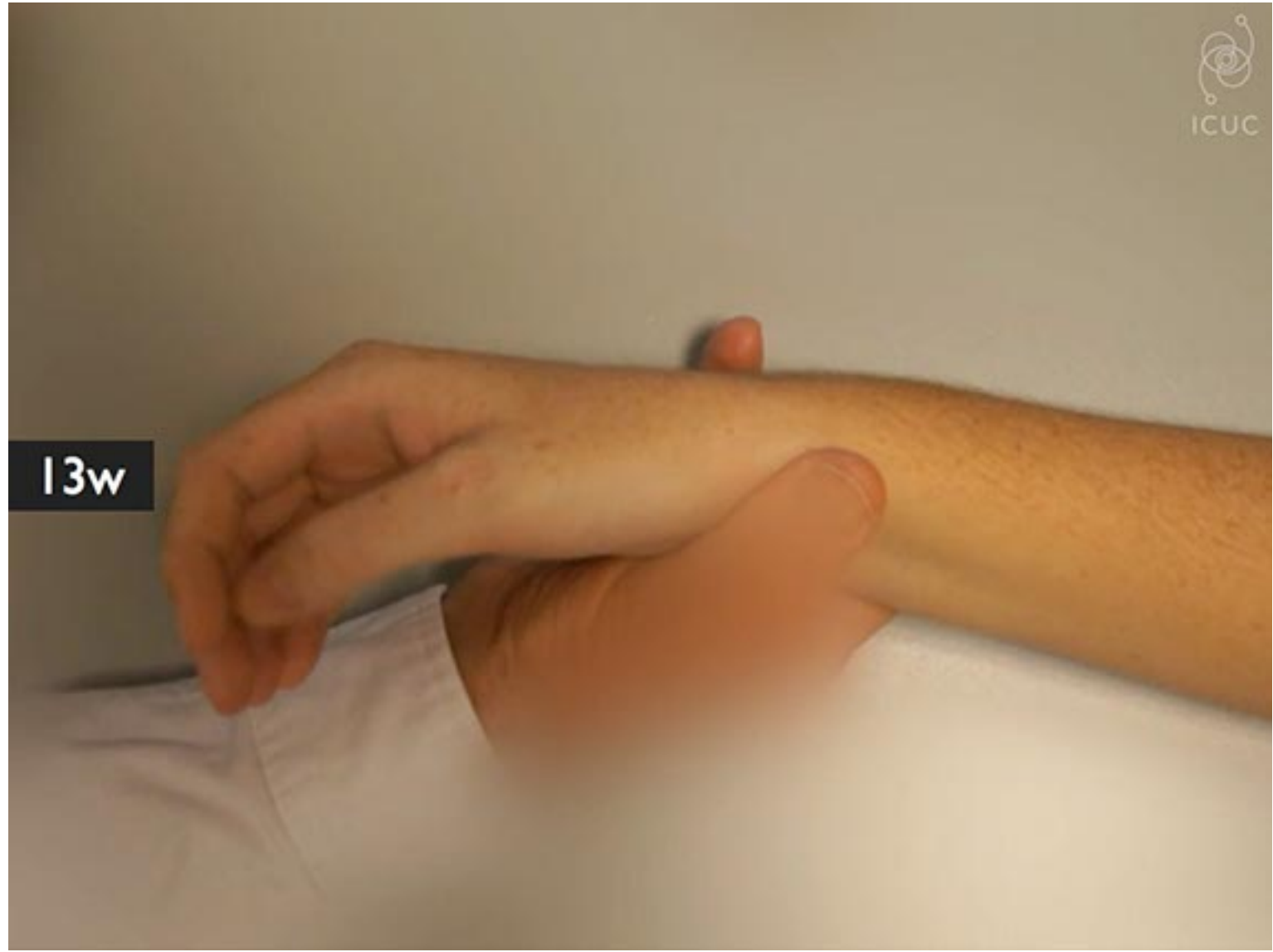

By 11 weeks the distal fracture is now healed.



Ilw

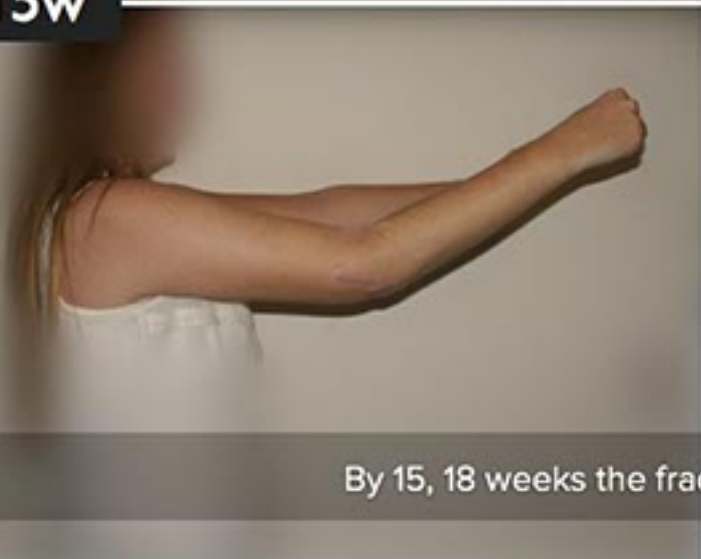




13w

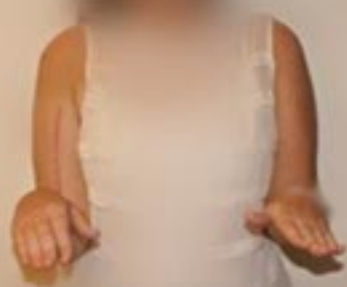

15w



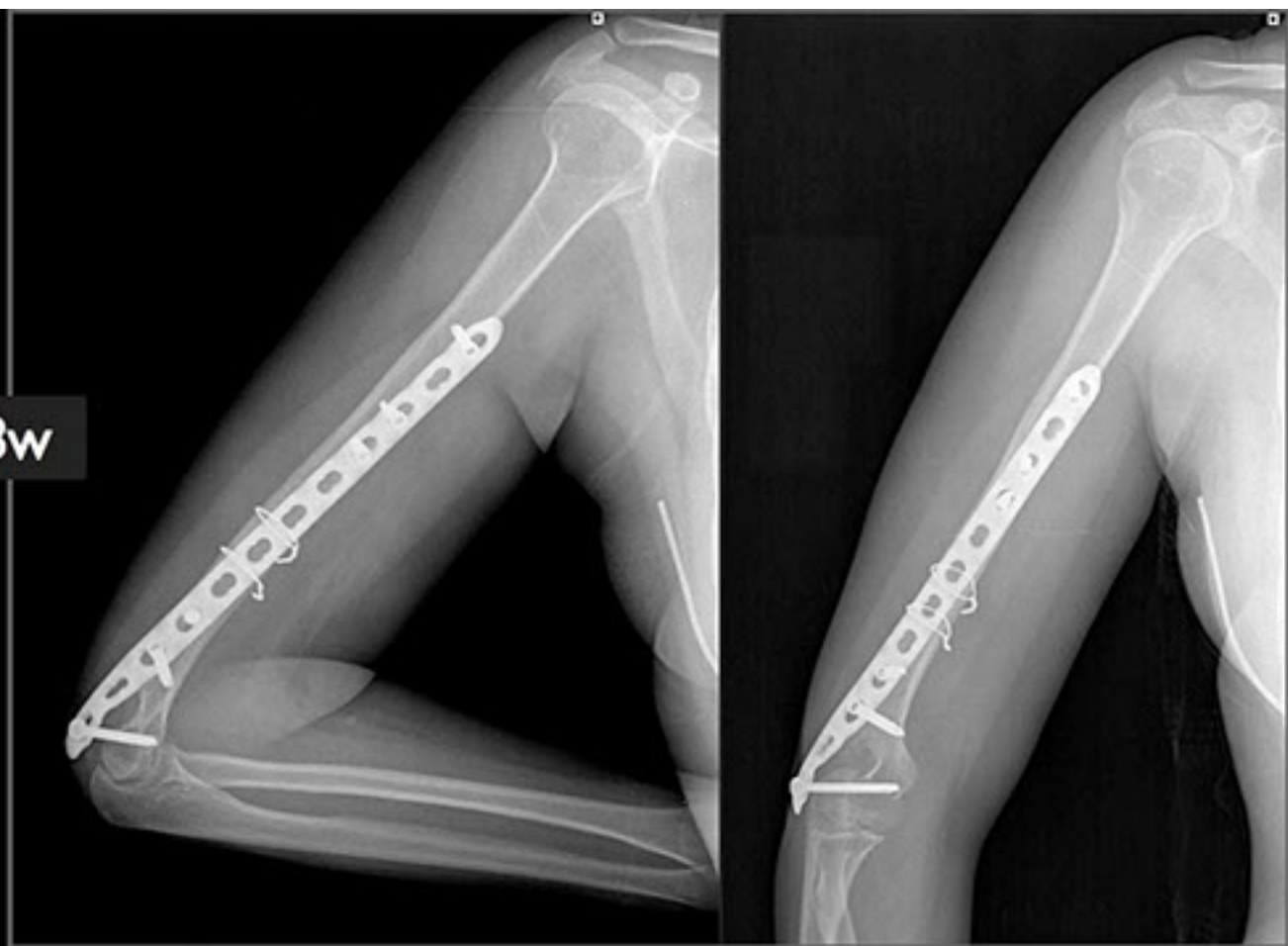
By 15, 18 weeks the fracture is consolidated.

18w

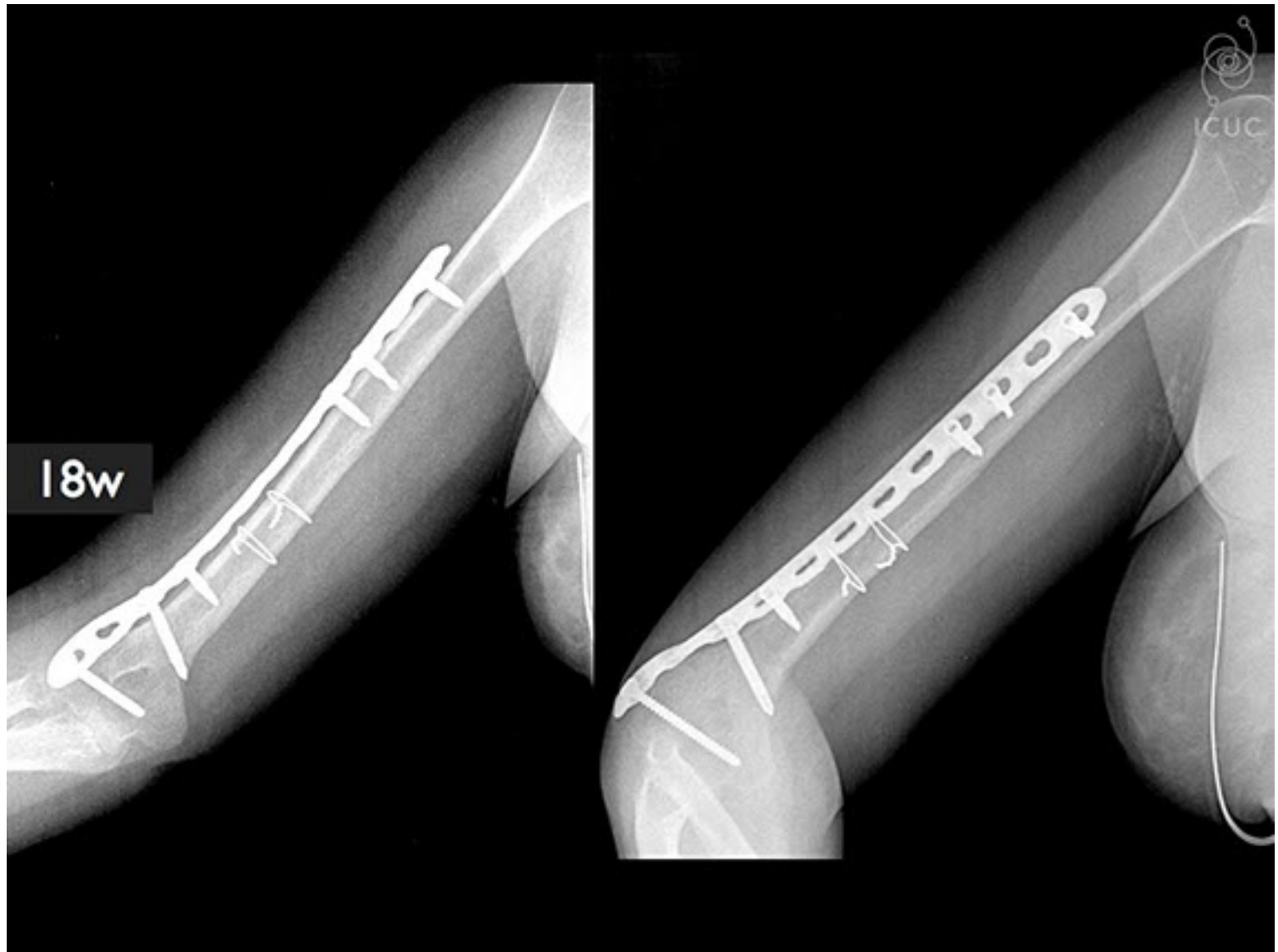


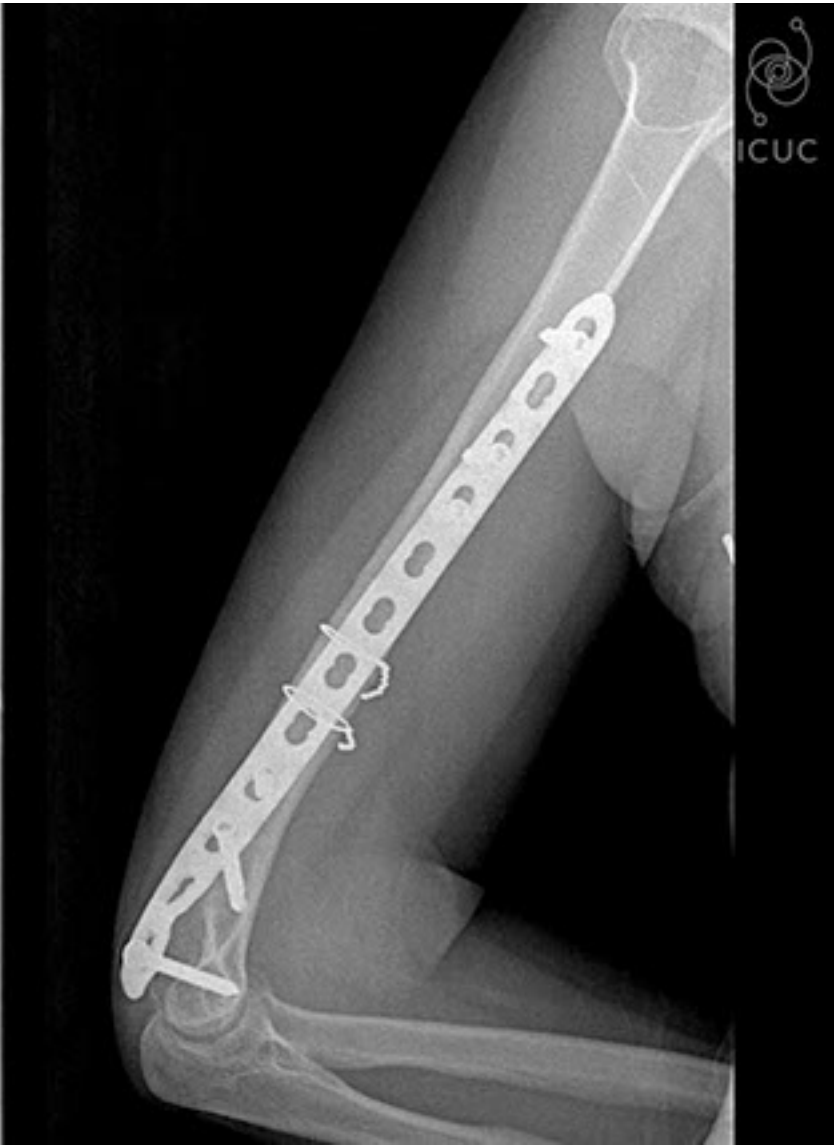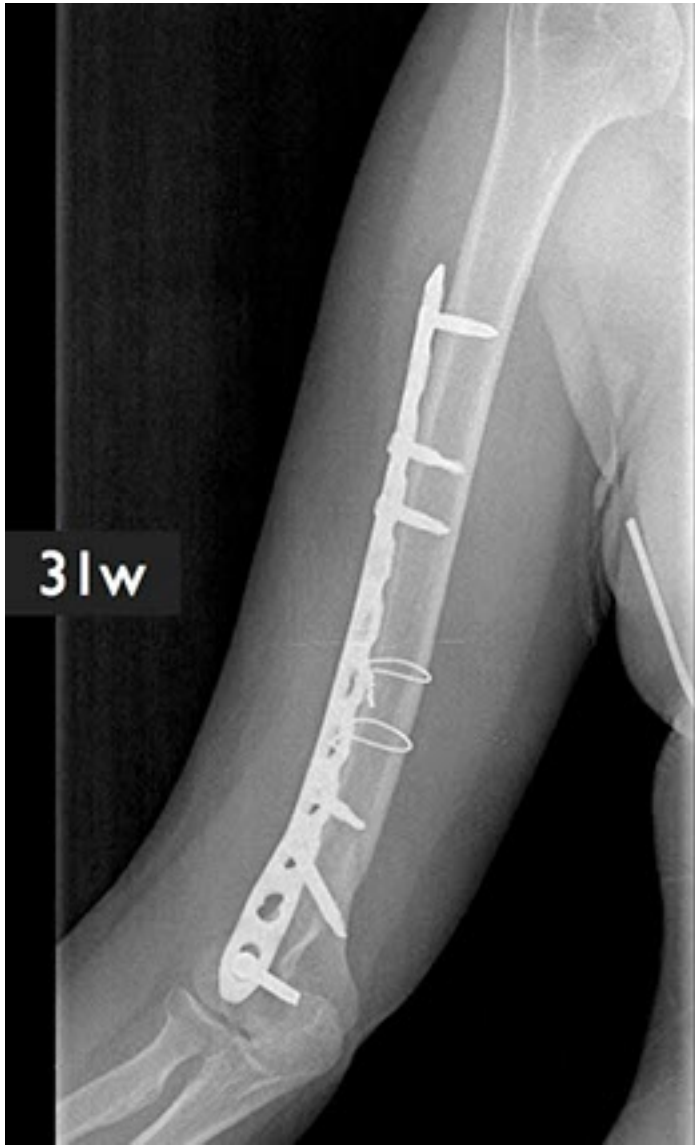There is new cortical bone medially and importantly the radial nerve is beginning to recover at that point as well.

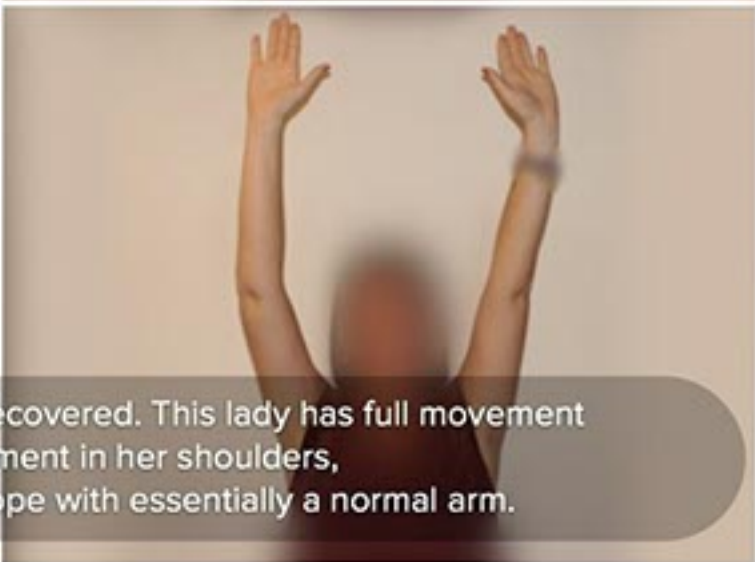
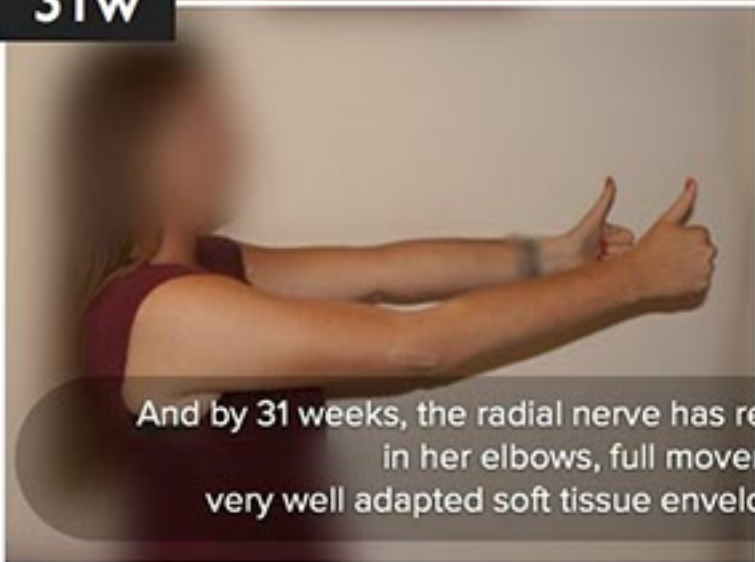18w



So by 18 weeks we've got basically medial cortical restoration.
No problem with the fixation of the fracture.







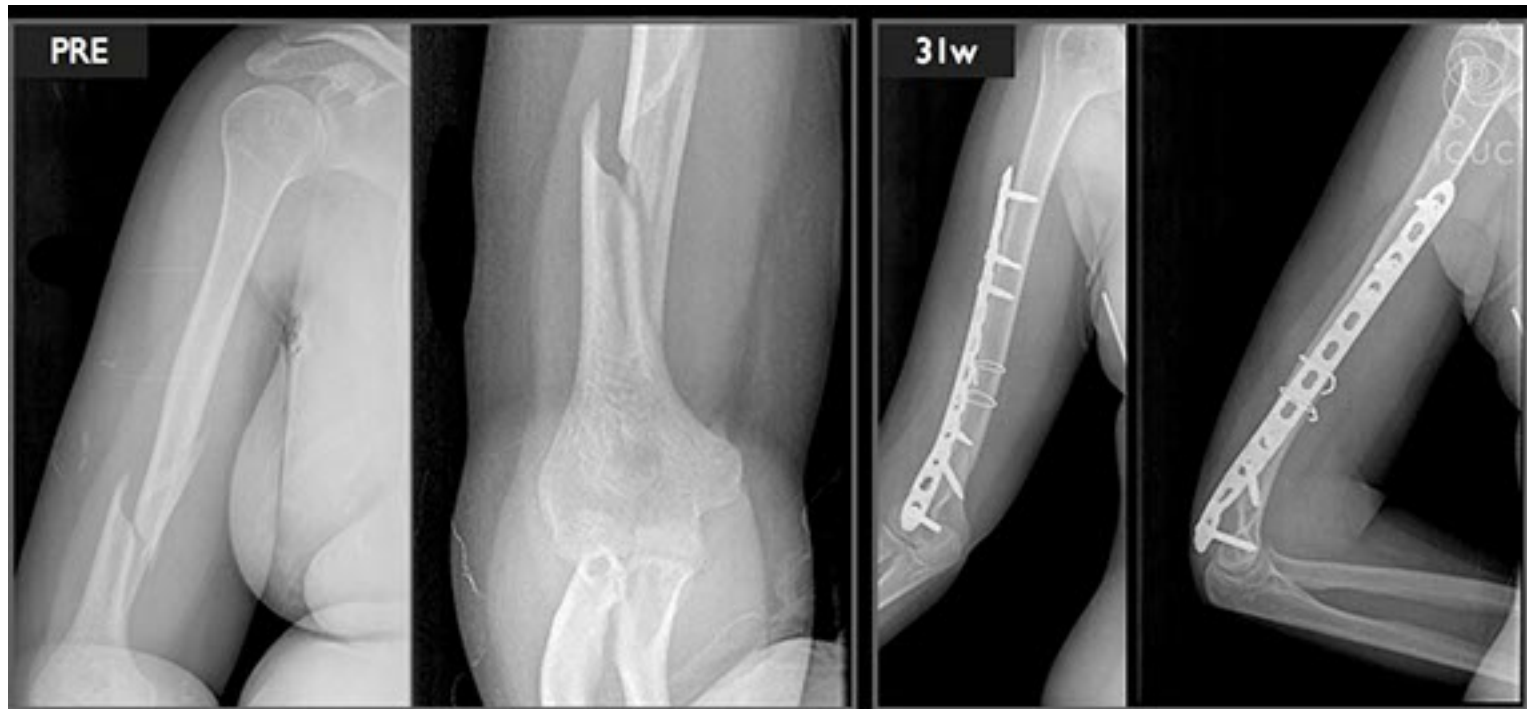

31w

And by 31 weeks, the radial nerve has recovered. This lady has full movement in her elbows, full movement in her shoulders, very well adapted soft tissue envelope with essentially a normal arm.



31w





This lovely case illustrates to me a surgical tactic, which is driven by the need to see the radial nerve because of a progressive palsy. A nice surgical tactic which involves developing two windows between and within the muscle and the constant checking of the nerve versus the fracture; adapting the fracture always accompanied by checking the nerve. Eventually ending up with a very super result.

I thought it was a very nice case indeed.





























